

CHAPTER 1

Vascular Access

Pham Nhu Hung, Marco Zuin, Hadrian Hoang-Vu Tran, Nguyen H.K. Nguyen, Mihas Kodenchery, and Thach N. Nguyen

Challenges 3

Femoral Approach 3

Game Play: Ideal Location of Femoral Access 3

Best Players: Also Known as Standard of Technical Excellence in Femoral Approach 3

Real-time Actions 4

Ultrasound-guided puncture 4

Tips and Tricks 4

***Selection of the area for puncture under ultrasound 4

**Difficulty in cannulating the arterial sheath 4

Real-time Actions 4

Fluoroscopically guided micropuncture access 4

Large sheath 6

Dedicated Equipment 6

Tips and Tricks 6

**Angiography to check the location of femoral entry through a dilator 6

*Preparations in obese patients 7

*Directing the needle 7

*If the wire cannot be inserted 7

*Sequential order for arterial and venous puncture 7

**Kinked wire 7

**Puncture of pulseless femoral artery 7

Confronting the Challenges 8

***Two catheters inserted with single puncture technique 8

***Insertion of intra-aortic balloon pump (IABP) through a diseased iliac artery 8

Puncture of femoral bypass graft 8

Real-time Actions 8

Bypass graft puncture 8

Confronting the Challenges 8

***Parallel technique 8

Antegrade Puncture 8

Real-time Actions 9

Common femoral artery antegrade puncture 9

*Basic; **Advanced; ***Rare, exotic, or investigational

\$, <100.00 \$US extra; \$\$, >100.00 \$US extra

⌚, <10 min extra; ⌚⌚, >10 min extra

♣, low risk of complications; ♣♣, high risk of complications

Practical Handbook of Advanced Interventional Cardiology: Tips and Tricks, Sixth Edition.

Edited by Thach N. Nguyen, Thuong Dzung Ho, Khiem D. Ngo, Mihas Kodenchery, Gianluca Rigatelli, Marco Zuin, Shao Liang Chen, and C. Michael Gibson.

© 2026 John Wiley & Sons Ltd. All rights reserved, including rights for text and data mining and training of artificial intelligence technologies or similar technologies. Published 2026 by John Wiley & Sons Ltd.

Companion website: www.wiley.com/go/nguyen/interventionalcardiology

2 CHAPTER 1

Tips and Tricks 9

- **Manipulation of the wire 9
- **Puncture of CFA with high bifurcation 9
- **Puncture with abduction and external rotation of the thigh 9

Brachial Approach 9

Axillary Puncture 10

Right Heart Catheterization in Patients Undergoing Procedure with

Radial Approach 11

Closure Devices 11

Collagen Plug Device: MYNX® 11

Clip Device: StarClose™ 12

The Perclose™ 12

Real-time Actions 12

Preclosure of large arterial access 12

Preclosure of large venous access 13

Tips and Tricks 13

- ***Differences in technical details for preclosure of venous access 13
- ***Double Angio-Seal™ closure for a 10-F vascular access 14
- ***Double MYNX closure for 14-F arterial access 14

Discriminating Differences 14

Which vascular closure devices for which patients? 14

Confronting the Challenges 14

Suspecting intra-arterial deployment of collagen plug 14

Confronting the Challenges 14

***Management of intra-arterial deployment of collagen plug 14

Complications 16

Hematoma 16

Arteriovenous Fistula 16

Acute Arterial Thrombosis 16

Confronting the Challenges 16

Mechanical thrombectomy for acute thrombosis 16

Limb Ischemia 16

Confronting the Challenges 16

***Temporary relief of iatrogenic ischemic limb: percutaneous technique for in vivo femoral artery bypass 16

Preventing limb ischemia 17

Retroperitoneal Hematoma 17

Mechanism of clinical symptoms 17

Discriminating Differences 18

Medical and surgical management of retroperitoneal hemorrhage 18

Tips and Tricks 18

**How to detect RPH in a 1-second maneuver? 18

Real-time Actions 18

How to seal a perforation with a balloon 18

How to close a perforation with microcoil or injection of thrombin 18

Perforation 18

Real-time Actions 19

How to seal a perforation with a covered stent 19

Pseudoaneurysm 19

Femoral Dissection 21

Case Report: Retrograde Abdominal and Thoracic Dissection from the Iliac Artery 22

CHALLENGES

Gaining vascular access without early or late bleeding at the access site is a major challenge for every operator carrying out diagnostic or interventional cardiovascular procedures.

FEMORAL APPROACH

GAME PLAY

Ideal Location of Femoral Access

The femoral artery is typically palpated below the inguinal ligament, which extends from the anterior superior iliac spine to the pubic tubercle. However, the true position of the inguinal ligament lies 1–2 cm beneath this line. The optimal “landing zone” for vascular entry is located above the femoral bifurcation and below an upper margin that is conservatively defined as several centimeters beneath the lowest point of the inferior epigastric artery (IEA). The IEA descends to, but does not cross, the distal side of the inguinal ligament. Therefore, entry above the lowest point of the IEA’s course, which typically ascends to supply the epigastrium, can be used to define an unequivocally high puncture site [1] (Figure 1.1).

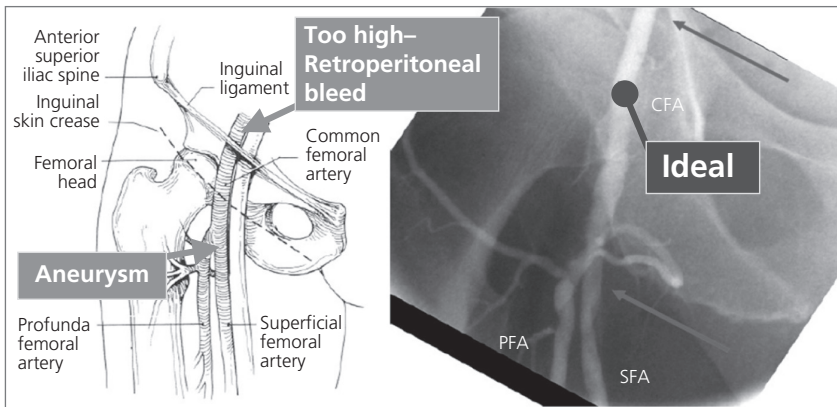
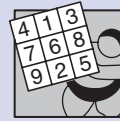


Figure 1.1 Ideal location for puncture of the femoral artery. Source: Reproduced with permission from John Wiley & Sons. CFA, common femoral artery; SFA, superficial femoral artery; PFA, profunda femoral artery.

BEST PLAYERS

Also Known as Standard of Technical Excellence in Femoral Approach

The technique utilizes fluoroscopic visualization of the femoral head in a posterior-anterior projection. The skin puncture is initiated at the lower border of the femoral head, aiming for arterial cannulation at the mid-third of the femoral head. However, even with this approach, punctures below the bifurcation of the common femoral artery (CFA) cannot be entirely avoided due to variability in the femoral artery bifurcation relative to the femoral head. In approximately 77% of cases, the bifurcation occurs below the femoral head, while in about 23% of cases, it is higher. Additionally, 97% of patients have the femoral artery positioned on the medial third of the femoral head, with only 3% having the artery completely medial to the femoral head. Therefore, the most effective way to achieve a near-perfect femoral puncture is through ultrasound guidance [1].

Real-time Actions

Ultrasound-guided puncture In this technique, a needle is initially positioned under fluoroscopy to locate on the skin the best location for puncture, the lower two-thirds of the femoral head (Figure 1.2a).

The equipment used is the Fujifilm SonoSite™ (Bothell, WA, USA), aimed at locating the segment of the CFA immediately proximal to the bifurcation. The femoral artery is identified as a minimally pulsatile, round structure adjacent to another round structure, the femoral vein (Figure 1.2b). When the operator applies pressure with the vascular probe, the femoral artery retains its size, while the femoral vein compresses (Figure 1.2c). The operator tilts the probe up and down to locate the bifurcation with the superficial femoral artery (SFA) and the profunda femoral artery (PFA) (Figure 1.2d). Once the SFA and PFA are located, the puncture site is set proximal to the bifurcation (Figure 1.2b). The needle is positioned at the center of the probe and angled tangentially toward the artery. The metal shadow of the needle is traced, and the tip creates a dent on the anterior wall of the CFA. By advancing forward, the tip enters the lumen, confirmed by strong blood flow back.

Tips and Tricks

*****Selection of the area for puncture under ultrasound** With ultrasound guidance, the operator can identify areas of calcification on the anterior wall of the CFA, which should be avoided for puncture. This is because the needle might penetrate the artery wall, but the subsequent wire may fail to pass through. Manipulating the needle in such cases can lead to unintended vascular access. Additionally, the wire might enter the artery in a subintimal fashion, causing arterial dissection. Therefore, it is advisable to avoid calcified areas and instead target regions without calcification for vessel entry.

****Difficulty in cannulating the arterial sheath** In some cases, inserting a sheath into the artery can be challenging due to the kinking of the wire at the entry site. To address this, push the wire slightly deeper and insert the sheath at a downward angle to access the lumen. Then, slide the sheath up along the artery. This process may require fluoroscopic guidance to ensure the dilator does not bend the wire, creating a pointed tip that could perforate the artery.

Real-time Actions

Fluoroscopically guided micropuncture access The micropuncture vascular access technique involves the use of needles and wires typically in the 21-gauge and 0.018-inch range. For femoral access, these needles are usually 7 cm in length. The outer diameter of this needle is 0.8 mm; in contrast, the 18-gauge needle used by most operators is 56% larger, resulting in as much as six times the blood flow rate through an inadvertent back wall puncture or from an arterial entry with failed sheath placement [2].

The CFA is punctured under fluoroscopic guidance using the mid-third of the femoral head to guide the needle to the anticipated puncture site, although restricting puncture to a point below the centerline of the femoral head may be the most prudent approach. After the initial localization of the bottom of the femoral head, repeat fluoroscopy is performed after the needle has been placed deep in the tissue track, but not yet into the femoral artery, to achieve an ideal location of puncture. The path of the needle can be adjusted several times, if necessary, as it traverses deep into the subcutaneous tissue [2]. Once the needle is in the vessel and there is blood return, some operators perform a limited femoral angiogram via the micropuncture needle using a 3-mL syringe (Figure 1.2e).

If an acceptable CFA access location is confirmed, a 0.018-inch wire is advanced through the needle. A 4-Fr micropuncture sheath is advanced over the wire and exchanged for a 0.035-inch wire to support the passage of a larger sheath size. There are also larger, highly tapered sheaths designed to go directly over the micropuncture wire. This technique allows relatively safe removal of the micropuncture needle or sheath after unfavorable location entry, with manual pressure applied for 3–5 minutes before attempting a new puncture based on the angiogram [2]. <http://invasivecardiology.com/files/CilFig5.png>

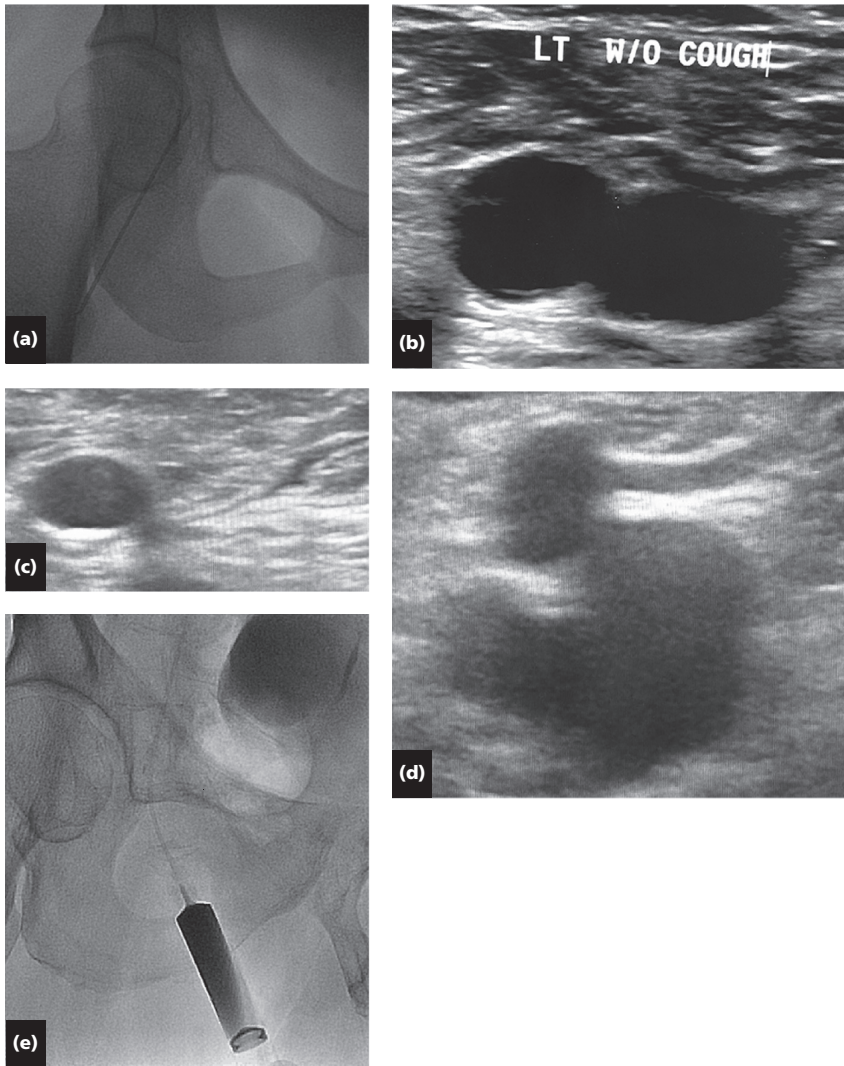


Figure 1.2 (a) A needle is positioned in the right groin area under fluoroscopy, looking for the ideal location for puncture. The tip should be at the lower two-thirds of the femoral head. The reason for this is to locate the upper limit of the area of puncture so the tip of the needle does not end up too high as guided by ultrasound in a patient with a high bifurcation of the deep femoral artery. (b) The femoral artery is recognized as a minimally pulsatile round structure. Next to it should be an oblong structure, which is the femoral vein. (c) Press the vascular probe down: the femoral artery stays the same, while the femoral vein disappears because it is compressed. (d) The superficial femoral artery, profunda femoris artery, and femoral vein at the bifurcation. (e) Before upsizing the micropuncture sheath, perform angiography of the arteriotomy site in the ipsilateral 30–40°. Note vessel morphology. If the location is not “ideal,” pull the sheath out, compress the groin area, and reaccess the artery.

Large sheath Newly developed inflatable vascular sheaths designed to minimize frictional forces caused by large-bore devices have been evaluated. Recent studies suggest that these sheaths may enhance femoral access in patients with access-limited peripheral artery disease. One such sheath is the 19-Fr SoloPath™ balloon-expandable transfemoral access (Terumo, Japan). [3].

DEDICATED EQUIPMENT

The 19-Fr SoloPath Transfemoral Introducer (STFI) is a vascular access device that enables large-bore access with technology allowing entry into the femoral artery at a low insertion profile (13 Fr), which then radially expands to a larger profile (19 Fr). The STFI sheath is inserted in a folded state over an expansion balloon dilator. The SoloPath transfemoral system is advanced under fluoroscopic guidance over a stiff wire. It consists of a 25-cm flexible, reinforced polymer sheath pre-mounted over a central balloon dilatation catheter. The specially folded distal two-thirds of the sheath facilitate passage through tortuous and calcified femoral arteries. Once the system is positioned in the abdominal aorta, the SoloPath balloon dilator is inflated for 60 seconds at 20 atm via injection of a 20-mL saline–contrast mix, then deflated and removed, leaving a large 21-F central lumen vascular sheath (Figure 1.3) [3].

E

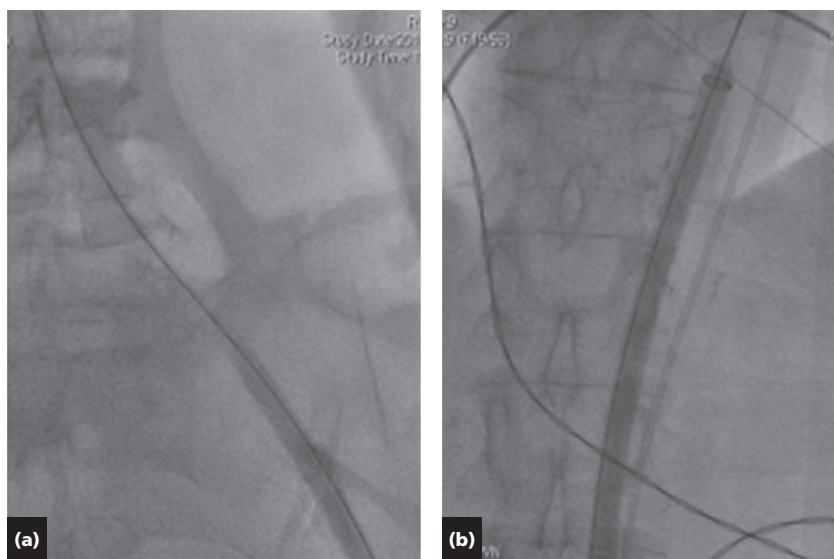


Figure 1.3 Fluoroscopic images of the partially (a) and completely expanded (b) SoloPath expandable sheath.

Tips and Tricks

****Angiography to check the location of femoral entry through a dilator** Some operators avoid injecting through the micropuncture needle due to additional radiation exposure and the risk of losing intraluminal positioning or causing vessel dissection. An alternative approach is to access the vessel with the micropuncture needle, advance the 0.018" wire, and place the small inner dilator of the micropuncture sheath over the 0.018" wire. This small dilator can then be used for angiography instead of injecting directly through the micropuncture needle or the larger outer 4-Fr sheath.

***Preparations in obese patients** The femoral pulse at the inguinal crease is an unreliable landmark for the CFA, especially in obese or elderly patients whose crease is often positioned lower than the inguinal ligament. To improve access, the protruding abdomen and panniculus should be retracted and secured to the chest with 3- to 4-inch tapes, which are then anchored to the sides of the catheterization table. Maintaining a thin and taut tissue layer above the artery prevents the needle from being deflected off the projected angle and pathway.

***Directing the needle** When the needle tip approaches the artery, it typically begins to pulsate, except in patients with severe local scarring (such as those with a history of multiple femoral artery cannulations, total hip replacements, or severely calcified arteries due to chronic renal failure). If the hub shifts to the right, the needle should be withdrawn by 1 cm and the tip redirected to the left before advancing further. Conversely, if the hub shifts to the left, the needle tip should be redirected to the right before continuing. If the needle pulsates along the vertical axis, it should be advanced slowly and deeper.

***If the wire cannot be inserted** Most commonly, this occurs when the needle has contacted the contralateral wall. To resolve this, slightly pull or rotate the needle, which may allow the wire to be inserted. If problems persist, it is better to withdraw the needle and re-puncture the artery rather than risk dissecting it with a slippery wire. After the sheath is inserted, if there is strong arterial backflow and the wire cannot navigate the tortuous iliac artery, try gently pulling the sheath back (to disengage it from under a plaque, if that is the issue) and inject contrast. This may help visualize the anatomy and identify the cause of the wire's difficulty. If there is no strong backflow, the sheath may not be in the arterial lumen. In cases of a very tortuous iliac artery, a diagnostic Judkins right (JR) catheter can be cautiously inserted and advanced to help steer the wire. Injections through the JR catheter can also assist in determining why the wire cannot be advanced.

***Sequential order for arterial and venous puncture** The sequence of arterial and venous puncture for right heart catheterization is often a matter of personal preference. We prefer to puncture the vein first, inserting a wire to secure access, followed by puncturing the artery a few seconds later. Afterward, we insert the sheath into both the artery and the vein. Since only a wire is in the vein, there is minimal distortion at the arterial puncture site, which could occur if a venous sheath were in place. A brief period of less than a minute without a sheath will not typically lead to hematoma at the venous site. If the artery is inadvertently punctured first, we cannulate the artery and inject contrast through the arterial sheath. Then, under fluoroscopy, we puncture the vein with the needle placed medially and parallel to the contrast-filled arterial sheath. Alternatively, ultrasound can be used to guide the puncture.

We avoid puncturing the artery with a venous sheath in place because, if the venous sheath is accidentally entered, it may be difficult to control bleeding from the extravascular segment of the sheath with manual pressure. To reduce the risk of creating an arteriovenous fistula (AVF), another strategy is to perform arterial and venous access in separate limbs (e.g. artery in the right groin and vein in the left groin).

****Kinked wire** It is not uncommon for the wire to pass easily into the lumen, but attempts to advance a dilator over the wire may result in kinking at the point of vascular entry. Instead of immediately exchanging the wire, the first preferred maneuver, if the wire is not too crooked, is to advance the wire further. This allows the dilator to be advanced over a straight, stiffer segment of the wire to properly dilate the entry site. If the wire is too soft, the second option is to exchange the softer wire for a stiffer one, using the smallest size 4-F dilator. Ensure that the dilator is advanced under fluoroscopy to verify that it does not bend the wire (which could create a pointed tip) and risk perforating the artery.

****Puncture of pulseless femoral artery** As usual, the artery should be punctured at the midpoint of the medial third of the femoral head. The skin puncture site should be localized

using fluoroscopy just below the inferior border of the femoral head to avoid puncturing above the lowest border of the IEA. However, these proportions are only accurate in the anteroposterior (AP) neutral position. Internal or external rotation of the femur can significantly alter the relationship between the femoral artery and the femoral head. Performing the procedure under fluoroscopy is recommended. The most effective technique is to locate the CFA using ultrasound.

Confronting the Challenges

*****Two catheters inserted with single puncture technique** This technique is used in situations like angioplasty for chronic total occlusion when contralateral injection is required. In such cases, an additional puncture, either higher or lower than the initial vascular access site or in the contralateral artery, is recommended. However, if no additional puncture is necessary, the sheath should be exchanged for an 8-F introducer. Two 4-Fr diagnostic catheters can then be inserted and connected to separate manifolds for diagnostic purposes [4].

*****Insertion of intra-aortic balloon pump (IABP) through a diseased iliac artery** When an IABP needs to be inserted and an iliac lesion is present, the lesion should first be dilated. After inserting the balloon pump, stent the lesion once the IABP is removed. If the balloon pump is to be inserted through a previously stented iliac artery, the procedure should be done under fluoroscopy to ensure the balloon does not become trapped by the stent struts. Chronic reendothelialization of the stent struts typically minimizes this risk.

Puncture of femoral bypass graft Problems associated with puncturing an old vascular graft in the femoral area include uncontrollable bleeding and hematoma formation due to the nonvascular nature of the punctured graft, disruption of the anastomotic suture line leading to false aneurysm formation, infection at the graft site, and damage to the catheter, including kinking and separation, caused by scar tissue in the inguinal area and the rigidity of the healed graft material. Inadvertent puncture of the native arterial system may result in entry to a dead-end stump in the common femoral or iliac artery.

Real-time Actions

Bypass graft puncture Since the exact location of the suture line is not known, to avoid puncturing the anastomotic site, it is best to puncture at the proximal end of the inguinal incision site or as close to the inguinal ligament as possible. To prevent catheter kinking at the puncture site, the needle should be introduced at an angle of approximately 30–45° to the estimated long axis of the graft. The most reliable method is to locate the artery using ultrasound. In cases of severe scarring, the entry site may require sequential dilation with progressively larger dilators, up to 1 Fr larger than the sheath selected for the procedure.

Confronting the Challenges

*****Parallel technique** If the native artery is punctured and the wire cannot be advanced due to a dead-end pouch, leave the small 4-F sheath in place as a landmark. Palpate the femoral artery again and try to feel two pulsations: the first is the native artery with the 4-F sheath, and the second, stronger pulsation is from the bypass graft, provided the graft is superficial (though it may be difficult to feel if the graft has a thick wall). Puncture the second pulsatile artery, ensuring you avoid the one with the sheath. This can be done under fluoroscopic guidance to prevent puncturing near the first sheath.

ANTEGRADE PUNCTURE

Antegrade femoral puncture is significantly simplified and more successful when the tissue between the skin surface and the artery is as thin as possible. In obese patients, the fatty panniculus may need to be manually retracted away from the puncture site and taped in place

before attempting the puncture. The technique for antegrade puncture of the femoral artery is discussed in detail in Chapter 23.

Real-time Actions

Common femoral artery antegrade puncture The first step is to localize the CFA and its bifurcation under fluoroscopy. The CFA typically overlies the medial third of the femoral head, with the bifurcation located just below the lower border of the femoral head. Once the landmarks are identified, the needle should be directed toward the superior aspect of the femoral head under fluoroscopy to avoid inadvertently puncturing the SFA or the PFA. It is crucial to puncture the femoral artery as high as possible above the bifurcation to allow enough space for catheter exchanges and manipulation of catheters into the SFA. Using fluoroscopy, the intended puncture site is located in the upper or middle third of the femoral head. The femoral pulse is palpated against the femoral head, and local anesthetic is infiltrated 2–3 cm cranial to the puncture site. An 18-gauge needle is then advanced at 45–60°, directed caudally toward the arterial puncture site. Once pulsatile flow is obtained, a soft-tip wire is inserted toward the SFA, following a straight caudal course. Any lateral deviation indicates entry into the PFA. If this occurs, the wire can be withdrawn, and the needle tip is deflected laterally to redirect the wire into the SFA. It is best to perform this procedure under ultrasound guidance.

Tips and Tricks

****Manipulation of the wire** If the wire is inserted into the PFA, it can be withdrawn and redirected by angling the needle tip medially toward the SFA. Alternatively, a wire with a curved tip can be used and manipulated so the tip points toward the SFA. Another option is to exchange the needle for a short dilator with a gently curved tip, which can be directed toward the SFA. This dilator can be slowly withdrawn from the PFA while injecting contrast. Once the orifice of the SFA is visualized under fluoroscopy, it can be selectively catheterized or used to direct a wire into the SFA.

****Puncture of CFA with high bifurcation** In patients with a high bifurcation, a single puncture can result in entry into both the SFA and PFA. If this occurs, the first spurt of blood may indicate the PFA has been punctured. Do not remove the needle completely; instead, slowly withdraw it and watch for a second spurt of blood. This may confirm that the needle is in the SFA when contrast is injected. In rare cases of high bifurcation, the CFA may be too high in the pelvic area to puncture. When the bifurcation is more proximal, puncturing the CFA becomes more challenging, particularly in obese patients. In such cases, it may be acceptable to selectively puncture and cannulate the SFA, provided it appears free of significant atherosclerotic disease and is of adequate size [5].

****Puncture with abduction and external rotation of the thigh** An alternative method to cannulate the SFA is to position the thigh in abduction and external rotation. This maneuver aims to facilitate a more mediolateral puncture site in the CFA. In the typical antegrade puncture, the needle tends to point more toward the PFA, which is lateral to the SFA. However, in the abduction and external rotation position, the needle points more toward the SFA, with the PFA located medial to it. This altered relationship is crucial when observing the wire's course during its selective entry into the SFA. After the procedure, if the patient is punctured in this position, local compression of the artery should be applied while maintaining the thigh in abduction and external rotation, as the puncture site is more mediolateral than usual.

BRACHIAL APPROACH

Although the radial artery is the most commonly used access site in the upper extremity, the brachial artery remains the preferred site for procedures requiring a larger sheath, such as subclavian artery stenting, renal stenting, or aortic aneurysm exclusion. It is recommended to puncture the brachial artery under ultrasound guidance. Radial access is discussed in Chapter 8.

AXILLARY PUNCTURE

Anatomically, the distal third of the axillary artery has three main branches: the subscapular artery, the anterior humeral circumflex artery, and the posterior humeral circumflex artery. The region between the origin of the subscapular artery and the origins of the anterior and posterior humeral circumflex arteries is ideal for percutaneous access to this vessel (Figure 1.4). The axillary artery is preferred over the subclavian artery due to its accessibility outside the chest wall, which allows for manual compression if closure procedures fail. It is also favored over the brachial artery because of its larger diameter and the presence of collateral circulation, which reduces the risk of limb ischemia during the procedure [6].

It is important to be aware of the structures surrounding the axillary artery in this region to prevent potential complications. In front of the artery lie the medial head of the median nerve and the medial antebrachial cutaneous nerve. Medial to the axillary artery is the axillary vein, with the ulnar nerve located between the artery and vein. The medial brachial cutaneous nerve is situated medial to the axillary vein. Laterally, the lateral branch of the median nerve and the musculocutaneous nerve are found. Behind the axillary artery are the axillary and radial nerves [6].

Before gaining access to the left axillary artery, a 7-Fr sheath is inserted into both the right and left radial arteries. An angiogram of the right radial artery is performed to ensure there are no contraindications for using this approach for percutaneous coronary intervention (PCI). Next, an angiogram of the left upper extremity is conducted to confirm the patency of the axillary artery and identify the optimal location for cannulation. This location is in the third part of the vessel, proximal to the origin of the anterior and posterior humeral circumflex arteries and distal to the subscapular artery. A 0.038-inch J wire is then inserted through the left radial artery sheath into the axillary artery. Using the J wire as a fluoroscopic guide, a micropuncture needle is used to access the axillary artery, and a 6-Fr sheath is placed using the modified Seldinger technique (Figure 1.5).

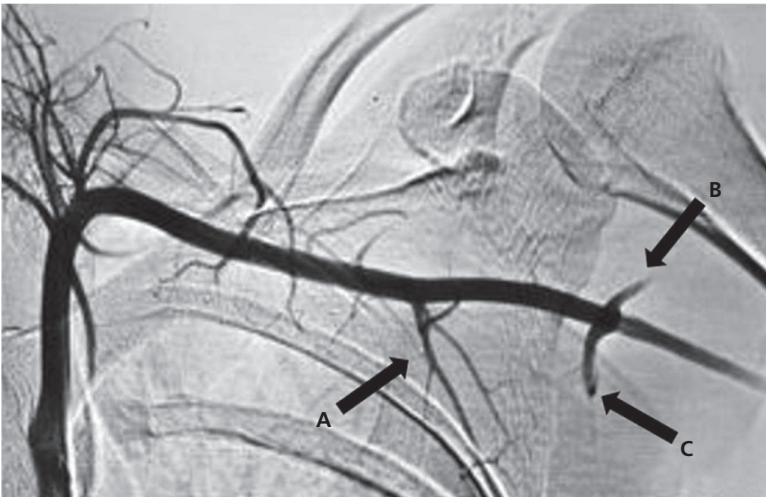


Figure 1.4 Normal subclavian and axillary artery angiogram. The subscapular artery (A) and anterior and posterior humeral circumflex arteries (B and C) are labeled in the third part of the axillary artery [6].

Source: Reproduced with permission from John Wiley & Sons.

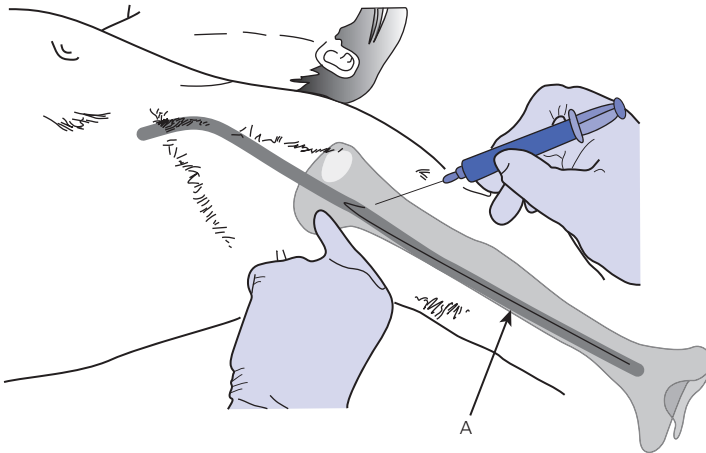


Figure 1.5 Patient in supine position with left arm abducted. A J-wire (A) inserted via a 7-Fr left radial sheath is visualized under fluoroscopy and marks the ideal location for needle insertion between the origin of the subscapular and humeral circumflex arteries. Source: Reproduced with permission from [6]/John Wiley & Sons.

RIGHT HEART CATHETERIZATION IN PATIENTS UNDERGOING PROCEDURE WITH RADIAL APPROACH

The upper and lower arms are prepped and draped in a sterile fashion, using brachial drapes over the wrist and antecubital fossa. Arterial access is obtained via the radial artery, and a sheath is inserted. Position the table so that the antecubital fossa is aligned under the imaging system. Then, inject 5–7 mL of a 50:50 contrast–saline mix into the radial artery under fluoroscopy through the side port of the sheath (the “arterial phase”). After approximately 5–10 seconds, the basilic vein in the upper arm should become visible (the “venous phase”). This is a good time to anesthetize the area over the basilic vein. Using the same micropuncture needle used for radial access, obtain access to the basilic vein, place a 5-Fr radial sheath, and then proceed with the right heart catheterization through the sheath [7].

CLOSURE DEVICES

A closure device can be used after procedures such as PCI, valvuloplasty, or IABP, or when an artery is inadvertently punctured, such as during subclavian artery cannulation. The choice between collagen plugs and suture closure is primarily based on personal preference and experience. Kaolin patches are also available for use when collagen plugs or suture-mediated devices cannot be employed due to factors like massive calcification or severe kinking that prevent the insertion of such devices.

Collagen Plug Device: MYNX®

The MYNX (Cordis Corporation, FL, USA) vascular closure device uses a polyethylene glycol sealant (“hydrogel”) that deploys outside the artery, while a balloon occludes the arteriotomy site within the artery. The device is inserted through the existing procedural sheath, and a small, semi-compliant balloon is inflated within the artery. The balloon is then pulled back to the arterial wall, serving as an anchor to ensure proper placement. The sealant is delivered just




Figure 1.6 The MYNX balloon was punctured when there was a sharp calcium ledge in the common femoral artery.

outside the arterial wall, where it expands to achieve hemostasis. Once hemostasis is achieved, the balloon is deflated and removed through the tract, leaving behind only the expanded, conformable sealant.

One challenge with the MYNX device is that the balloon can be punctured by a sharp calcium ledge in the CFA (Figure 1.6). If there is concern about calcified plaque in the CFA, or if the operator prefers not to use a closure device with an intravascular component, the VASCADE™ (Cardiva Medical, Inc., Santa Clara, CA, USA) may be a better alternative, as it uses a collapsible disk as an anchor. Another potential issue with the MYNX closure device arises when there is a lesion in the mid-external iliac artery. There is concern that the balloon could be inflated at the site of an iliac artery plaque. To address this, inject the balloon of the MYNX device with contrast and position it distal to the iliac lesion under fluoroscopy. Inflate the balloon under fluoroscopy (Figure 1.7a), pull the balloon down (Figure 1.7b), and then deploy the protein plug (Figure 1.7c).

Clip Device: StarClose™

The StarClose (Abbott Vascular Devices; Abbott Laboratories, Redwood City, CA, USA) device achieves hemostasis using a 4-mm nitinol clip implant. The device is inserted into the arterial lumen, and its “wings” are deployed. As the device is withdrawn, the wings are pulled against the arterial wall, confirming proper positioning. The clip is then deployed just outside the arterial wall, where it grasps the edges of the arteriotomy, drawing them together to achieve closure. The StarClose device is indicated for diagnostic and interventional procedures and for closing 5- to 6-Fr arteriotomies, though it has also been successfully used for 7- to 8-Fr arteriotomies.

The Perclose™ Real-time Actions

Preclosure of large arterial access In cases where a large sheath is required (e.g. for aortic valvuloplasty), untied sutures can be pre-placed using the Perclose (Abbott Vascular, Chicago, IL, USA) percutaneous suture delivery system prior to sheath deployment. A 5- to 6-Fr sheath may first be used for arterial angiography to assess the anatomy of the CFA, ensuring it is free from calcification and not near any lesions. Once suitable anatomy is identified, the suture device is used to place the untied sutures. At the end of the procedure, the “purse-string” suture is tightened around the arteriotomy to achieve hemostasis [8].

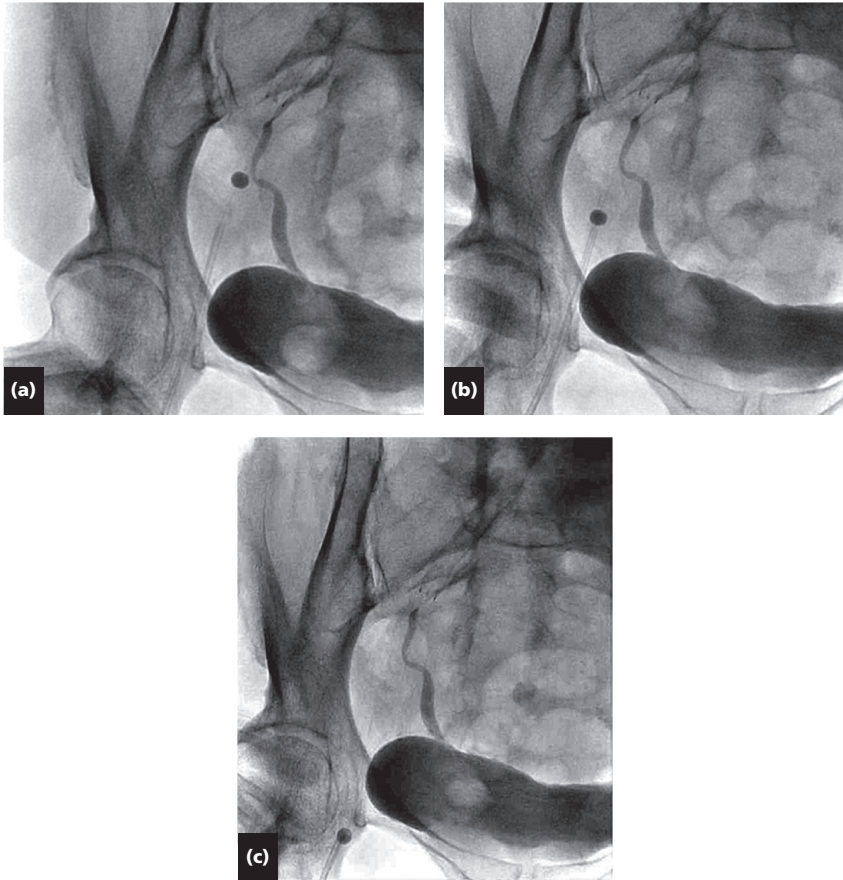


Figure 1.7 (a) The balloon was injected with contrast, positioned, and inflated under fluoroscopic guidance below the lesion in the iliac artery. (b) The balloon and the sheath were pulled down under fluoroscopy. (c) The balloon is at the wall, and the protein plug is ready to be deployed.

Preclosure of large venous access The “preclosure” technique involves preloading a 6-Fr Perclose suture closure device into the femoral vein after access with a 6- or 8-Fr dilator, prior to the insertion of a 14-Fr venous introducer sheath for antegrade aortic valvuloplasty. The placement of the Perclose device within the venous system is confirmed either by back-bleeding from the marker port or by contrast injection through the port. The needles are then removed, and the sutures are clipped. After the sutures are deployed, a wire is placed into the femoral vein through the Perclose device. The wire is used to exchange for a 14-Fr sheath, while the sutures are laid alongside the puncture and covered with betadine-soaked gauze. Upon completion of the valvuloplasty procedure, a wire is passed through the 14-Fr sheath to secure the vessel in case of suture closure failure. Heparin is not reversed. The sheath is removed through the sutures, and the sutures are tied around the wire. If hemostasis is achieved, the wire is gently removed, and the knot is pushed further to complete the closure [8].

Tips and Tricks

*****Differences in technical details for preclosure of venous access** Since veins have thinner walls than arteries, less tension is applied when retracting the Perclose device for venous closure compared to arterial closure. The device foot can securely contact the vessel

wall with steady pressure, using less force than is required for arteries. Back-bleeding through the marker port is seen in most cases, although it is less pronounced than in arterial closure due to the lower pressure in the venous system. Typically, a slow dribble of blood is noted from the marker port. There may be a delay in the onset of back-bleeding, which is further influenced by the low venous pressure. This delay can be minimized by having the patient take a deep breath or perform the Valsalva maneuver [8].

*****Double Angio-Seal™ closure for a 10-F vascular access** Although Angio-Seal (Terumo, Somerset, NJ, USA) labeling indicates compatibility with procedural sheaths of 8 Fr or smaller, the device has been successfully used to close 10-Fr arteriotomies with a “double wire” technique. In this approach, at the end of the procedure, both the Angio-Seal wire and a second, additional wire are inserted through the sheath. The Angio-Seal is deployed as usual using the primary wire, leaving the second wire in place. If hemostasis is achieved, the second wire is carefully removed while maintaining pressure on the collagen plug. If hemostasis is not achieved, the second wire serves as a “backup” to allow for the deployment of a second Angio-Seal device next to the first [9].

*****Double MYNX closure for 14-F arterial access** Two MYNX closure devices were simultaneously passed through the 14-F arterial sheath, and both distal semi-compliant balloons were inflated with a 3:1 saline-to-contrast mixture to facilitate balloon visualization. Under fluoroscopic guidance, the MYNX balloons were withdrawn to the distal end of the 14-F sheath, and then both balloons and the sheath tip were pulled back to the previously visualized arteriotomy site. The polyethylene glycol sealant from each MYNX device was advanced into the 14-F sheath sequentially, and the sheath was then withdrawn, allowing the sealant to hydrate and expand in an extra-arterial position over the arteriotomy. After 2 minutes, the balloons were deflated, the MYNX delivery catheters were removed, and manual compression was applied for an additional 2 minutes. Closure of the 14-F arteriotomy was confirmed to be complete, with no bleeding, vascular compromise, or hematoma on inspection [10].

Discriminating Differences

Which vascular closure devices for which patients? Vascular closure devices (VCDs) are not suitable for all patients, and caution is necessary when considering their use in individuals with peripheral vascular disease, extreme obesity, small femoral arteries (diameters <4–5 mm), or those with arterial cannulation at or below the bifurcation (because there is no bony structure behind the SFA to support manual compression if VCDs fail). In addition to patient-specific and arterial factors, the mechanism of action of VCDs must also be considered, particularly the presence of an intravascular component in the closure device.

Devices with significant intravascular components, such as the Angio-Seal device, are not recommended for bifurcation punctures due to the risk of obstructing smaller branches by the intravascular portion. Furthermore, accurately aligning the intravascular part can be challenging due to the complex angles at the bifurcation site. There is also a risk of intravascular deployment of the collagen plug. Therefore, access-site closure remains challenging in patients with bifurcation punctures. Devices without significant intravascular components, such as the StarClose or MYNX devices, are particularly beneficial for these patients. Additionally, VCDs should not be used in high arterial punctures, as they have been associated with an increased risk of retroperitoneal hemorrhage, with an odds ratio as high as 17:1 [11].

Confronting the Challenges

Suspecting intra-arterial deployment of collagen plug During deployment of an Angio-Seal device, intra-arterial deployment of the collagen plug can be caused by inadequate tension on the suture, vigorous tamping, too deep insertion of the device into the artery so that the anchor is caught in the posterior wall, and so on. Suspicion of a problem is aroused when there is a long travel distance of the tamper tube or continued bleeding [12].

Confronting the Challenges

*****Management of intra-arterial deployment of collagen plug** In a case report of possible intra-arterial deployment of the collagen plug by the Angio-Seal device, it was

observed that the tamper tube was inserted much deeper than usual. Despite this, the patient continued to bleed, prompting the placement of a tension spring as per usual practice. A hemostat was simultaneously applied to secure the end of the suture, and a FemoStop™ (RADI Medical Systems, Uppsala, Sweden) compression device was placed above the Angio-Seal to control the bleeding. After 4 hours, the anchor, composed of absorbable polymer material, softened and became pliable. To prevent potential embolization of the anchor and collagen plug if the suture broke during traction, a hemostat was placed at the level of the skin. Steady traction was then applied to the suture, perpendicular to the femoral artery, ensuring that pressure was not excessive. After 20 minutes, the plug was successfully removed. FemoStop was reapplied, and hemostasis was achieved [12]. Another method for removing an embolized plug is using a snare to extract it (Figure 1.8a–c). Management is summarized in Box 1.1.

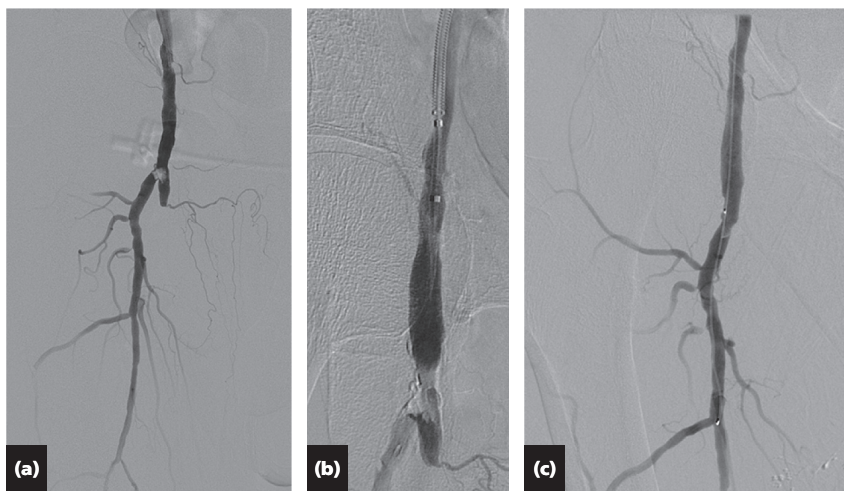


Figure 1.8 (a) The patient underwent diagnostic catheterization of the carotid artery. The right femoral angiogram was not performed at the end of the case because of a high creatinine level 1.8 mg/dL. An Angio-Seal device was deployed. One hour later, the patient had severe right leg pain. The femoral angiogram showed acute occlusion of the superficial femoral artery at the bifurcation. (b) and (c) A snare was advanced to the bifurcation area and successfully removed the embolized plug.

BOX 1.1 WHAT TO DO IF COLLAGEN IS INSERTED INTRA-ARTERIALLY

1. Prevent the problem: always maintain tension on the suture and avoid tamping with excessive force.
2. Recognize the problem: absence of resistance during tamping and inadequate hemostasis are clues.
3. Duplex ultrasound can document intra-arterial collagen.
4. Apply tension on the string in the usual fashion; secure the suture with a hemostat at skin level to add security.
5. **Do not cut the suture:** embolization of the anchor and plug may occur.
6. If there are signs of embolism and thrombosis, obtain a vascular surgery consultation.
7. Wait at least 4 h to allow softening of the anchor.
8. Exert steady vertical traction on the suture with approximately 10 lb of force.
9. If removal of the device is achieved, maintain manual compression to achieve hemostasis.
10. A FemoStop device should be ready for rapid deployment after the device is removed.
11. Remove the collagen plug using an atherectomy device (if needed).

Source: Adapted from [11].

COMPLICATIONS

Hematoma

The frequency of hematoma increases with increasing size of the sheath, level of anticoagulation, and obesity of the patient. Surgical evacuation is not required, even for large hematomas, unless there is undue tension on adjacent structures or in the case of a truly huge hematoma. Surgical evacuation and arterial repair are required when the hematoma is pulsatile and expanding, an indication of communication between the hematoma and the femoral artery, and the presence of a false aneurysm.

Arteriovenous Fistula

This happens rarely (>0.4%) when the puncture is made where the artery overlies the vein. Most small AVFs are asymptomatic and usually close spontaneously. A large AVF with symptoms of high-output failure needs to be corrected surgically.

Acute Arterial Thrombosis

Occlusion of the femoral artery may occur due to thrombosis or local arterial injury. It happens mostly in women with small femoral arteries that are completely blocked by the catheter during the procedure and in patients whose SFA is catheterized rather than the CFA.

Confronting the Challenges

Mechanical thrombectomy for acute thrombosis If thrombosis of the femoral artery is suspected, access is obtained from the contralateral side, and 5000 units of heparin are given. A 6-F crossover sheath is placed in the external iliac artery over a 0.035-inch stiff Amplatz guidewire. The occluded/thrombosed/embolized segment of the artery is crossed with a 0.014-inch or 0.018-inch wire. Any thrombectomy device can then be introduced over the wire, and an attempt is made to remove thrombi. If normal distal flow is established without any residual stenosis, the procedure is terminated. If there is still residual thrombus, then the segment is dilated with a peripheral balloon, and if the post-percutaneous transluminal angioplasty (PTA) result is not optimal, a self-expanding stent may be deployed [13].

If a heavy thrombotic burden persists after mechanical thrombectomy, then tissue plasminogen activator (tPA) 0.05 mg/kg can be given along with heparin through a multi-hole delivery catheter (e.g. 5-Fr Mewissen). Four hours later, an angiogram can be carried out to check the progress, and if there is still a thrombus, the patient can undergo a longer infusion (12–18 hours) [13].

Limb Ischemia

Patients who develop acute limb ischemia after femoral artery catheterization must be carefully and immediately evaluated by duplex ultrasound. Angiography is mandatory and should not be delayed. The purpose of angiography is to identify the location (aortoiliac inflow circulation, infrainguinal outflow circulation, or runoff circulation) and cause (dissection, thrombosis, distal embolization, or sheath/vessel mismatch) of ischemia since these factors will help determine the treatment strategy (e.g. vascular surgery, percutaneous revascularization, thrombectomy, or intra-arterial thrombolytic infusion). In most cases, digital subtraction angiography is best, because cine angiography may not permit adequate visualization of the runoff circulation [14].

Confronting the Challenges

*****Temporary relief of iatrogenic ischemic limb: percutaneous technique for in vivo femoral artery bypass** During PTA of high-risk patients, if acute limb ischemia arises during femoral artery catheterization, the antegrade sheath in the femoral artery and the retrograde sheath in the contralateral CFA can be connected using standard 12-inch pressure tubing and a male-to-male adapter. This technique is considered a temporary method to restore blood flow, minimize the metabolic consequences of acidosis and muscle necrosis,

permit more definitive percutaneous or surgical revascularization as indicated, and allow the use of devices for invasive hemodynamic support when such devices cause limb ischemia and there are no other therapeutic alternatives [14].

Preventing limb ischemia Steps to prevent limb ischemia include (1) careful examination of femoral pulses and bruits before catheterization; (2) angiography prior to insertion of any hemodynamic support device; (3) angioplasty and stenting of suitable aortoiliac stenoses before device insertion; and (4) use of a sheathless IABP, which might reduce the risk of ischemic complications in patients with diffuse aortoiliac disease or small vessels [14].

Retroperitoneal Hematoma

The clinical clues of retroperitoneal hematoma (RPH) include hypotension without apparent reason, blood loss without possible source, suprainguinal tenderness and fullness, and flank discomfort. A small hematoma is not able to cause any hemodynamic disturbances or any increase of the retroperitoneal cavity pressure to cause neurological symptoms (Figure 1.9a).

An RPH near the iliopsoas muscle will often present severe muscle spasms, resulting in severe pain in the groin or hip area with radiation to the lower back and anterior thigh on any attempt to extend the hip. With an expanding hematoma, femoral nerve compression typically occurs along the iliopsoas gutter with a characteristic pain in the anteromedial thigh. Usually, bleeding into the retroperitoneal site is self-limiting unless the patient is anticoagulated.

Mechanism of clinical symptoms The femoral nerve is formed by the second to fourth lumbar nerve roots and provides motor innervation to the quadriceps, sartorius, pectineus, and iliopsoas. It supplies sensory innervation to the anteromedial thigh and medial leg. The nerve lies in the groove between the iliacus and psoas muscles. Entrapment of the femoral nerve by an iliopsoas hematoma is the most likely cause of femoral nerve palsy. Weakness of the quadriceps muscle and decreased patellar reflex are the most striking findings on physical examination [15].

Management of RPH includes stopping heparin and reversing anticoagulation with protamine, then rapid fluid resuscitation to reverse hypovolemia. A transfusion may be needed. The decision to intervene with evidence of persistent hemorrhage remains controversial, and a vascular surgical consultant should be involved at an early stage. The RPH will often have a tamponade effect on the site of persistent hemorrhage. Surgery could potentially reduce the effect of the tamponade with catastrophic consequences. There is a trend toward such

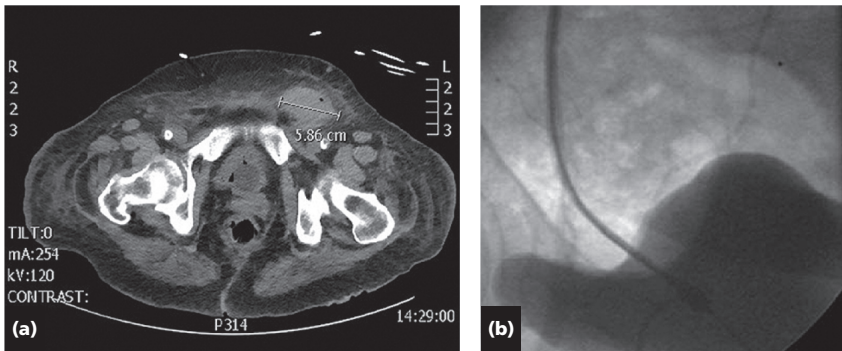


Figure 1.9 (a) A hematoma was seen in the left groin area (in the left upper corner of the CT scan of the abdomen). (b) A dented bladder due to retroperitoneal hematoma. It looks different from the normally round shape of the bladder.

techniques as stent grafts or intra-arterial embolization to halt the persistent hemorrhage. Open surgery should be considered if the patient remains hemodynamically unstable and the previously mentioned measures have been unsuccessful [16].

Discriminating Differences

Medical and surgical management of retroperitoneal hemorrhage After PCI, the presence of RPH was associated not only with a higher frequency of post-procedure cardiac complications, including myocardial infarction and congestive heart failure, but also with a higher frequency of infection and/or sepsis, gastrointestinal bleeding, and contrast nephropathy. Of the patients who developed RPH, 92.3% were treated medically and 7.7% underwent surgical repair. A trend toward higher in-hospital mortality was observed in patients with RPH treated surgically than in those treated medically, possibly reflective of the fact that a surgical approach might be performed in more unstable patients in whom fluid resuscitation and blood transfusions are inadequate in reestablishing a stable hemodynamic status [17].

Tips and Tricks

****How to detect RPH in a 1-second maneuver?** An AP view of the pelvic area under fluoroscopy may give a clue to the problem. Usually, the bladder is seen as round and filled with contrast. If the opacified bladder is seen displaced and its round shape is dented, RPH is strongly suspected (Figure 1.9b). However, a significant quantity of blood needs to be sequestered before unilateral external compression of the bladder occurs.

Real-time Actions

How to seal a perforation with a balloon The initial angiogram reveals a laceration of the IEA arising at the origin of the right CFA. A 6-Fr crossover sheath is positioned in the right external iliac artery, and a 6-Fr right Judkins-4 guide is then advanced over the crossover sheath to select the ostium of the lacerated IEA. A 0.014-inch Balanced Middleweight wire (Abbott Vascular Devices; Abbott Laboratories, Redwood City, CA, USA) is advanced into the IEA, and the tip is positioned distal to the lacerated area. A 2 × 10 mm balloon catheter is then advanced and parked at the level of the laceration and inflated at 1 atm on three sequential occasions for up to 20 minutes. Adequate balloon occlusion can be confirmed by injecting contrast through the guide. Nevertheless, if the angiogram reveals persistent and significant bleeding after each balloon deflation, attempts should be made to thrombose the lacerated vessel in order to stop the hemorrhage.

How to close a perforation with microcoil or injection of thrombin Microcoils can be used for closure of the small artery. If there are no microcoils available, infusion of thrombin through the lumen of the inflated over-the-wire balloon can be done. Careful positioning and sealing of the vessel are confirmed with injection of contrast from the guide and through the balloon lumen to ensure that there is no passage of contrast from the vessel lumen into the CFA. Thrombin-JMI (Jones Pharma, St. Louis, MO, USA) is diluted in normal saline at a concentration of 50 IU/mL. Subsequently, a total of three consecutive doses of 100 IU of thrombin can be administered through the balloon catheter lumen. Contrast can be injected through the balloon lumen after each dose of thrombin. When there is no further evidence of blood flow and no extravasation of contrast through the laceration, the balloon can be deflated [18] (Figure 1.10a–d).

Perforation

If a balloon bursts and perforates a peripheral artery below the inguinal ligament, local bleeding can be controlled by direct pressure. In the case of higher perforation, a large peripheral balloon should be inflated above or at the rupture site to stop the bleeding and to seal the puncture site [19].

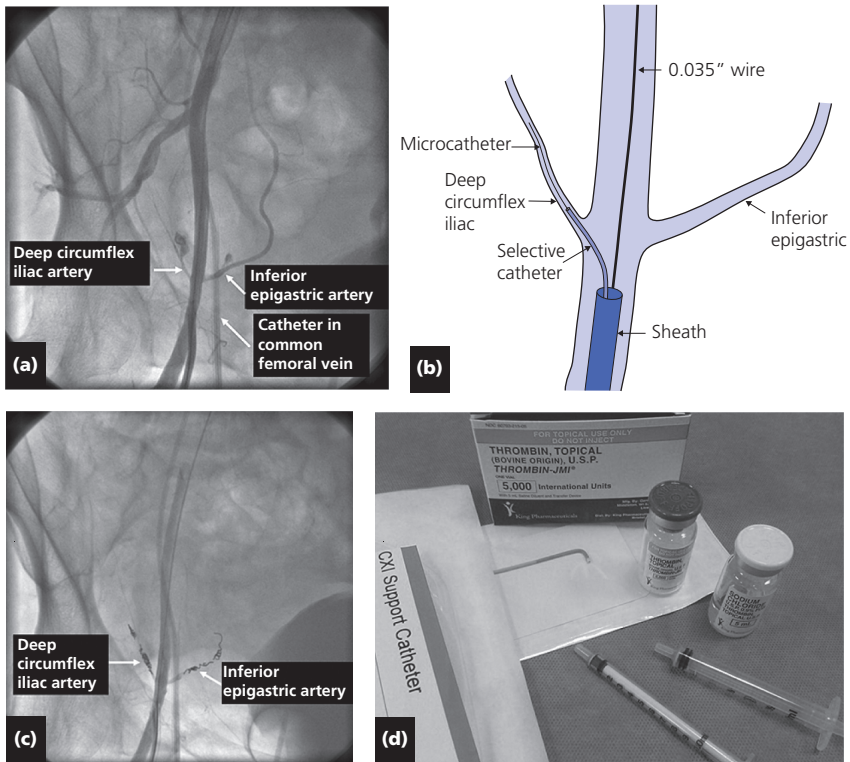


Figure 1.10 (a) After coronary stenting, an angiogram of the common femoral artery showed bleeding at the deep circumflex iliac artery, and the inferior epigastric artery. (b) A selective catheter was advanced into the deep circumflex iliac artery and with it a microcatheter was positioned near the perforated area. (c) Microcoils were delivered into the deep circumflex iliac artery and the inferior epigastric artery and successfully closed the perforations. (d) How to mix thrombin: use 2–3 mL of the patient's blood mixed with 1000–2000 units of thrombin. Inject the thrombin–blood patch into the track.

Real-time Actions

How to seal a perforation with a covered stent Access is obtained through the left femoral artery for a retrograde approach to right iliofemoral angiography. A 6-Fr internal mammary catheter is inserted over a 0.035-inch Glidewire™ (Terumo Medical Corp., Somerset, NJ, USA), and this wire is used to cross into the right SFA. The Glidewire is then exchanged for a 0.035-inch Amplatz super stiff wire, and an 8-Fr, 65-cm long Arrow-Flex® sheath (Teleflex, Wayne, PA, USA) is advanced under fluoroscopic guidance over the aortoiliac bifurcation to provide adequate support in the right external iliac artery. Balloon tamponade of the perforation site is performed by inflating a balloon at 2 atm for 5 minutes, although persistent extravasation of contrast continues. An undersized self-expanding covered stent is then placed across the perforation site, where contrast leakage persists. The stent graft is subsequently post-dilated with a balloon at 8 atm, achieving complete hemostasis and resolving the free-flow contrast into the retroperitoneum (Figure 1.11a–c).

Pseudoaneurysm

The primary cause of pseudoaneurysm (PA) is inadvertent puncture of the SFA. A femoral PA develops when the puncture site fails to close, allowing continuous blood flow into a small perivascular space surrounded by fibrous tissue and hematomas. It is suspected when a laterally

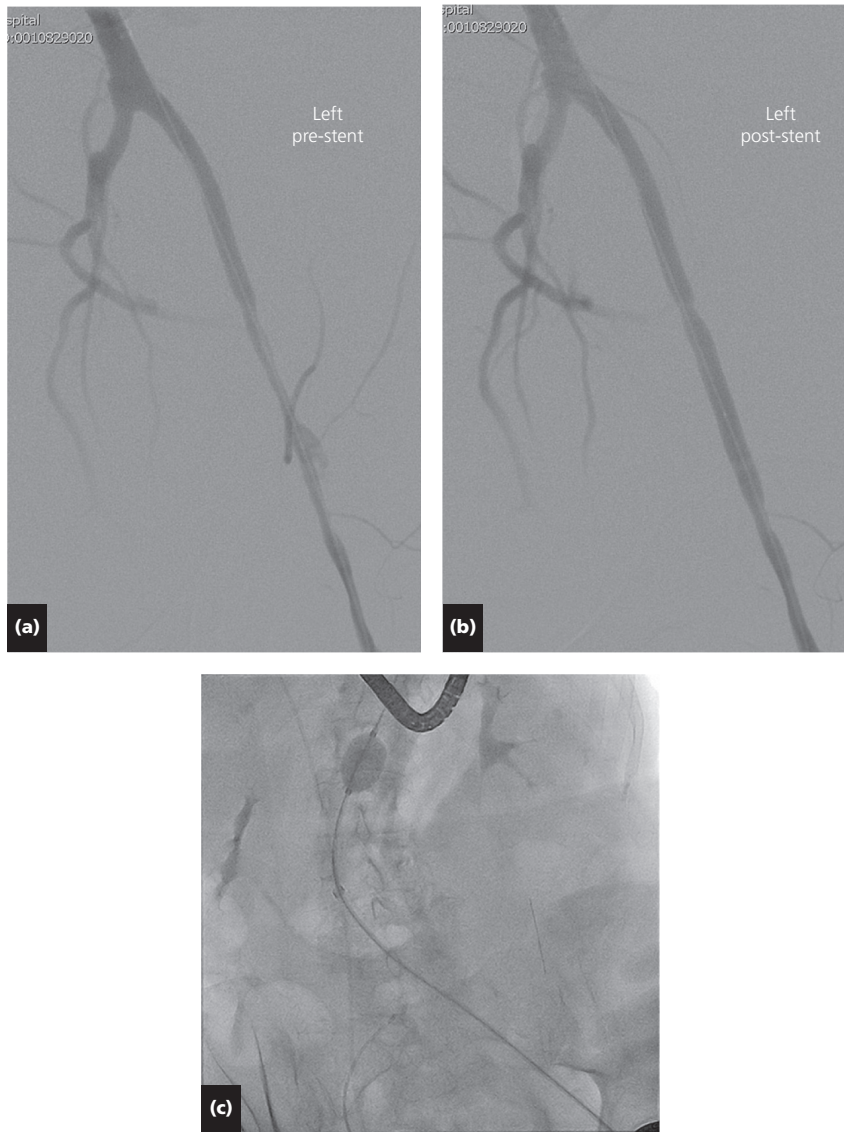


Figure 1.11 (a) and (b) Bleeding from the left external iliac artery treated with a covered stent. (c) When there is a lot of bleeding, a large aortic balloon can be inflated at the distal end of the aorta to stop the bleeding through the iliac arteries.

pulsatile mass, an arterial bruit, and tenderness at the vascular access site are present. Confirmation is made through ultrasound, which typically shows a hypoechoic cavity with blood flow through a neck, visible by color Doppler. Pulsed Doppler reveals to-and-fro flow between the cavity and the arterial lumen during systole and diastole. Hematomas appear as hypoechoic collections without Doppler flow movement.

Indications for aggressive management include a large PA size, growth in size, or the need for continued anticoagulation. Small PAs (<3 cm in diameter) often close spontaneously, likely due to thrombosis, with follow-up ultrasound 1–2 weeks later showing spontaneous thrombosis, eliminating the need for surgical intervention. PAs greater than 3 cm in diameter are less likely to resolve on their own. If the PA persists beyond 2 weeks or increases in size, the risk of femoral artery rupture necessitates intervention. The simplest method of treatment is using a mechanical compression device, such as FemoStop. The success rate for this approach is 74%, with a mean compression time of 33 minutes. In cases of failure, ultrasound-guided compression can be employed successfully.

Contraindications to mechanical compression are listed in Box 1.2. Ultrasound-guided compression is commonly used, with success dependent on anticoagulation status and the ability to easily visualize and compress the PA. The most recent treatment modality involves injecting thrombin into the PA, a quick, simple, and painless technique. Surgery is rarely required unless other management strategies fail. In rare cases, thrombin may enter the peripheral circulation, leading to intra-arterial thrombosis (seen in less than 2% of cases), which is usually managed conservatively. The ranking of each method's effectiveness in excluding a femoral PA is summarized in Box 1.3.

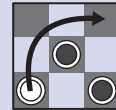
BOX 1.2 CONTRAINDICATIONS TO MECHANICAL COMPRESSION FOR PSEUDOANEURYSM

1. Sign of local infection
2. Critical limb ischemia
3. Large hematomas with overlying skin necrosis
4. Injuries above the inguinal ligament

BOX 1.3 TACTICAL MOVE

Best options for exclusion of femoral pseudoaneurysm

1. **✕ FIRST best option:** Mechanical compression therapy if there is no thrombin available
2. **\$✕ SECOND best option:** For patients **who** fail empiric compression: ultrasound-guided compression
3. **\$✕♦** For patients on anticoagulants or **having** contraindication to compression: percutaneous injection of thrombin



Femoral Dissection

Femoral artery dissection is a recognized complication of the Perclose (and other) closure devices and could occur if the needles are deployed too early and they interact with the posterior wall of the vessel or if the needles are deployed through a plaque in the anterior wall of the vessel. Meticulous attention and gentle manipulations while puncturing the artery and advancing the wire may lower the risk of access site complications. Routine femoral angiography during cardiac catheterization could lead to early diagnosis not only of arterial dissections but also of other complications, such as bleeding from laceration of the IEA.

Open surgical repair has historically been the treatment of choice for flow-limiting femoral artery dissections, but percutaneous techniques are increasingly being used to treat these injuries. Stenting of the CFA is not recommended because of the high risk of stent fracture.

Balloon angioplasty or atherectomy of the CFA might be better alternatives to stenting if they provide an acceptable angiographic result.

Patients with non-flow-limiting iliac artery dissections can often be treated conservatively because the blood flow tends to “tuck” iliac dissections caused during retrograde insertion of catheters, wires, or other equipment. Conservative management for non-flow-limiting dissections consists of bed rest with follow-up noninvasive imaging and clinical exams. If dissections are flow-limiting, then stenting (using self-expanding stents for the external iliac artery or either self-expanding or balloon-expandable stents for the common iliac artery) may be the treatment of choice.

CASE REPORT

Retrograde Abdominal and Thoracic Dissection from the Iliac Artery

A patient with suspected coronary disease was prepared for cardiac catheterization via the femoral approach. A standard right femoral artery puncture was performed, and the wire passed easily to the mid-aorta. However, there was difficulty advancing the wire and the catheter beyond the aortic arch, and the procedure was abandoned. Half an hour later, the patient complained of severe back pain and became temporarily hypotensive. A computed tomography (CT) scan confirmed the aortic dissection, with the entry point in the iliac artery extending to the aortic arch. Initially, the patient was managed conservatively, but she had recurrent transient episodes of severe back pain associated with transient hypotension (75/40 mmHg), so, under fluoroscopic guidance, a 10 mm × 4 cm stent was placed in the right common iliac artery via the contralateral femoral approach. The new stent occluded the entry point. Follow-up CT showed thrombosis of the false lumen and sealing of the dissection flap. The favorable outcome in this patient was likely due to two factors: (1) the retrograde direction of the dissection, in contrast to the antegrade direction of the usual spontaneous aortic dissection and (2) the absence of re-entry, which contributed to stagnation of blood flow in the false lumen, resulting in the formation of thrombus and the rapid disappearance of the retrograde dissection [21].

REFERENCES

1. Bogart DB, Bogart MA, Miller JT, et al. Femoral artery catheterization complications: a study of 503 consecutive patients. *Catheter Cardiovasc Diagn* 1995;**34** (1):8–13.
2. Cilingiroglu M, Feldman T, Salinger MH, et al. Fluoroscopically-guided micropuncture femoral artery access for large-caliber sheath insertion. *J Invasive Cardiol* 2011;**23**:157–61.
3. Millán X, Azzalini L, Khan R, et al. Efficacy of a balloon-expandable vascular access system in transfemoral TAVI patients. *Catheter Cardiovasc Intervent* 2016;**88**:1145–52.
4. Nicholson WJ, Rab T. Simultaneous diagnostic coronary angiography utilizing a single arterial access technique. *Catheter Cardiovasc Intervent* 2006;**68**:718.
5. Biondi-Zoccai GG, Agostoni P, Sangiorgi G, et al. Mastering the antegrade femoral artery access in patients with symptomatic lower limb ischemia: Learning curve, complications, and technical tips and tricks. *Catheter Cardiovasc Intervent* 2006;**68**:835–42.
6. Lotun K, Shetty R, Patel M, Arain SA. Percutaneous left axillary artery approach for Impella 2.5 liter circulatory support for patients with severe aortoiliac arterial disease undergoing high risk percutaneous coronary intervention. *J Interv Cardiol* 2012;**25**:210–3.
7. Dugas CM, Schussler JM, Yoon AD. *An Easier Way to Obtain Access for Right Heart Catheterization during Transradial Left Heart Catheterization*. <http://www.scai.org/Coronary/Hack.aspx?cid=b665c224-c032-4aa8-ade2-7aa9c2c74c7b>

8. Feldman T. Femoral arterial preclosure: Finishing a procedure before it begins. *Cathet Cardiovasc Interv* 2001;**53**:448.
9. Bui QT, Kolansky DM, Bannan A, Herrmann HC. "Double wire" Angio-Seal closure technique after balloon aortic valvuloplasty. *Catheter Cardiovasc Interv* 2010;**75**:488–92.
10. Korngold EC, Inglessis I, Garasic JM. A novel technique for 14 French arteriotomy closure after percutaneous aortic valvuloplasty using two Mynx closure devices. *J Interv Cardiol* 2009;**22**:179–83.
11. Schwartz B, Burstein S, Economides C, et al. Review of vascular closure devices. *J Invasive Cardiol* 2010;**22**:599–607.
12. Stein B, Terstein P. Non-surgical removal of Angio-Seal Device after intraarterial deposition of collagen plug. *Cathet Cardiovasc Interv* 2000;**50**:340–2.
13. Samal A, White C. Percutaneous management of access site complications. *Catheter Cardiovasc Intervent* 2002;**57**:12–23.
14. Merhi WM, Turi ZG, Dixon S, et al. Percutaneous ex-vivo femoral arterial bypass: A novel approach for treatment of acute limb ischemia as a complication of femoral arterial catheterization. *Catheter Cardiovasc Intervent* 2006;**68**:435–40.
15. Raja Y, Lo TS, Townend JN. Don't rule out retroperitoneal bleeding just because the angiogram was done from the radial artery. *J Invasive Cardiol* 2010;**21**:E3–4.
16. Frank JJ, Kamalakannan D, Kodenchery M, et al. Retroperitoneal hematoma in patients undergoing cardiac catheterization. *J Interv Cardiol* 2010;**23**:569–74.
17. Trimarchi S, Smith DE, Share D, et al. Retroperitoneal hematoma after percutaneous coronary intervention: prevalence, risk factors, management, outcomes, and predictors of mortality: a report from the BMC2 (Blue Cross Blue Shield of Michigan Cardiovascular Consortium) Registry. *JACC Cardiovasc Interv* 2010;**3**:845–50.
18. Silva JA, Stant J, Ramee SR. Endovascular treatment of a massive retroperitoneal bleeding: successful balloon-catheter delivery of intra-arterial thrombin. *Catheter Cardiovasc Intervent* 2005;**64**:218–22.
19. Chambers CE, Griffin DC, Omarzai RK. The "dented bladder": Diagnosis of a retroperitoneal hematoma. *Cathet Cardiovasc Diagn* 1993;**34**:224–6.
20. Zahn R, Thoma S, Fromm E, et al. Pseudoaneurysm after cardiac catheterization: Therapeutic interventions and the sequelae: Experience in 86 patients. *Cathet Cardiovasc Diagn* 1997;**40**:9–15.
21. Prasad A, Compton PA, Prasad A, et al. Incidence and treatment of arterial access dissections occurring during cardiac catheterization. *J Interv Cardiol* 2008;**21**:61–6.