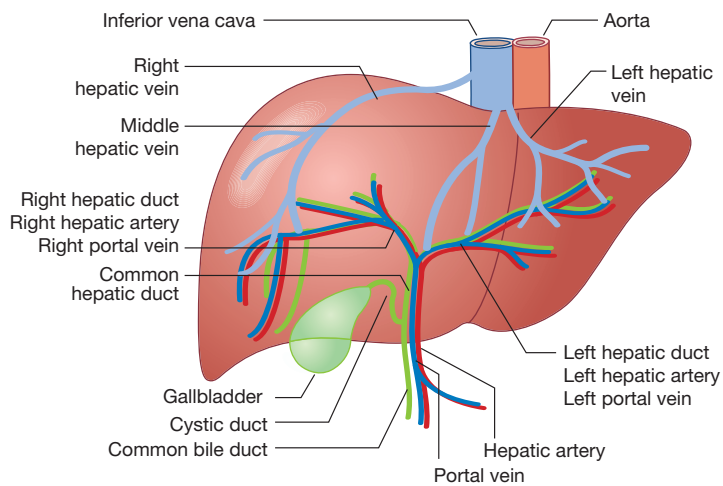


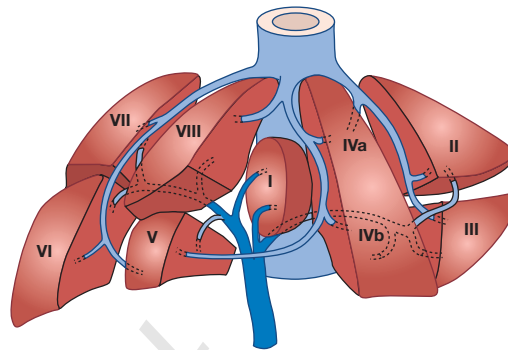
1

Liver and biliary anatomy and structure

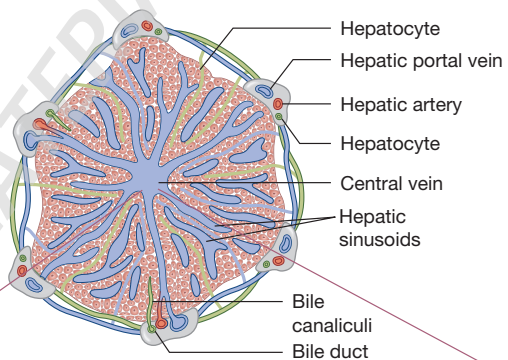
Blood supply of the liver



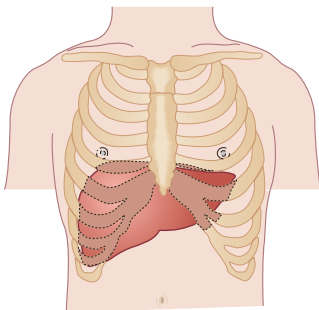
Segments of the liver



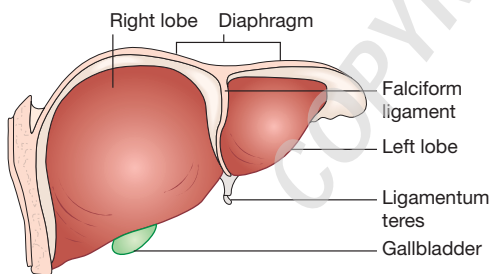
Basic structure of liver lobule



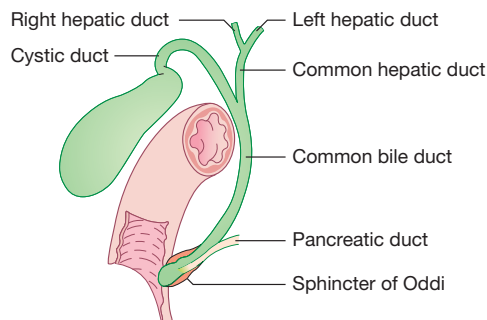
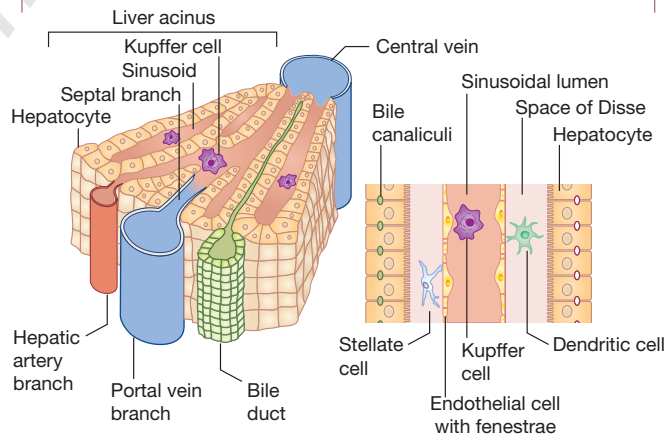
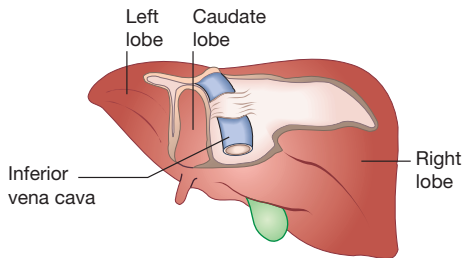
Position of the liver



Anterior view



Posterior view



Development

The liver begins as a hollow endodermal bud from the foregut (duodenum) in the third week of gestation. The bud then separates into the hepatic and biliary components. The hepatic part contains bipotential progenitor cells that differentiate into hepatocytes or ductal cells, which form the early biliary duct plates. These rapidly proliferating cells penetrate adjacent mesodermal tissue (septum transversum) and are met by a growing vascular capillary plexus from the vitelline and umbilical veins, which form the sinusoids. The gallbladder and extra-hepatic bile ducts are formed from the connection of these proliferating cells and the foregut. The liver structure is formed by epithelial liver cords that differentiate into hepatocytes, bile canaliculi and hepatic ducts. Bile flows from the 12th week. Kupffer cells are derived from circulating monocytes while hepatic stellate cells are derived from submesothelial cells.

Macro liver and biliary anatomy

The liver is the largest internal organ, weighing 1.2–1.5 kg. It is surrounded by a capsule of connective tissue (Glisson's capsule). It is situated in the right upper quadrant, shielded by the ribs and moves with respiration due to attachment to the diaphragm. The upper border lies at the level of the nipples/fifth rib. The liver contains two lobes: the larger **right** lobe, which also contains the **caudate** (posterior surface) and **quadrate** (inferior surface) lobes, and the **left** lobe. The two lobes are separated anteriorly by the **falciform ligament**, posteriorly by the **ligamentum venosum** and inferiorly by the **ligamentum teres**. The **middle hepatic vein** runs between the right and left lobes. The liver can be further divided into eight segments based on the division of the right middle and left hepatic veins.

The **right and left hepatic biliary ducts** exit the liver and unite at the hilum to form the **common hepatic duct**. The **gallbladder** is situated above the transverse colon. The body of the gallbladder narrows at the neck before becoming the cystic duct. The **cystic duct** then joins to form the **common bile duct**. The common bile duct lies anterior to the portal vein and passes behind the first part of the duodenum before entering the second part of the duodenum. It joins the pancreatic duct to form a common channel, the **ampulla of Vater**. In the duodenum, the ampulla forms a membranous bulge, the major duodenal papilla. The **sphincter of Oddi** comprises thickened longitudinal and circular muscle fibres and is the duodenal component of the common bile duct. It contracts intermittently, controlling the release of bile.

Blood and lymphatic supply

The liver has a dual blood supply from the **portal vein** and the **hepatic artery**. Approximately 25% of the liver's blood supply is supplied by the hepatic artery, which originates from the **coeliac axis**. The portal vein provides 75% of the liver's blood supply and

returns venous blood from the gastrointestinal tract and spleen. Both vessels enter the liver through the **porta hepatis (liver hilum)**. Inside the hilum, the portal vein and hepatic artery divide into the right and left branches, supplying their respective lobes before being distributed to the segments and flowing into the **sinusoids** via the portal tracts. Blood leaves the sinusoids and then enters tributaries of the hepatic veins (middle, right and left) before entering the **inferior vena cava**. The caudate lobe receives a separate blood supply from the portal vein and hepatic artery while its hepatic vein drains directly into the inferior vena cava.

The **cystic artery** provides the gallbladder's blood supply while drainage is via the **cystic vein**. The majority of the blood supply to the bile ducts is from the **retroduodenal and right hepatic arteries**.

Lymph collects in the portal tracts and enters larger vessels before entering the hepatic ducts.

Micro liver structure

Liver lobes are made up of microscopic units called lobules which are hexagonal in shape. The **acinus** is the functional structural unit of the liver. It is an elliptical unit with a **portal triad** at the centre, a **central vein** at each pole and has three zones:

- **Zone 1: periportal**. Contains most oxygenated blood. Most susceptible to damage from toxins entering the liver. Performs the majority of metabolic activity;
- **Zone 2: midzone**;
- **Zone 3: centrilobular**. Closest to the central vein. Most susceptible to ischaemic damage;

Hepatocytes are arranged in cords which radiate out from the central vein. Blood-filled sinusoids form networks between the hepatocytes which are lined with a fenestrated endothelium. Between the hepatocytes and **sinusoidal endothelial cells** is the **perisinusoidal space of Disse** which contains **Kupffer cells** and **hepatic stellate cells**. Kupffer cells have phagocytic capacity and are the resident hepatic macrophages. Hepatic stellate cells store vitamin A and produce collagen in response to injury. Microvilli are seen at the sinusoidal surface and increase the surface area for transfer of oxygen, nutrients and so on between blood in the sinusoids and hepatocytes. **Bile canaliculi** are formed by a channel between two surfaces of hepatocytes and are sealed by **zonulae occludentes**. They join to form bile ductules in the portal tracts by opening into **canals of Hering**. These canals drain bile into the biliary ductule of the portal tracts.

Anatomical abnormalities

Riedel's lobe

This is an anatomical variation characterised by a downward projection of the right lobe of the liver. It moves with respiration and can descend as far down as the right iliac fossa. It is more common in women but is usually asymptomatic.