
Limb Lengthening and Reconstruction Surgery Case Atlas

S. Robert Rozbruch • Reggie C. Hamdy •
Austin T. Fragomen • Mitchell Bernstein
Editors

Limb Lengthening and Reconstruction Surgery Case Atlas

Adult Deformity – *S. Robert Rozbruch*

Tumor – *Taylor J. Reif*

Upper Extremity – *John E. Herzenberg*

Second Edition

With 1715 Figures and 2 Tables

 Springer

Editors

S. Robert Rozbruch
Department of Orthopedic Surgery
Hospital for Special Surgery
New York, NY, USA

Reggie C. Hamdy
Department of Pediatric Surgery
Shriners Hospital - Canada
Montreal, QC, Canada

Austin T. Fragomen
Department of Orthopedic Surgery
Hospital for Special Surgery
New York, NY, USA

Mitchell Bernstein
Departments of Surgery & Pediatric Surgery (Division of
Orthopaedics)
McGill University Health Center & Shriners Hospital for
Children - Canada
Maywood, IL, USA

ISBN 978-3-031-77356-3 ISBN 978-3-031-77357-0 (eBook)
<https://doi.org/10.1007/978-3-031-77357-0>

© Springer Nature Switzerland AG 2015, 2024

This work is subject to copyright. All rights are solely and exclusively licensed by the Publisher, whether the whole or part of the material is concerned, specifically the rights of translation, reprinting, reuse of illustrations, recitation, broadcasting, reproduction on microfilms or in any other physical way, and transmission or information storage and retrieval, electronic adaptation, computer software, or by similar or dissimilar methodology now known or hereafter developed.

The use of general descriptive names, registered names, trademarks, service marks, etc. in this publication does not imply, even in the absence of a specific statement, that such names are exempt from the relevant protective laws and regulations and therefore free for general use.

The publisher, the authors and the editors are safe to assume that the advice and information in this book are believed to be true and accurate at the date of publication. Neither the publisher nor the authors or the editors give a warranty, expressed or implied, with respect to the material contained herein or for any errors or omissions that may have been made. The publisher remains neutral with regard to jurisdictional claims in published maps and institutional affiliations.

Cover illustration: Artist: Yonina Jacobs, "New Growth" 2010, Assemblage: acrylic on canvas, 33" × 15"

This Springer imprint is published by the registered company Springer Nature Switzerland AG.
The registered company address is: Gewerbestrasse 11, 6330 Cham, Switzerland

If disposing of this product, please recycle the paper.

To my wife, Yonina, and our children, Jason and Nicole and Libby and Brett, whose love and support make me smile and give me strength every day.

S. Robert Rozbruch

I dedicate this second edition of the Atlas to my wife Sylvie and my son Sebastien for their relentless and unwavering support during the completion of this new edition. To my late parents, who will always remain my guiding light. To my mother, whose sweet and comforting voice will forever resonate in my ears. To my father, the best mentor I would ever have dreamed of having. He will not see this Atlas, but I am sure he would have been very proud of it. To all my colleagues for their invaluable help and especially to all the children and adolescents I have treated, you have been the most amazing inspiration to me.

Reggie C. Hamdy

I would like to dedicate this book to my mentors, John Denton, Eugene Wolf, and S. Robert Rozbruch. These giants shaped me as a surgeon and helped me hone in on my career path. It has been my greatest honor to join my close friend Rob Rozbruch and journey together to shape this world of limb lengthening and reconstruction. I thank my family for supporting my demanding clinical academic career. And most importantly, I thank my patients for trusting me and teaching me the true art of medicine.

Austin T. Fragomen

To my wife, Neilly: I love you dearly, and thank you for your continued support and encouragement. To our two wonderful children, Asher and Avery, whose boundless curiosity and joy remind me daily of the magic of learning. This work is dedicated to you, with all my gratitude.

Mitchell Bernstein

Preface

Nine years after publication of the first edition, we are pleased to present the second edition of the *Limb Lengthening and Reconstruction Surgery Case Atlas*. The clinical work presented and the amazing subspecialty of orthopedic surgery it represents has come a long way since our first edition in 2015. Now well known internationally and in the USA, the limb lengthening community is recognized as a distinct and critical area of orthopedics despite its apparent overlap with other subspecialties. No longer entirely reliant on external fixators, we routinely use internal fixation for complex deformity correction, lengthening, bone defect management, and limb salvage. The precision we achieve in surgery is based on the core principles and the new techniques that have been developed. The evolution to the new often borrows from the old knowledge using circular external fixation. We have transitioned from the sole use of external fixation to integrated techniques and to the frequent use of internal fixation. While we have a variety of powerful tools available to tackle complex limb reconstruction cases, different surgeons will use varying approaches and techniques based on both their preferences and also the resources available in their locations. For that reason, none of the cases presented in this book are out of date.

Techniques presented include classic circular external fixation, hexapod external fixation, integrated techniques such as lengthening and then nailing (LATN), lengthening over a nail (LON), bone transport over a nail, bone transport and then nailing, and fully internal techniques of internal lengthening nailing, opening and closing wedge osteotomies with plates, deformity correction with intramedullary nailing and blocking screws, plate-assisted bone segment transport, and internal bone transport nail. Also included is amputation reconstruction with osseointegration limb replacement.

The second edition of the atlas has a total of 481 cases in 6 sections presented in 3 volumes.

Limb Lengthening and Reconstruction Surgery Case Atlas—Trauma • Foot and Ankle—135 cases

Limb Lengthening and Reconstruction Surgery Case Atlas—Pediatric Deformity—152 cases

Limb Lengthening and Reconstruction Surgery Case Atlas—Adult Deformity • Tumor • Upper Extremity—194 cases

We have found case-based learning to be especially enjoyable and educationally effective. As orthopedic deformity surgeons, we are visual, practical, and creative. It is natural for most of us to teach and learn by assembling a case for presentation.

The chapter format used in this case atlas mimics my own personal approach to evaluating and treating a patient, which includes a detailed history and physical examination, analysis and measuring radiographs, and synthesis of a problem list. This exercise enables analysis of a very complicated case, first by breaking it down to its composite parts. The patient then becomes less complicated enabling the formation of a treatment strategy based on principles to address all component parts of the problem list. This often demands creativity and some courage but since the plan is based on sound principles, it is less intimidating. With increasing experience, I have been able to utilize technical tricks and these “pearls” are most helpful in surgery. I have learned

to think a couple steps ahead and have a backup plan or two in order to avoid and manage complications. I diligently document cases in a photo database to be used for patient and colleague education as well as research. This has been my approach to limb deformity practice over the last 25 years.

The format of this case atlas continues to be uniform and is aligned with my approach to evaluating and treating patients. Each case/chapter contains this flow:

1. Abstract
2. Basic clinical history
3. Preoperative photos and x-rays
4. Problem list
5. Treatment strategy
6. Basic principles
7. Photos and x-rays during treatment
8. Technical pearls
9. Outcome photos and x-rays
10. Avoiding and managing complications
11. References and additional reading

I want to thank our brilliant contributors from around the world. With a large collection of cases, the reader will be exposed to an array of limb lengthening and reconstruction surgery. You will also notice similar cases presented by different authors who use differing approaches. Our field has less uniformity and more creativity than our sibling subspecialties. Furthermore, I want to thank my friends and co-editors, Reggie Hamdy, Austin Fragomen, and Mitchell Bernstein and section editors, Taylor Reif and Jason Hoellwarth without whom this project would not have been possible. I am pleased that this publication is endorsed by the Limb Lengthening and Reconstruction Society (LLRS) of North America, an organization that we have all been active in.

Additional gratitude goes to the fantastic Springer team, including Kristopher Spring who helped initiate the project and our wonderful, energetic, and organized editorial team led by Swetha Varadharajan. I also want to thank my mentors Dror Paley, John Herzenberg, Munjed AlMuderis, Russ Warren, Tom Sculco, and David Helfet from whom I have learned so much. I am grateful for having had the opportunity to teach and train many fellows and residents who have taught and energized me over the last 25 years.

Finally, a special thanks to my wife, Yonina and my children, Jason and Nicole and Libby and Brett whose love and encouragement make me smile and give me strength every day.

New York, USA
December 2024

S. Robert Rozbruch, MD

Booknotes

This book is part of a set consisting of three volumes:

Volume 1: “Pediatric Deformity”

Section: Pediatric Deformity – *Reggie C. Hamdy and Jason S. Hoellwarth*

Contents: Pediatric Lower Extremity Trauma

- Growth Plate Injuries
- Congenital Pseudarthrosis of the Tibia and Fibula
- Congenital Lower Limb Deficiencies
- Pediatric Blount Disease
- Pediatric Arthrogyposis
- Pediatric Skeletal Dysplasias
- Pediatric Metabolic and Vascular Disorders
- Pediatric Hip Deformities
- Pediatric Foot and Ankle Deformities
- Pediatric Chronic Osteomyelitis
- Pediatric Rotational Deformities
- Pediatric Rotational Deformities (Miserable Malalignment)

Volume 2: “Trauma • Foot and Ankle”

Section: Trauma – *Mitchell Bernstein*

Contents: Femoral Reconstruction

- Tibial Reconstruction
- Intentional Deformation Tibia
- Bone Defect—Integrated Fixation
- Acute trauma—External
- Acute trauma—External Fixation
- Bone Defect—External Fixation
- Bone Defect—Internal Fixation
- Malunion—External Fixation
- Malunion—Internal Fixation
- Nonunion—External Fixation
- Nonunion—Internal Fixation
- Osteomyelitis

Section: Foot and Ankle – Austin T. Fragomen

Contents: Ankle Arthrodesis
Charcot Neuroarthropathy
Complex Foot Deformity
Contracture
Distraction Arthroplasty
Metatarsal Reconstruction
Supramalleolar Osteotomy (SMO)

Volume 3: “Adult Deformity • Tumor • Upper Extremity”**Section: Adult Deformity – S. Robert Rozbruch**

Contents: Internal Lengthening Nail
Femoral Deformity
Tibial Deformity
Multiple Segment Deformity
Integrated Fixation
Hip
Knee
Knee Fusion
Bone Defect
Amputation Reconstruction

Section: Tumor – Taylor J. Reif

Contents: Benign Bone Tumor
Malignant Bone Tumor
Failed Initial Treatment
Sequela of Resection

Section: Upper Extremity – John E. Herzenberg

Contents: Upper Limb: Humerus
Upper Limb: Humerus
Upper Limb: Elbow and Forearm
Upper Limb: Hand and Wrist
Upper Limb: Trauma
Upper Limb: Amputation

Contents

Volume 1

Part I Adult Deformity	1
1 Adult Deformity: An Introduction	3
S. Robert Rozbruch	
Part II Adult Deformity: Internal Lengthening Nail	5
2 Both Femur and Tibial Shortening Caused from Hemi-hyperthopia Treated Simultaneously with Two Antegrade Precice Nails	7
Metin Kucukkaya	
3 Combined Deformities of the Femur and Tibia with 9 cm Shortening Treated with a Retrograde Femoral Motorized Lengthening Nail and a Tibial Plate	13
Metin Kucukkaya and Ozgur Karakoyun	
4 Congenital Femoral and Tibial Shortening Internally Lengthened with an ISKD and a Precice Nail	17
Pablo Wagner and John E. Herzenberg	
5 Femoral Lengthening (12 cm) with Two Precice Nail Lengthenings. Management of a Broken Precice Nail During the First Lengthening	23
Metin Kucukkaya	
6 Femoral Lengthening with Fitbone Nail Treated with “Sandwich Technique” to Remedy Non-union Then Lengthened with Precice Nail at Allogeneous Fresh Frozen Strut Graft Site	29
Metin Kucukkaya and Sami Sokucu	
7 Femur Lengthening with Precice Internal Lengthening Nail	33
S. Robert Rozbruch	
8 Limb Lengthening of 14 cm with Simultaneous Deformity Correction of Femur and Tibia by Fully Implantable, Electric Driven Lengthening Nails	41
Peter Helmut Thaller and Tobias Helfen	
9 LLD After Total Hip Replacement Treated with Precice Nail	49
Pablo Wagner, Renee Hunter, and John E. Herzenberg	
10 Malaligned and Short Femur Associated with Vascular Deficit – 2 Stage Realignment and Lengthening with Custom Made Magnetic Driven Intramedullary Nail	55
Peter Helmut Thaller and Felix Frankenberg	

11	Partial Union After Lengthening: A New Concept in Bone Healing	63
	Pablo Wagner, Burkley Jensen, and John E. Herzenberg	
12	Tibia Lengthening with Precice Internal Lengthening Nail	67
	S. Robert Rozbruch	
13	Tibial Lengthening Using a PRECICE Nail	73
	Matthew Wagoner, Pablo Wagner, and John E. Herzenberg	
14	Clamshell Osteotomy and Retrograde PRECICE Lengthening	79
	John A. Scolaro	
15	Lengthening and Valgus Correction of the Femur with a Retrograde Internal Lengthening Nail	87
	Stephen J. Wallace and S. Robert Rozbruch	
16	Bilateral Femur Stature Lengthening with Precice Stryde Nails	93
	Amber A. Hamilton, Danya M. Jacobs, and S. Robert Rozbruch	
Part III	Adult Deformity: Femoral Deformity	97
17	Acute Correction of Multiplane Deformity and Bone Defect as a Result of Complication After Distal Femoral Opening Wedge Osteotomy	99
	Lee Donghoon	
18	Correction of Complex Femur Periprosthetic Deformity	105
	Leonid N. Solomin, Elena Shchepkina, Fanil Sabirov, Sergei Lasunsky, and Evgenii Golovenkin	
19	Double Level Osteotomy of the Femur for Severe Genu Valgum with Femoral Retroversion	111
	Stephen J. Wallace and Austin T. Fragomen	
20	Extra-articular Deformity Correction and then Staged THR and TKR	115
	Jason S. Hoellwarth and S. Robert Rozbruch	
21	Proximal Femur Malunion After Intramedullary Nailing Treated with Deformity Correction with a Blade Plate	123
	Hobie Summers	
22	Spring (“Lazy Russian”) Technique for Simultaneous Multi-apical Deformity Correction	127
	Leonid N. Solomin, Konstantin L. Korchagin, Fanil Sabirov, and Elena Shchepkina	
23	THR and Femur Osteotomy for Tuberculosis Induced Deformity	133
	Jason S. Hoellwarth and S. Robert Rozbruch	
24	Bilateral Distal Femoral Osteotomy, Opening Wedge with Plate, for Genu Valgum	137
	S. Robert Rozbruch	
25	Complex Femoral Deformity: Acute Correction and IM Nail Fixation	143
	Mahmoud A. El-Rosasy	
26	Femoral Shaft Varus Above a Total Knee Replacement Treated with a Circular Hexapod Fixator	149
	Petr Skomoroshko, Leonid N. Solomin, Viktor Vilenskiy, and Fanil Sabirov	
27	Periarticular Femur Deformity and LLD: A Modern Approach	153
	Austin T. Fragomen	

Part IV Adult Deformity: Tibial Deformity	159
28 Complex Tibial Deformity: Acute Correction and IM Nail Fixation	161
Mahmoud A. El-Rosasy	
29 Computer Assisted External Fixation for Aesthetic Changing Lower Limb Shape	165
Pavel Kulesh and Leonid N. Solomin	
30 Correction of Bilateral Genu Varum for a High Level Athlete	169
Austin T. Fragomen	
31 Gradual Correction of Distal Tibial Varus Deformity	175
Megan M. Riedel and Janet D. Conway	
32 Treatment of Posterior Tibial Nerve Impingement After Tibial Lengthening	179
Dong Hoon Lee	
33 Distal Tibial Nonunion Repair Through Distraction Osteogenesis Using an Automatic Hexapod Frame	187
Stephen J. Wallace and Austin T. Fragomen	
34 Leg Length Discrepancy Combined with Genu Recurvatum and Genu Valga as Sequela of Growth Plate Injury	193
Lee Donghoon	
Part V Adult Deformity: Multiple Segment Deformity	199
35 Complex Deformity After PFFD Treatment – Multifocal, Gradual Correction on Femur and Tibia with Monolateral External Fixation	201
Peter Helmut Thaller and Sami Sokucu	
36 Complex Four Segment Multiapical Lower Extremity Deformities in Rickets Treated with Fixator Assisted Intramedullary Nailing	207
Mehmet Kocaoglu and F. Erkal Bilen	
37 Correction of Valgus-Torsion Deformity of the Femur and Varustorsion Deformity of the Lower Leg Accompanied with LLD	215
Leonid N. Solomin and Pavel Kulesh	
38 Correction of Varus Deformity of the Femur and Tibia in Patient with LCL Laxity	223
S. Robert Rozbruch	
39 Correction of Windswept Rotational Deformity with Fixator Assisted Plating Technique	231
Mitchell Bernstein and S. Robert Rozbruch	
40 Femoral and Tibial Rotational Deformity Treated with Fixator Assisted Nailing and Gradual Correction with The Taylor Spatial Frame	239
Vikrant Landge and Janet D. Conway	
41 Intraoperative SSEP Monitoring of Circular External Fixation in Achondroplasia	247
Marina Makarov, Lori Karol, and Mikhail Samchukov	

42	Multiapical Deformity Correction in Bilateral Femur and Tibia in Rickets. LAMP Technique to Decrease the Time of External Fixator	255
	León Gonzalo Mora Herrera	
43	Multiapical Deformity of Knee, Tibia, and Ankle Treated with Osteotomy, Arthrodesis, and Arthroplasty	265
	S. Robert Rozbruch	
44	Treatment of Complex Deformity of the Lower Extremities in Hypophosphatemic Rickets Using a Six-Pod Frame and Fixator Assisted Plating	271
	Dong Hoon Lee	
45	Dual Femoral and Tibial Osteotomies with Internal Fixation for Acute Valgus Correction	277
	Stephen J. Wallace and S. Robert Rozbruch	
46	Dual Femoral/Tibial Osteotomies and LCL Reconstruction for Genu Varum and Knee Instability	283
	Stephen J. Wallace and Austin T. Fragomen	
47	Leg Length Discrepancy Correction with Femur and Tibial Lengthening Using Precise Nails	289
	Amber A. Hamilton, Danya M. Jacobs, and S. Robert Rozbruch	
48	Lengthening and Correction of Femur Malunion Followed by High Tibial Osteotomy	295
	Stephen J. Wallace and S. Robert Rozbruch	
49	Multisegment (Femur, Lower Leg, Foot) Multilevel Staged Deformity Correction	301
	Elena Shchepkina, Fanil Sabirov, and Leonid N. Solomin	
50	Oblique Joint Line of the Knee Treated with Distal Femur and Proximal Tibial Osteotomies	309
	Doron Keshet and Mitchell Bernstein	
Part VI	Adult Deformity: Integrated Fixation	315
51	Acute Correction of Combined Deformity of the Tibia by Double Level Osteotomy and Fixator Assisted Plating Technique	317
	Dong Hoon Lee	
52	Acute Correction of Tibial Deformity and Plate Fixation, with Subsequent Lengthening Over Plate	325
	Mahmoud A. El-Rosasy	
53	Acute Correction with Marrow (Intramedullary Canal) Narrowing Technique and Subsequent Lengthening Over Nail for the Femoral Shortening Combined with a Deformity	331
	Dong Hoon Lee	
54	Simultaneous Lengthening and Deformity Correction over Customized Intramedullary Locking Nail (LON) for Multidimensional Deformity of the Proximal Tibia	339
	Peter Helmut Thaller and Florian Wolf	
55	HEX-Based Femur Lengthening over the Nail	349
	Elena Shchepkina, Leonid N. Solomin, and Fanil Sabirov	

56	Infected Distal Femur Nonunion Treated with a Circular External Fixator Then Internal Lengthening Nail	355
	Stephen J. Wallace and Austin T. Fragomen	
Part VII	Adult Deformity: Hip	363
57	Advanced Hip Arthrosis, Massive Perceived LLD and Pelvic Obliquity due to Adduction Contracture Treated with THR	365
	Amgad M. Haleem and S. Robert Rozbruch	
58	Ipsilateral Secondary Hip Osteoarthritis and Leg Length Discrepancy: Treated Simultaneously with Total Hip Replacement and Motorized Lengthening	373
	Metin Kucukkaya and Abdullah Gogus	
59	Staged Revision of a Chronic Infected Ipsilateral THA and TKA Using an Antibiotic Laden PMMA Functional Spacer Incorporating a Knee Fusion Nail	377
	Stephen Kent and Kevin Tetsworth	
60	Staged Total Hip Arthroplasty and Femoral Lengthening for Chronic Developmental Hip Dysplasia	385
	Taylor J. Reif and S. Robert Rozbruch	
Part VIII	Adult Deformity: Knee	391
61	Bilateral Genu Varum and LLD Corrected with an Internal Lengthening IMN and Contralateral HTO	393
	Austin T. Fragomen	
62	Knee Joint Osteochondral Reconstruction Using Fresh Femoral Head Autograft	399
	Tamer Mettyas, Patrick Weinrauch, and Kevin Tetsworth	
63	Neglected Rotatory Knee Dislocation Treated with the Taylor Spatial Frame	407
	Amgad M. Haleem and S. Robert Rozbruch	
64	Reconstruction of a Lateral Femoral Condyle Articular Surface Defect with a Fresh Osteochondral Allograft	413
	Constantin Edmond Dlaska and Kevin Tetsworth	
65	Salvage of an Infected Malunion of a Lateral Tibial Plateau with Staged Revision to a Bulk Osteochondral Allograft and Associated Lateral Meniscal Transplant	421
	Kevin Tetsworth	
66	Sustained Clinical and Structural Benefit After Five Years Following Joint Distraction in the Treatment of Severe Knee Osteoarthritis	429
	Peter M. van Roermund	
67	Treatment of Severe Knee Joint Stiffness with Soft Tissue Release and External Fixation	435
	Leonid N. Solomin and Konstantin L. Korchagin	
68	Adolescent Blounts with Joint Line Depression Treated with Staged Osteotomies	441
	Doron Keshet and Mitchell Bernstein	

69	Extra-Articular Deformity Correction for Staged Revision Total Knee Replacement	449
	Stephen J. Wallace and S. Robert Rozbruch	
70	Four-Segment Reconstruction and Hemi-plateau Elevation for Severe Genu Varum with Blount's Disease	455
	Stephen J. Wallace and Austin T. Fragomen	
71	Knee Distraction for OA: Technical and Biomechanics Tips	461
	Hemant K. Sharma and Paul Harwood	
72	Leg Length Discrepancy Combined with Multiplane Deformities and Recurrent Patella Dislocation	467
	Lee Donghoon	
73	Minimally Invasive (2 cm Incision) Tibial Plateau Elevation and Stabilization with Frame	477
	Hemant K. Sharma, Hussain K. Al Omar, and Mickhael Bang Langit	
74	Recurrent Patello-Femoral Dislocations Treated with Femoral Rotational Osteotomy and Supratubercle Tibial Osteotomy	485
	Simon Martel, Patrick Park, Oren Eisman, and Thierry Pauyo	
75	Single-Stage High Tibial Osteotomy and Anterior Cruciate Ligament Reconstruction	493
	Yousef Marwan and Paul A. Martineau	
76	Soft Tissue Release and External Fixation for Severe Posttraumatic Knee Stiffness	501
	Leonid N. Solomin, Saigidula Rokhoev, and Dmitriy Chugaev	
77	Treatment of Recurrent Patella Dislocation and Rotational Malalignment Syndrome with Acute Correction of the Bony Deformities	505
	Lee Donghoon	
Part IX	Adult Deformity: Knee Fusion	511
78	Bilateral Congenital Knee Fusions with Lower Limb Deformities and Coxa Vara Treated with Osteotomies	513
	Marie Gdalevitch	
79	Correction of Varus Deformity of the Femur in a Patient with Knee Fusion	519
	Leonid N. Solomin and Petr Skomoroshko	
80	Knee Arthrodesis for Failed Total Knee Arthroplasty	525
	Megan M. Riedel and Janet D. Conway	
81	Knee Fusion and Lengthening for Failed Total Knee Replacement and Bone Loss	531
	Vikrant Landge and Janet D. Conway	
82	Knee Fusion with Gradual Shortening and Staged Insertion of Antibiotic Coated Intramedullary Nail for Failed Infected Total Knee Arthroplasty	535
	Amgad M. Haleem and S. Robert Rozbruch	
83	Cable Transport over Intramedullary Nail for Massive Femoral Bone Defect for Knee Arthrodesis	541
	Stephen J. Wallace and Austin T. Fragomen	

84 Large Knee Joint Bone Defect Substitution with Hex-Based and Cable Techniques	547
Konstantin L. Korchagin, Fanil Sabirov, Elena Shchepkina, and Leonid N. Solomin	
Part X Adult Deformity: Bone Defect	553
85 Acute Shortening and Re-lengthening to Bridge Bone Defects	555
Mahmoud A. El-Rosasy	
86 Bifocal Staged Bone Transport of a 30 cm Defect Including the Knee Joint	561
Leonid N. Solomin, Elena Shchepkina, Pavel Kulesh, and Konstantin L. Korchagin	
87 Cable Technique with a Medial Monorail for Bone Transport and Extended Soft Tissue Access for Reconstruction of More Than 16 cm of Tibial Bone	567
Peter Helmut Thaller and Julian Fuermetz	
88 Deformity Correction (Tibial Bone Defect due to Osteomyelitis) in Lower Limb Using Taylor Spatial Frame	573
Hiroyuki Tsuchiya	
89 Motorized Intramedullary Transport and Lengthening Nail Used to Reconstruct a Nonunion/Bone Defect of the Tibia	579
Søren Kold	
90 Biological Dead Space Management of Osteomyelitis: Debridement and Insertion of the Free Muscle Flap Inside the Debrided Cavity to Provide Biological, Live Dead Space Management and Antibiotic Delivery	585
Hemant K. Sharma, Mickhael Bang Langit, and Hussain K. Al Omar	
91 Chronic Osteomyelitis: Curettage, Filling with Antibiotics-Impregnated Artificial Bone Substitute and Internal Fixation	591
Hiroyuki Tsuchiya	
92 Infected 60 mm Subtrochanteric Bone Defect in Fibrous Dysplasia Lesion	597
Khaled Abu Dalu, Yousef Marwan, Neil Saran, and Mitchell Bernstein	
Part XI Adult Deformity: Amputation Reconstruction	605
93 An Initially Successful Lengthening of a Traumatic Below Knee Amputation Stump by Ilizarov Technique with Subsequent Failure Due to Soft Tissue Conditions	607
Peter M. van Roermund	
94 Below Knee Amputation Stump Lengthening	613
Prism S. Schneider and Mark R. Brinker	
95 Femoral Stump (Residual Limb) Lengthening with a Motorized Intramedullary Lengthening Rod	619
Søren Kold	
96 Lengthening of a Very Short Below Knee Amputation Residual Limb to Enhance Prosthetic Wear	625
S. Robert Rozbruch	

97	Post-traumatic Short Femoral Stump Lengthened with a Monolateral External Fixator	631
	Pablo Wagner, Renee Hunter, and John E. Herzenberg	
98	Freedom Nail Lengthening Followed by Press-Fit Osseointegration for the Transfemoral Amputee with Very Short Residual Bone	635
	Mustafa Alttahir, Jason S. Hoellwarth, Kevin Tetsworth, and Munjed Al Muderis	
99	Press-Fit Osseointegration for the Pelvic Disarticulation Amputee	641
	Qutaiba Al-Maawi, Jason S. Hoellwarth, Kevin Tetsworth, and Munjed Al Muderis	
100	Press-Fit Osseointegration for the Transfemoral Amputee	647
	Claudia Roberts, Jason S. Hoellwarth, Kevin Tetsworth, and Munjed Al Muderis	
101	Press-fit Osseointegration for the Transtibial Amputee	653
	Claudia Roberts, Jason S. Hoellwarth, Kevin Tetsworth, and Munjed Al Muderis	
102	Simultaneous Transfemoral Amputation and Press-Fit Osseointegration for the Patient with Severe Complex Regional Pain Syndrome	659
	Jason S. Hoellwarth, Kevin Tetsworth, and Munjed Al Muderis	
103	Femoral Osseointegration in a Transfemoral Amputee After Lengthening of Her Short Femoral Stump	663
	Maroun Rizkallah, Natalie Habra, Panagiotis (Peter) Glavas, and Robert Turcotte	
104	Osseointegration Amputation Reconstruction Extremely Short Femur	671
	Adam D. Geffner, Taylor J. Reif, and S. Robert Rozbruch	
105	Osseointegration Amputation Reconstruction Femur	677
	Adam D. Geffner, Taylor J. Reif, and S. Robert Rozbruch	
106	Reconstruction of an Extremely Short Transtibial Amputee with Osseointegration Prosthesis	683
	Taylor J. Reif and S. Robert Rozbruch	
107	Below Knee Amputation Reconstruction with Osseointegration Prosthesis for Chronic Pain and Deformity	689
	Taylor J. Reif and S. Robert Rozbruch	
 Volume 2		
Part XII	Tumor	695
108	Tumor: Introduction	697
	Taylor J. Reif	
Part XIII	Tumor: Benign Bone Tumor	699
109	Correction of Long Bone Deformities due to Ollier's Disease with Ilizarov Method	701
	Levent Eralp and Ilker Eren	

110	Deformity Correction (Benign Bone Tumor) in Lower Limb Using Taylor Spatial Frame	707
	Hiroyuki Tsuchiya	
111	Femoral Neck Aneurysmal Bone Cyst Treated with Articulated Distraction and Grafting	715
	Levent Eralp and Ilker Eren	
112	Tibio-Talar Fusion to Treat Bone Defect and Ankle Arthritis Following Treatment of a Distal Tibial Giant Cell Tumour	721
	Peter Calder	
113	Benign Tumor 1: Decompression and Cannulation for Simple Bone Cyst	729
	Hiroyuki Tsuchiya	
114	Benign Tumor 2: Reconstruction with Artificial Bone Substitute for Giant Cell Tumor	735
	Hiroyuki Tsuchiya and Akihiko Takeuchi	
115	Correction of Fibrous Dysplasia Induced Femoral Deformity with Intramedullary Nail	741
	Taylor J. Reif and S. Robert Rozbruch	
116	Leg Length Discrepancy Combined with Shepherd's Crook Deformity in Polyostotic Fibrous Dysplasia	747
	Lee Donghoon	
117	Management of Deformities After Treatment of Simple Bone Cyst	755
	Gamal Ahmed Hosny	
118	Talofibular Fusion and Lengthening to Reconstruct a Failed Distal Tibia Allograft Defect After Osteosarcoma Resection	761
	Erik J. Geiger and S. Robert Rozbruch	
119	Two-Stage Femoral Deformity Correction and Lengthening with Intramedullary Magnetic Nail in the Setting of Multiple Enchondromatosis	771
	Melih Civan, Buğra Alpan, Harzem Özger, and Levent Eralp	
Part XIV	Tumor: Malignant Bone Tumor	781
120	Combined Technique for Simultaneous Reconstruction of Ankle Instability and Tibial Lengthening Following Sacrifice of the Sciatic Nerve	783
	Levent Eralp and Ilker Eren	
121	Distraction Epiphysiolysis Prior to Resection of a Malignant Bone Tumor (Osteosarcoma)	789
	Levent Eralp and Ilker Eren	
122	Pathologic Femur Fracture Close to Distal Femoral Physis	795
	Christopher Iobst	
123	Distal Tibia-Ankle Reconstruction with Bone Transport Fusion After Resection of Osteosarcoma	799
	Erik J. Geiger, Taylor J. Reif, and S. Robert Rozbruch	

124	Femoral Lengthening with Intramedullary Magnetic Nail in the Setting of “Frozen Hotdog” Biological Reconstruction After Distal Femur Osteosarcoma Resection	809
	Melih Civan, Buğra Alpan, Harzem Özger, and Levent Eralp	
125	Joint Preserving Peri-articular Reconstruction of Distal Femur After High-Grade Tumor Resection	817
	Daniel Eduardo Prince and Maksim Vaynrub	
126	Joint Preserving Peri-articular Reconstruction of Distal Tibia After High-Grade Tumor Resection	829
	Daniel Eduardo Prince	
127	Joint Preserving Peri-articular Reconstruction of Proximal Tibia After High-Grade Tumor Resection	839
	Daniel Eduardo Prince	
128	Joint Preserving Periarticular Reconstruction of Proximal Femur After High-Grade Tumor Resection	849
	Prince Daniel Eduardo	
129	Joint Preserving Tibial Shaft Trifocal Reconstruction with Balanced Cable Bone Transport After Tumor Resection	859
	Molly Friel Klima and Daniel Eduardo Prince	
130	Malignant Tumor 1: Frozen Autograft-Prosthesis Composite for Proximal Tibia	867
	Hiroyuki Tsuchiya and Akihiko Takeuchi	
131	Malignant Tumor 2: Reconstruction of Proximal Humerus with Frozen Autograft	875
	Hiroyuki Tsuchiya and Akihiko Takeuchi	
Part XV	Tumor: Failed Initial Treatment	881
132	Failed Allograft Reconstruction (Nonunion) for Malignant Bone	883
	Austin T. Fragomen	
133	Oncologic Defects: Reconstruction Following Initial Treatment Failure	889
	George Cierny III	
134	Reconstruction of Failed Allograft Reconstruction with Combined Technique (Low-Grade Osteosarcoma)	895
	Mehmet Kocaoglu and F. Erkal Bilen	
135	Repair and Lengthening After Nonunion of Free Vascularized Fibula Graft for Reconstruction of Osteosarcoma of the Tibia	901
	S. Robert Rozbruch	
136	Staged Reconstruction of a Failed Modular Knee Tumor Prosthesis	909
	Levent Eralp and Ilker Eren	
137	Failed Proximal Tibia Allograft: Limb Salvage with Trifocal Tandem Transport	919
	Erik J. Geiger, Taylor J. Reif, and S. Robert Rozbruch	
138	Post Oncologic Allograft Femur Nonunion Treated with Staged Compression Nailing and Simultaneous Femur and Tibial Lengthening	927
	Taylor J. Reif, Kayla M. Jaime, and Austin T. Fragomen	

Part XVI Tumor: Sequela of Resection	933
139 Reconstruction of a 22 cm Femur Bone Defect with Transport Over Nail and Cable Technique	935
Mitchell Bernstein and S. Robert Rozbruch	
140 Reconstruction of a Bone Defect (Malignant Bone Tumor) in the Proximal Tibia Using a Frozen Autograft	943
Hiroyuki Tsuchiya	
141 Reconstruction of a Bone Defect (Malignant Bone Tumor) in the Proximal Tibia Using Taylor Spatial Frame (Distraction Osteogenesis)	953
Hiroyuki Tsuchiya	
142 Reconstruction of a Bone Defect (Malignant Bone Tumor) in the Diaphyseal Tibia Using Circular External Fixator with Trifocal Bone Transport (Distraction Osteogenesis)	961
Levent Eralp and Ilker Eren	
143 Reconstruction of a Bone Defect (Malignant Bone Tumor) in the Proximal Humerus Using Vascularized Fibular Grafting	967
Hiroyuki Tsuchiya	
144 Reconstruction of a Bone Defect (Malignant Bone Tumor) in the Proximal Tibia Using a Hemicortical Frozen Autograft	977
Hiroyuki Tsuchiya	
145 Reconstruction of a Bone Defect, Following Resection of Chondrosarcoma in the Distal Forearm by Segment Transport Over Nail Technique Using Uniplanar Fixator	987
Levent Eralp and Ilker Eren	
146 Acute Deformity Correction and Limb-Lengthening After Allograft Reconstruction for Sarcoma	993
Lee M. Zuckerman	
147 All Internal Limb-Lengthening After Hemipelvectomy for Sarcoma Resection	1003
Lee M. Zuckerman	
148 Delayed Limb-Lengthening with a “Sleeper Nail” After Sarcoma Resection	1009
Lee M. Zuckerman	
149 Distal Femur Prosthetic Revision Aided by Soft Tissue Distraction and Titanium Mesh Cage Defect Reconstruction Followed by Tibial Lengthening	1019
Melih Civan, Ahmet Salduz, Harzem Özger, and Levent Eralp	
150 Multiple Femoral and Tibial Lengthening with External Fixator and Intramedullary Magnetic Nail in the Setting of Distal Femur Resection Prosthesis	1027
Melih Civan, Harzem Özger, and Levent Eralp	
151 Reconstruction of the Femur with Allograft After Sarcoma Resection and Subsequent Limb-Lengthening	1035
Lee M. Zuckerman	

Part XVII Upper Extremity	1043
152 Upper Extremity: An Introduction	1045
John E. Herzenberg	
Part XVIII Upper Limb: Humerus	1047
153 Adolescent with 15 cm Humeral Shortening from Osteomyelitis Treated by Humeral Lengthening via Circular External Fixation	1049
John Birch, Alexander Cherkashin, and Mikhail Samchukov	
154 Deformity of the Humerus in a 4-Year-Old Boy with Osteogenesis Imperfecta	1057
Elizabeth Ashby, Reggie C. Hamdy, and François Fassier	
155 Humeral Deformity Secondary to Ollier Disease – Angular Correction and Lengthening with a Taylor Spatial Frame	1061
Daniel Ruggles, Pablo Wagner, and John E. Herzenberg	
156 Humeral Lengthening and Deformity Correction in Ollier’s Disease: Distraction Osteogenesis with a Multiaxial Correction Frame	1067
S. Robert Rozbruch	
157 Humeral Lengthening for Septic Growth Arrest	1073
Pablo Wagner, Daniel Ruggles, and John E. Herzenberg	
158 Humeral Lengthening in Erb’s Palsy	1079
Gamal Ahmed Hosny	
159 Humeral Lengthening with a Motorized Intramedullary Lengthening Nail	1085
Søren Kold	
160 Varus and Shortening of the Proximal Humerus	1091
Hae-Ryong Song and Kwang-Won Park	
161 Humeral Lengthening Rotational Correction with Hexapod Frame for Osteomyelitis	1099
Doron Keshet and Mitchell Bernstein	
162 Humerus Lengthening with an Internal Lengthening Nail	1107
Adam D. Geffner, Sherif Galal, Taylor J. Reif, and S. Robert Rozbruch	
163 Distal Humeral Shaft Fracture in Osteogenesis Imperfecta Patient Fixed Initially with Elastic Nails, Converted to Slim Nail with a Supplemental Plate due to Non-union	1115
Khaled Abu Dalu, Yousef Marwan, and Chantal Janelle	
164 Principles of Rodding Upper Limb Deformity in Children with Osteogenesis Imperfecta	1119
Ishani P. Shah and James A. Fernandes	
Part XIX Upper Limb: Elbow and Forearm	1129
165 Correction of Forearm by Corrective Radial Osteotomy and Ulnar Lengthening by Distraction Osteogenesis Deformity in Hereditary Multiple Osteochondromatosis	1131
Levent Eralp and Ilker Eren	

166	Correction of Forearm Deformities in Hereditary Multiple Exostosis (MHE)	1139
	Mark Eidelman	
167	Cubitus Varus Deformity due to Multiple Hereditary Exostosis Treated with Ulnar Lengthening and Closed Radio-Capitulum Reduction	1145
	Aik Saw and Rukmanikanthan Shanmugam	
168	Forearm Deformity in a Fourteen-Year-Old Boy with Osteogenesis Imperfecta	1151
	Elizabeth Ashby, Reggie C. Hamdy, and François Fassier	
169	Multiple Hereditary Exostoses: Forearm Deformities	1155
	Dror Paley and Craig A. Robbins	
170	Forearm Correction and Differential Ulnar Lengthening Using Frame Within a Frame	1165
	Jason S. Hoellwarth and S. Robert Rozbruch	
171	Forearm Rotational Osteotomies Using 3D Planning and Guides in a Young Adult with Arthrogyposis	1171
	David B. Frumberg, Christopher V. Wilhelm, and Michael Amick	
172	Treatment of Forearm Malunion Using 3D Printed Osteotomy and Plating Guides	1179
	Raymond W. Liu	
173	Use of a Hexapod Frame for Correction of Congenital Elbow Flexion Deformity	1187
	Viktor Vilenskiy, Maxim Baushev, Dmitrii Gavrilov, and Leonid N. Solomin	
174	Reconstruction of Radius Bone Defect in a 10-Year-Old Girl with Neurofibromatosis Type I Using Association of Autograft, Elastic HA-Coated Nail, and External Fixation	1191
	Dmitry A. Popkov and Pierre Lascombes	
175	TAR Syndrome	1197
	Gamal Ahmed Hosny	
176	Correction of Cubitus Varus Using Hexapod	1201
	Mark Eidelman and Nadav Rinott	
Part XX	Upper Limb: Hand and Wrist	1207
177	Bilateral Metacarpal Lengthening for Congenital Brachymetcarpia	1209
	S. Robert Rozbruch	
178	Congenital Malformation of the Upper Limb (Ulnar Clubhand) in a 6 Year Old Child Treated by Lengthening Associated with Flexible Intramedullary Nailing	1217
	Dmitry A. Popkov, Arnold V. Popkov, and Pierre Lascombes	
179	Radial Clubhand	1223
	Muayad Kadhim and Richard S. Davidson	
180	Radial Clubhand Correction with Radius Lengthening Using the Ilizarov/TSF	1229
	S. Robert Rozbruch	

181	Ulnarization as Treatment for Radial Clubhand (RCH)	1235
	Dror Paley and Craig A. Robbins	
182	Salvage of a Failed Sauvé-Kapandji Procedure	1243
	Martin McNally and Peter Burge	
183	Severe Wrist Flexion Deformity in Arthrogyrosis Corrected by Carpal Closing Wedge Osteotomy	1249
	Khaled Abu Dalu, Doron Keshet, and Chantal Janelle	
Part XXI	Upper Limb: Trauma	1253
184	Fracture of the Humerus Treated Initially with a Flexible Intramedullary Nail and Later Converted to Circular External Fixation due to Non-union	1255
	Lane Wimberly, Alexander Cherkashin, and Mikhail Samchukov	
185	Humerus Nonunion Treated with Fixator Augmented Rod Technique	1263
	Mahmoud A. El-Rosasy	
186	Mangled Upper Extremity Salvaged with Spatial Frame, Skin Grafts, Radial Lengthening, and Wrist Fusion	1267
	Daniel Schlatterer	
187	Mangled Upper Extremity Salvaged with Spatial Frame, Skin Grafts, Wrist Fusion and Transfer of FCR to EDC	1273
	Daniel Schlatterer	
188	Reconstruction of the Elbow After Gunshot Injury with Dynamic Articulated Frame	1279
	León Gonzalo Mora Herrera	
189	Judet Osteoperiosteal Decortication for Humeral Nonunion	1287
	Hobie Summers	
190	Radial Shaft Chronic Osteomyelitis Treated with Resection, Radial Osteotomy, and Bone Transport Using a Monolateral Fixator	1291
	Ahmed H. Elhessy and Janet D. Conway	
Part XXII	Upper Limb: Amputation	1297
191	Arthrogyrosis Elbow Extension Contracture	1299
	Dan A. Zlotolow	
192	Press-Fit Osseointegration for the Transhumeral Amputee	1303
	William Yenn-Ru Lu, Jason S. Hoellwarth, Kevin Tetsworth, and Munjed Al Muderis	
193	Press-Fit Osseointegration for the Forearm Amputee	1309
	Warrick Heald, Jason S. Hoellwarth, Kevin Tetsworth, and Munjed Al Muderis	
194	Reconstruction of Transulnar Amputation with Osseointegration Prosthesis and Myoelectric Robotic Hand	1313
	Taylor J. Reif and S. Robert Rozbruch	
Index	1319

About the Editors



Dr. S. Robert Rozbruch is Chief of the Limb Lengthening and Complex Reconstruction Service and Director of the Osseointegration Limb Replacement Center at Hospital for Special Surgery. He is Professor of Clinical Orthopedic Surgery at Weill Cornell Medical College, and is a member of several national medical societies including fellowship in the American Academy of Orthopaedic Surgeons, Orthopaedic Trauma Association, and ASAMI—The Limb Lengthening & Reconstruction Society of which he was President (2012–2013). He has presented his clinical and research works at numerous national and international medical meetings and has authored over 200 articles in medical journals and chapters in orthopedic textbooks. He edited two authoritative textbooks on limb lengthening and reconstruction.

Dr. Rozbruch was educated at the University of Pennsylvania graduating Magna Cum Laude in 1985, and he attended Weill Cornell Medical College of Cornell University, from which he graduated with honors in research in 1990. Residency training at Hospital for Special Surgery in orthopedic surgery (1991–1995) was followed by two fellowships. He did specialized training in Trauma as an AO fellow at the University of Bern in Switzerland. Additional training in adult and pediatric limb lengthening followed at the Maryland Center for Limb Lengthening & Reconstruction.



Reggie C. Hamdy is a pediatric orthopedic surgeon, graduated from the University of Alexandria and completed his residency at the University of Ottawa, and his fellowship training at the Hospital for Sick Children, Toronto, and Brown University in Providence, Rhode Island. He joined the Shriners Hospitals for Children—Canada in 1994, and was appointed Chief of Staff and Head of Division of Paediatric Orthopaedics, McGill University in 2010 (till 2020). He was President of LLRS North America 2015. He is a tenured Professor of Surgery. He was appointed Associate Chair, Department of Paediatric Surgery (Continuous Professional Development), McGill University in 2024 and is currently the Medical Director of the Motion Analysis Laboratory, Director of the Limb Lengthening and Deformity Unit, Director of the Fellowship Training Program in Paediatric Orthopaedics, and Surgical Director of The Osteogenesis Imperfecta Program. His main clinical interests include the management of children with complex

conditions such as Osteogenesis Imperfecta (OI), skeletal dysplasias, neuromuscular conditions specifically arthrogyposis, and children with limb deformities. He is the Chairman of the Limb Reconstruction Committee of the SICOT 2024/2025. He has authored or co-authored over 160 peer review publications and 8 chapters, and he is the Editor of a book on *Pelvic and Femoral Osteotomies in Children* (Springer) and the Co-Editor of an *Atlas on Limb Lengthening and Reconstruction* (First Edition and the present Second Edition).



Dr. Austin T. Fragomen is Professor of Clinical Orthopedic Surgery at Weill Cornell Medical School and HSS. He has excelled as an educator. He is the director of the LLRS fellowship program which includes recruitment and year-long training of exceptional young surgeons interested in pursuing a career in the subspecialty of Limb Deformity. In addition, surgeons from various regions in the United States and from around the globe come to New York to rotate with Dr. Fragomen for month-long visiting-professor observer-ships to broaden how they approach complex orthopedic challenges. Feedback from these observers includes amazement with the volume of Limb Deformity patients treated in Dr. Fragomen's clinic and his ability to spend time with each person to ensure that the patient remains the focus of the practice.


With over 150 publications, research has been central to ensuring the highest quality patient care including surgical decision making and has given Dr. Fragomen a voice nationally and worldwide. Authoring textbook chapters requires not only a profound knowledge of the field of Limb Deformity but also demands meticulous scouring of publications, new and old, relevant to the topic, providing further information and perspective to the author. Dr. Fragomen maintains a prospective database of all the surgeries he has performed for use in later analysis to find trends in patient care. This data then drives future decision making to optimize surgery and post-operative protocols ensuring the best possible outcomes and patient satisfaction. Dr. Fragomen is invited to speak regularly at orthopedic programs around the United States, Canada, and abroad to share his research and personal experiences for the advancement of successful outcomes in these other centers. As the president of the national Limb Lengthening & Reconstruction Society (LLRS) from 2019 to 2021, Dr. Fragomen launched several initiatives that have inspired current members, drawn in new members, and gained traction at the American Academy of Orthopedic Surgeons (AAOS) where he also serves on the Board of Subspecialty Societies.

Dr. Fragomen takes pride in resolving the previously "unsolvable" problems from which his patients suffer, and he welcomes collaboration with other HSS surgeons who have complimentary skill sets in an effort to guarantee that all of his patients have been treated by the best of the best.



Mitchell Bernstein is Associate Professor of Surgery at McGill University in Montreal, Canada. He specializes in adult and pediatric trauma, limb lengthening, and deformity correction surgery. Dr. Bernstein serves as the Director of the Orthopaedic Residency Program, Head of the Orthopaedic Trauma Unit at the Montreal Children's Hospital, and Co-Director of the Limb Deformity Unit at Shriners Hospital for Children—Canada.

Section Editors



Jason Hoellwarth
Director of Research
Limb Lengthening and Complex Reconstruction Service
Hospital for Special Surgery
New York, NY, USA

Weill Cornell Medical College
Cornell University
New York, NY, USA



Taylor J. Reif
Director of Education
Limb Lengthening and Complex Reconstruction Service
Hospital for Special Surgery
New York, NY, USA

Weill Cornell Medical College
Cornell University
New York, NY, USA

Contributors

Khaled Abu Dalu Shriners Hospital for Children, Montreal, QC, Canada
McGill University Health Centre, McGill University, Montreal, QC, Canada

Qutaiba Al-Maawi Ibn Sina Training Hospital, Baghdad, Iraq

Buğra Alpan Department of Orthopaedics and Traumatology, Acıbadem Maslak Hospital, Acıbadem University, Istanbul, Turkey

Mustafa Alttahir Limb Reconstruction Centre, Macquarie University Hospital, Sydney, NSW, Australia

Michael Amick Department of Orthopaedics & Rehabilitation, Yale School of Medicine, New Haven, CT, USA

Elizabeth Ashby Shriners Hospital, Division of Paediatric Orthopaedics, McGill University, Montreal, QC, Canada

Maxim Baushev Saint-Petersburg State University Hospital Institute, St. Petersburg, Russia

Mitchell Bernstein Departments of Surgery & Pediatric Surgery (Division of Orthopaedics), McGill University Health Center & Shriners Hospital for Children - Canada, Maywood, IL, USA

F. Erkal Bilen Faculty of Health Sciences, Istanbul Yeniüzyıl Üniversitesi, Istanbul, Turkey

John Birch Center for Excellence in Limb Lengthening and Reconstruction, Texas Scottish Rite Hospital for Children, Dallas, TX, USA

Mark R. Brinker Acute and Reconstructive Trauma, Fondren Orthopaedic Group, Texas Orthopaedic Hospital, Houston, TX, USA

Peter Burge Hand Surgery Unit, Nuffield Orthopaedic Centre, Oxford University Hospitals, Oxford, UK

Peter Calder Royal National Orthopaedic Hospital (RNOH), Stanmore, London, UK

Alexander Cherkashin Center for Excellence in Limb Lengthening and Reconstruction, Texas Scottish Rite Hospital for Children, Dallas, TX, USA

Dmitriy Chugaev Vreden National Research Orthopaedic Centre, St. Petersburg, Russia

George Cierny III San Diego, CA, USA

Melih Civan Department of Orthopedics and Traumatology, Başakşehir Çam ve Sakura City Hospital, Istanbul, Turkey

Janet D. Conway International Center for Limb Lengthening, Rubin Institute for Advanced Orthopedics, Sinai Hospital of Baltimore, Baltimore, MD, USA

Richard S. Davidson Department of Orthopaedics, Children's Hospital of Philadelphia, School of Medicine, Hospital of the University of Pennsylvania, Philadelphia, PA, USA

Constantin Edmond Dlaska Department of Orthopaedic Surgery, Royal Brisbane and Women's Hospital, Brisbane, QLD, Australia

Lee Donghoon Donghoon Advanced Lengthening Reconstruction Institute (DALRI), Gyeonggi-do, South Korea

Prince Daniel Eduardo Memorial Sloan Kettering Cancer Center, New York, USA

Mark Eidelman Ruth Rappoport Children's Hospital, Rambam Healthcare Campus, Haifa, Israel

Technion Faculty of Medicine, Rambam Health Care Campus, Meyer's Children Hospital, Haifa, Israel

Oren Eisman Division of Orthopaedic Surgery, Shriners Hospitals for Children, Montreal, Canada

Ahmed H. Elhessy International Center for Limb Lengthening, Rubin Institute for Advanced Orthopedics, Sinai Hospital of Baltimore, Baltimore, MD, USA

Mahmoud A. El-Rosasy Faculty of Medicine, Department of Orthopaedic Surgery, University of Tanta, Tanta, Al-Gharbeya, Egypt

Levent Eralp Orthopaedics and Traumatology Department, Istanbul Faculty of Medicine, Istanbul University, Istanbul, Turkey

Ilker Eren Orthopaedics and Traumatology Department, Koç University School of Medicine, Istanbul, Turkey

François Fassier Shriners Hospital and Montreal Children Hospital, Division of Paediatric Orthopaedics, McGill University, Montreal, QC, Canada

Austin T. Fragomen Department of Orthopedic Surgery, Hospital for Special Surgery, New York, NY, USA

Felix Frankenberg 3D-Surgery, Department of General, Trauma, Hand and Plastic Surgery, Ludwig-Maximilians-University (LMU), Munich, Germany

David B. Frumberg Department of Orthopaedics & Rehabilitation, Yale School of Medicine, New Haven, CT, USA

Julian Fuermetz 3D-Surgery, Department of General, Trauma, Hand and Plastic Surgery, Ludwig-Maximilians-University (LMU), Campus Innenstadt, Munich, Germany

Sherif Galal Department of Orthopaedic Surgery, Faculty of Medicine, Cairo University, Cairo, Egypt

Dmitrii Gavrilov Saint-Petersburg State University, St. Petersburg, Russia

Marie Gdalevitch Shriners Hospital for Children, Canada, Montreal, QC, Canada

Adam D. Geffner Limb Lengthening and Complex Reconstruction Service, Hospital for Special Surgery, New York, NY, USA

Erik J. Geiger University of Miami, Miami, FL, USA

Panagiotis (Peter) Glavas Division of Orthopedic Surgery, University of Montreal, CHU Sainte-Justine, Montreal, QC, Canada

Abdullah Gogus Istanbul Florence Nightingale Hospital, Istanbul, Turkey

Evgenii Golovenkin Vreden National Medical Research Center of Traumatology and Orthopedics, St. Petersburg, Russia

Natalie Habra Rehabilitation Medicine Department, University of Montreal, Institut de Réadaptation Gingras-Lindsay de Montréal, Montreal, QC, Canada

Amgad M. Haleem Limb Lengthening and Complex Reconstruction Service, Hospital for Special Surgery, New York, NY, USA

Reggie C. Hamdy Department of Pediatric Surgery, Shriners Hospital - Canada, Montreal, QC, Canada

Amber A. Hamilton Hospital for Special Surgery, New York, NY, USA

Paul Harwood Major Trauma Centre, Leeds Teaching Hospitals, Academic Department of Trauma & Orthopaedic Surgery, University of Leeds, Leeds, UK

Warrick Heald Limb Reconstruction Centre, Macquarie University Hospital, Macquarie University, Macquarie Park, NSW, Australia

Tobias Helfen 3D-Surgery, Department of General, Trauma, Hand and Plastic Surgery, Ludwig-Maximilians-University (LMU), Campus Innenstadt, Munich, Germany

John E. Herzenberg Rubin Institute for Advanced Orthopedics, International Center for Limb Lengthening and Reconstruction, Sinai Hospital of Baltimore, Baltimore, MD, USA

Jason S. Hoellwarth Department of Orthopaedic Surgery, Osseointegration Limb Replacement Center, Limb Lengthening and Complex Reconstruction Service, Hospital for Special Surgery, New York, NY, USA

Gamal Ahmed Hosny Benha Faculty of Medicine, Benha, Cairo, Egypt
Benha University Hospitals, Banha, Egypt

Renee Hunter Rubin Institute for Advanced Orthopedics, International Center for Limb Lengthening and Reconstruction, Sinai Hospital of Baltimore, Baltimore, MD, USA

Christopher Iobst Department of Orthopedic Surgery, Nemours Children's Hospital, Orlando, FL, USA

Danya M. Jacobs Hospital for Special Surgery, New York, NY, USA

Kayla M. Jaime Hospital for Special Surgery, New York, NY, USA

Chantal Janelle Shriners Hospital for Children, Montreal, QC, Canada
McGill University Health Centre, McGill University, Montreal, QC, Canada

Burkley Jensen Rubin Institute for Advanced Orthopedics, International Center for Limb Lengthening and Reconstruction, Sinai Hospital of Baltimore, Baltimore, MD, USA

Muayad Kadhim Children's Hospital of Philadelphia, University of Pennsylvania, Philadelphia, PA, USA

Ozgur Karakoyun Department of Orthopaedics and Traumatology, Medical Faculty, Namik Kemal University, Tekirdag, Turkey

Lori Karol Texas Scottish Rite Hospital for Children, Dallas, TX, USA

Stephen Kent University of Queensland, Brisbane, QLD, Australia

Doron Keshet Pediatric Orthopedic Unit, Ruth Rappaport Children's Hospital, Haifa, Israel

Molly Friel Klima Memorial Sloan Kettering Cancer Center, New York, NY, USA

Mehmet Kocaoglu Faculty of Health Sciences, Istanbul Yeniüzyıl Üniversitesi, Istanbul, Turkey

- Søren Kold** Department of Orthopaedics, Aalborg University Hospital, Aalborg, Denmark
- Konstantin L. Korchagin** Vreden Russian Research Institute of Traumatology and Orthopedics, St. Petersburg State University, St. Petersburg, Russia
- Metin Kucukkaya** Istanbul Florence Nightingale Hospital, Istanbul, Turkey
- Pavel Kulesh** Vreden Russian Research Institute of Traumatology and Orthopedics, St. Petersburg, Russia
- Vikrant Landge** International Center for Limb Lengthening, Rubin Institute for Advanced Orthopedics, Sinai Hospital of Baltimore, Baltimore, MD, USA
- Mickhael Bang Langit** Hull Limb Reconstruction and Bone Infection Unit, Hull University Teaching Hospitals, Hull, UK
- Pierre Lascombes** Division of Pediatric Orthopaedics, University of Geneva, Geneva, Switzerland
University of Nancy, Nancy, France
- Sergei Lasunsky** Vreden National Medical Research Center of Traumatology and Orthopedics, St. Petersburg, Russia
- Dong Hoon Lee** Limb Lengthening and Deformity Reconstruction Service, Department of Orthopedic Surgery, Severance Children's Hospital, College of Medicine, Yonsei University, Seoul, Seodaemun-gu, South Korea
- Raymond W. Liu** Case Western Reserve School of Medicine, Rainbow Babies and Children's Hospital, Cleveland, OH, USA
- William Yenn-Ru Lu** Limb Reconstruction Centre, Macquarie University Hospital, Macquarie University, Macquarie Park, NSW, Australia
- Marina Makarov** Center for Excellence in Limb Lengthening and Reconstruction, Texas Scottish Rite Hospital for Children, Dallas, TX, USA
- Simon Martel** Division of Orthopaedic Surgery, Shriners Hospitals for Children, Montreal, Canada
- Paul A. Martineau** McGill University Health Centre, McGill University, Montreal, QC, Canada
- Yousef Marwan** Department of Surgery, College of Medicine, Health Sciences Centre, Kuwait University, Kuwait City, Kuwait
Shriners Hospital for Children, Montreal, QC, Canada
McGill University Health Centre, McGill University, Montreal, QC, Canada
- Martin McNally** The Limb Reconstruction Unit, Nuffield Orthopaedic Centre, Oxford University Hospitals, Oxford, UK
- Tamer Mettyas** Royal Brisbane & Women's Hospital, Brisbane, QLD, Australia
- León Gonzalo Mora Herrera** Clínica de Alargamientos Óseos y Reconstrucción de Extremidades, Medellín, Colombia
- Munjed Al Muderis** Limb Reconstruction Centre, Macquarie University Hospital, Macquarie University, Macquarie Park, NSW, Australia
- Hussain K. Al Omar** Hull Limb Reconstruction and Bone Infection Unit, Hull University Teaching Hospitals, Hull, UK

Harzem Özger Department of Orthopedics and Traumatology, Istanbul University, Istanbul, Turkey

Dror Paley Paley Advanced Limb Lengthening Institute, St. Mary's Medical Center, West Palm Beach, FL, USA

Kwang-Won Park Department of Orthopedic Surgery, Guro Hospital, Korea University Medical Center, Seoul, South Korea

Patrick Park Division of Orthopaedic Surgery, Shriners Hospitals for Children, Montreal, Canada

Thierry Pauyo Division of Orthopaedic Surgery, Shriners Hospitals for Children, Montreal, Canada

Arnold V. Popkov Russian Ilizarov Scientific Center for Restorative Traumatology and Orthopaedics, Kurgan, Russia

Dmitry A. Popkov National Ilizarov Medical Research Center for Traumatology and Orthopaedics, Kurgan, Russia

Russian Ilizarov Scientific Center for Restorative Traumatology and Orthopaedics, Kurgan, Russia

Daniel Eduardo Prince Memorial Sloan Kettering Cancer Center, New York, NY, USA

Taylor J. Reif Director of Education, Limb Lengthening and Complex Reconstruction Service, Hospital for Special Surgery, New York, NY, USA

Weill Cornell Medical College, Cornell University, New York, NY, USA

Megan M. Riedel International Center for Limb Lengthening, Rubin Institute for Advanced Orthopedics, Sinai Hospital of Baltimore, Baltimore, MD, USA

Nadav Rinott Ruth Children's Hospital, Rambam Health Care Campus, Haifa, Israel

Maroun Rizkallah Division of Orthopedic Surgery, McGill University Health Centre, Montreal, QC, Canada

Craig A. Robbins Paley Advanced Limb Lengthening Institute, St. Mary's Medical Center, West Palm Beach, FL, USA

S. Robert Rozbruch Department of Orthopedic Surgery, Hospital for Special Surgery, New York, NY, USA

Claudia Roberts Limb Reconstruction Centre, Macquarie University Hospital, Macquarie University, Macquarie, NSW, Australia

Saigidula Rokhoev Vreden National Research Orthopaedic Centre, St. Petersburg, Russia

Daniel Ruggles International Center for Limb Lengthening, Rubin Institute for Advanced Orthopedics, Sinai Hospital of Baltimore, Baltimore, MD, USA

Fanil Sabirov Vreden Russian Research Institute of Traumatology and Orthopedics, St. Petersburg, Russia

Vreden National Medical Research Center of Traumatology and Orthopedics, St. Petersburg, Russia

Ahmet Salduz Department of Orthopedics and Traumatology, Istanbul University, Istanbul, Turkey

Mikhail Samchukov Center for Excellence in Limb Lengthening and Reconstruction, Texas Scottish Rite Hospital for Children, Dallas, TX, USA

- Neil Saran** Shriners Hospital for Children, Montreal, QC, Canada
McGill University Health Centre, McGill University, Montreal, QC, Canada
- Aik Saw** Department of Orthopaedic Surgery, University Malaya Medical Centre, Kuala Lumpur, Malaysia
- Daniel Schlatterer** Orthopaedic Trauma, Atlanta Medical Center, Atlanta, GA, USA
- Prism S. Schneider** Orthopaedic Trauma Service, The University of Texas Medical School at Houston, Houston, TX, USA
- John A. Scolaro** Department of Orthopaedic Surgery, University of California, Irvine, Orange, CA, USA
- Ishani P. Shah** Department of Trauma and Paediatric Orthopaedics, Manchester University NHS Foundation Trust, Manchester, UK
- Rukmanikanthan Shanmugam** Department of Orthopaedic Surgery, University Malaya Medical Centre, Kuala Lumpur, Malaysia
- Hemant K. Sharma** Hull University Teaching Hospitals, Hull York Medical School, University of Hull, Hull, UK
Hull Limb reconstruction and Bone infection Unit, Hull, UK
- Elena Shchepkina** Vreden National Medical Research Center of Traumatology and Orthopedics, St. Petersburg, Russia
Pavlov First St. Petersburg State Medical University, St. Petersburg, Russia
- Petr Skomoroshko** Vreden Russian Research Institute of Traumatology and Orthopedics, St. Petersburg State University, St. Petersburg, Russia
- Sami Sokucu** Baltalimanı Bone Diseases Education and Training Hospital Istanbul, Istanbul, Turkey
- Leonid N. Solomin** Vreden Russian Research Institute of Traumatology and Orthopedics, St. Petersburg State University, St. Petersburg, Russia
- Hae-Ryong Song** Department of Orthopedic Surgery, Guro Hospital, Korea University Medical Center, Seoul, South Korea
- Hobie Summers** Loyola University Medical Center, Maywood, IL, USA
- Akihiko Takeuchi** Department of Orthopaedic Surgery, Graduate School of Medical Science Kanazawa University, Kanazawa, Ishikawa, Japan
- Kevin Tetsworth** Department of Orthopaedic Surgery, Royal Brisbane and Women's Hospital, Brisbane, QLD, Australia
- Peter Helmut Thaller** 3D-Surgery, Department of General, Trauma, Hand and Plastic Surgery, Ludwig-Maximilians-University (LMU), Campus Innenstadt, Munich, Germany
- Hiroyuki Tsuchiya** Department of Orthopaedic Surgery, Graduate School of Medical Sciences, Kanazawa University, Kanazawa, Ishikawa, Japan
- Robert Turcotte** Division of Orthopedic Surgery, McGill University Health Centre, Montreal, QC, Canada
- Peter M. van Roermund** University Medical Center Utrecht, Utrecht, The Netherlands
- Maksim Vaynrub** Memorial Sloan Kettering Cancer Center, New York, NY, USA

- Viktor Vilenskiy** Saint-Petersburg State University Hospital Institute, St. Petersburg, Russia
Vreden Russian Research Institute of Traumatology and Orthopedics, St. Petersburg, Russia
- Pablo Wagner** Rubin Institute for Advanced Orthopedics, International Center for Limb Lengthening and Reconstruction, Sinai Hospital of Baltimore, Baltimore, MD, USA
- Matthew Wagoner** Rubin Institute for Advanced Orthopedics, International Center for Limb Lengthening and Reconstruction, Sinai Hospital of Baltimore, Baltimore, MD, USA
- Stephen J. Wallace** Summit Orthopaedics, Lake Oswego, OR, USA
- Patrick Weinrauch** Brisbane Hip Clinic, Brisbane, QLD, Australia
- Christopher V. Wilhelm** Department of Orthopaedics & Rehabilitation, Yale School of Medicine, New Haven, CT, USA
- Lane Wimberly** Center for Excellence in Limb Lengthening and Reconstruction, Texas Scottish Rite Hospital for Children, Dallas, TX, USA
- Florian Wolf** 3D-Surgery, Department of General, Trauma, Hand and Plastic Surgery, Ludwig-Maximilians-University (LMU), Campus Innenstadt, Munich, Germany
- Dan A. Zlotolow** Shriners Hospital for Children, Hand & Upper Extremity Surgeon, Temple University School of Medicine, Philadelphia, PA, USA
- Lee M. Zuckerman** University of Southern California Keck School of Medicine, Los Angeles, CA, USA

Principles of Deformity Correction

Reggie C. Hamdy¹ and S. Robert Rozbruch²

¹Department of Pediatric Surgery, Shriners Hospital - Canada, Montreal, QC, Canada

²Department of Orthopedic Surgery, Hospital for Special Surgery, New York, NY, USA

Patients with lower limb deformities constitute a large proportion of referrals to both pediatric and adult orthopedic clinics. A practical approach to assessing and treating lower limb deformities should include four distinct steps. **First**, know what is normal: determine if there a deformity or if it is part of the normal development of the child. **Second**, define the characteristics of this deformity (type, site, plane, and magnitude). **Third**, decide if the deformity needs to be treated (depending on the clinical picture). **Fourth**, generate a treatment plan. In this atlas, more than 300 cases of lower and upper limb deformities of various etiologies are presented. A detailed analysis of these deformities is a prerequisite for appropriate planning of surgical correction. This chapter presents a practical approach to the assessment of lower limb deformities.

When a skeletally immature patient presents with a lower limb deformity, the first priority is to rule out **physiological** “deformity.” Almost all newborn babies have a symmetrical angular genu varum deformity of the legs that changes to a genu valgum deformity around 18–24 months of age. This partially corrects, gradually, until the age of 7–8 years old, when the adult anatomic valgum value of 7° is reached (Fig. 1). Similarly, the vast majority of rotational deformities in children (in-toeing and out-toeing) is physiological and usually corrects with age. However, in some patients, these deformities are not physiological but secondary to **pathological conditions** (congenital or acquired) and should be fully investigated.

History taking. The presenting symptoms should be clearly identified: what is the reason for the consultation? Is this a cosmetic or functional problem? What are the functional limitations this deformity inflicts on the patient? Is pain present? What are the characteristics of this pain (when did it start, is it acute or chronic, any associated symptoms, any systemic manifestations, what are the relieving and precipitating factors, localization, radiation of the pain, character of the pain)? Are daily activities affected? In certain conditions, such as skeletal dysplasias and metabolic disorders, other nonskeletal systems may be affected, and it is important to recognize these. The patient may have more than one deformity. It is imperative to identify which deformity (or deformities) is the cause of the symptoms. It is also imperative to determine the cause of the deformity as this may have an impact on the surgical planning. In skeletally immature patients, the deformity may be progressive. This is especially true for partial growth arrest deformities. In addition, the possibility of recurrence of the deformity after a successful correction has to be explained to the patient and family.

Physical examination is very important for the assessment of not only bony deformities but also other musculoskeletal pathologies such as joint contractures and soft tissue problems, including the condition of the skin and soft tissues surrounding the deformity. These factors will have an impact in the decision-making process regarding acute versus gradual correction and bony stabilization. A complete neurovascular assessment should be performed. More than one type of deformity may be present, including angular (in frontal, sagittal, or oblique planes), rotational, translational, axial (limb length discrepancy), or multiplanar deformity. The deformities could be unilateral or bilateral and may be associated with other musculoskeletal problems, as well as non- musculoskeletal problems. Physical examination is of specific

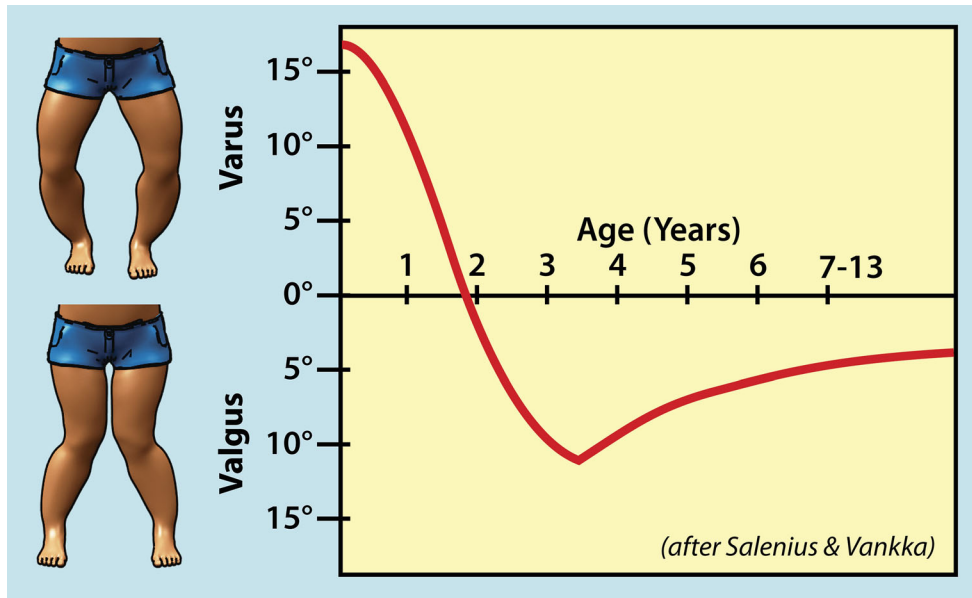


Fig. 1 Normal age limits for physiological genu varum and genu valgum

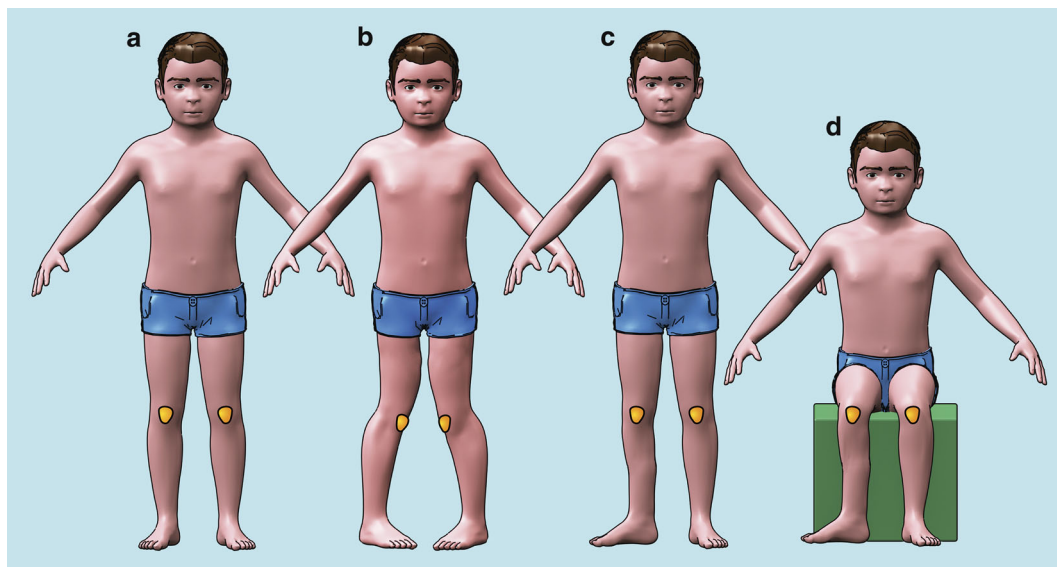


Fig. 2 (a–d) (a) Normal rotational alignment of the lower limbs. (b) Bilateral Internal rotation deformity of the lower limbs (in-toeing), partly due to exaggerated femoral anteversion, as the patella are “kissing” each other. (c) Right-side external rotation deformity due to external tibial torsion (patella is pointing forwards). (d) Sitting position showing external rotation deformity of the right tibia

importance in the identification and assessment of rotational deformities and limb length discrepancies. For rotational deformities, clinical examination is usually sufficient to quantify, plan, and correct the rotational deformity (Figs. 2 and 3). For a more precise measurement of rotational deformities, a CT scan can be performed (Fig. 4). Plain X-rays may suggest a rotational malalignment, but cannot quantify the magnitude of the deformity. For limb length discrepancies, a wooden block placed under the shorter leg to level the pelvis usually gives a good clinical measure of the magnitude of shortening (Fig. 5). When there are angular deformities in the limbs, it is important to differentiate true from apparent LLD (Fig. 6). Each deformity should be identified and characterized separately in order to decide which one (or ones) needs to be addressed and which need not be corrected.

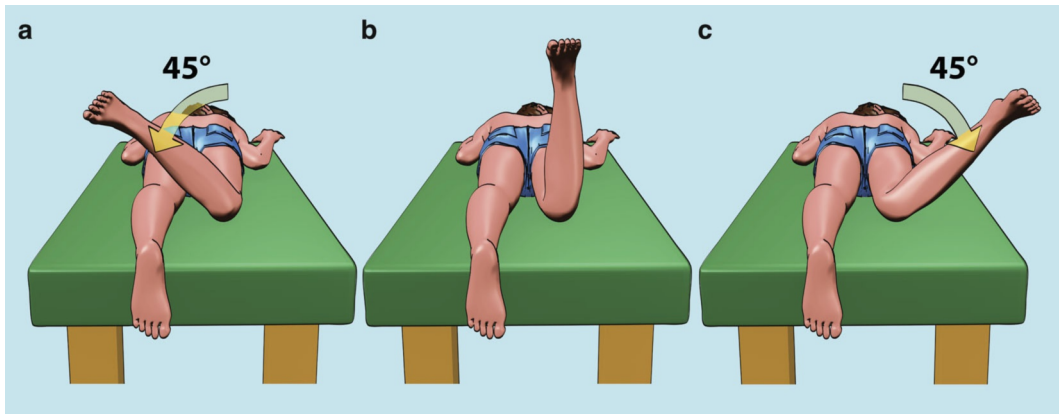


Fig. 3 Rotational alignment in the prone position. (a) Hip external rotation. (b) Hip in neutral position. (c) Hip internal rotation

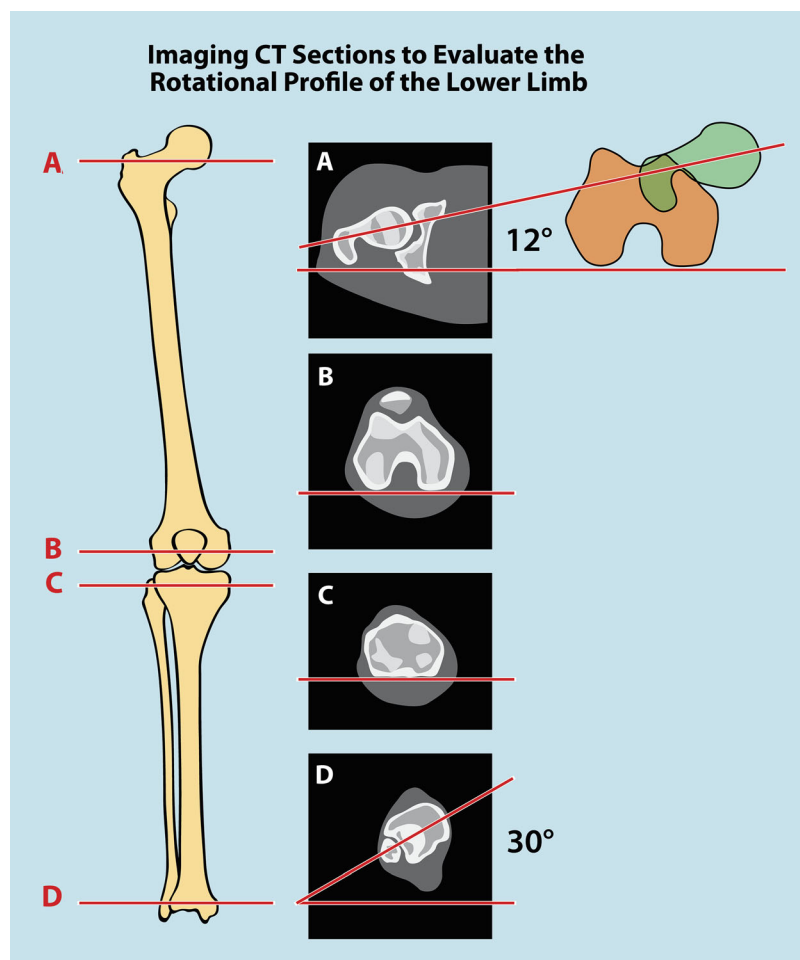


Fig. 4 CT scan measurement of rotational profile, using transverse cuts through. (a) Proximal femur (femoral anteversion) – normal 12°. (b) Distal femur (femoral condyle alignment). (c) Proximal tibia. (d) Distal tibia

Radiological assessment of bony deformities should address **six key questions**:

- What is the plane of the deformity (frontal, sagittal, or oblique)?
- What is the direction of the deformity (varus/valgus, anterior/posterior)?

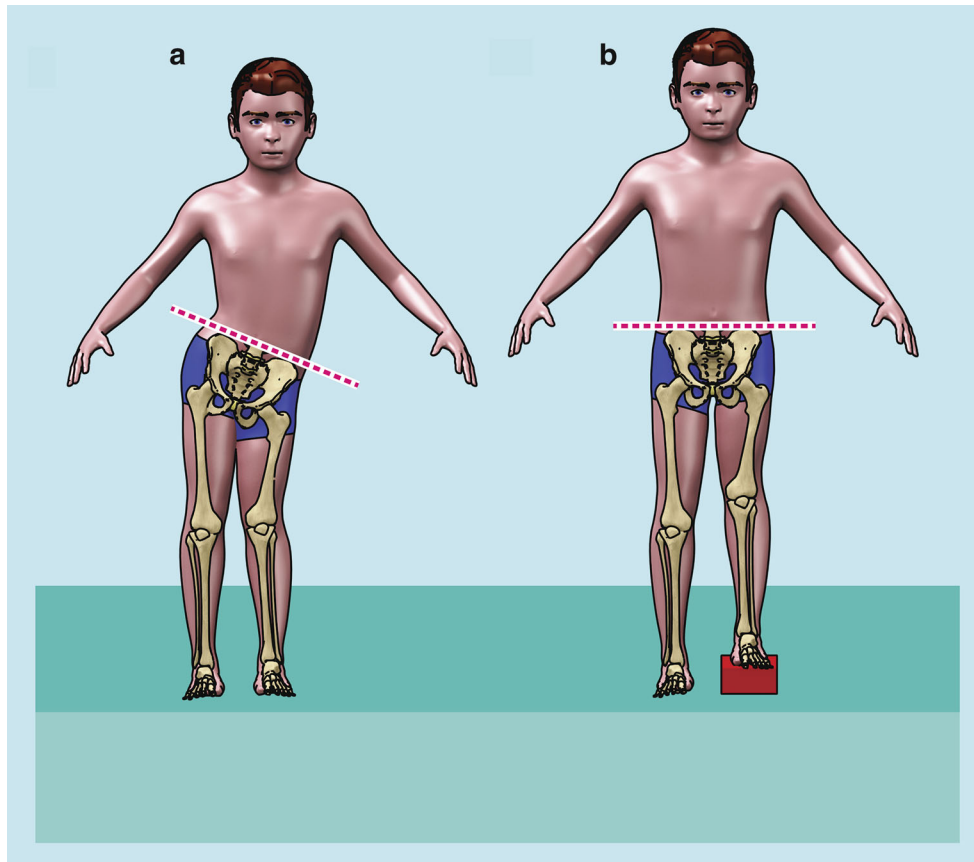


Fig. 5 Measurement of LLD with wooden blocks. (a) Without block, the pelvis is oblique. (b) With wooden block elevation equal to the LLD, the pelvis is level. This method takes into consideration the heel height, but cannot be used in the presence of knee or hip contractures

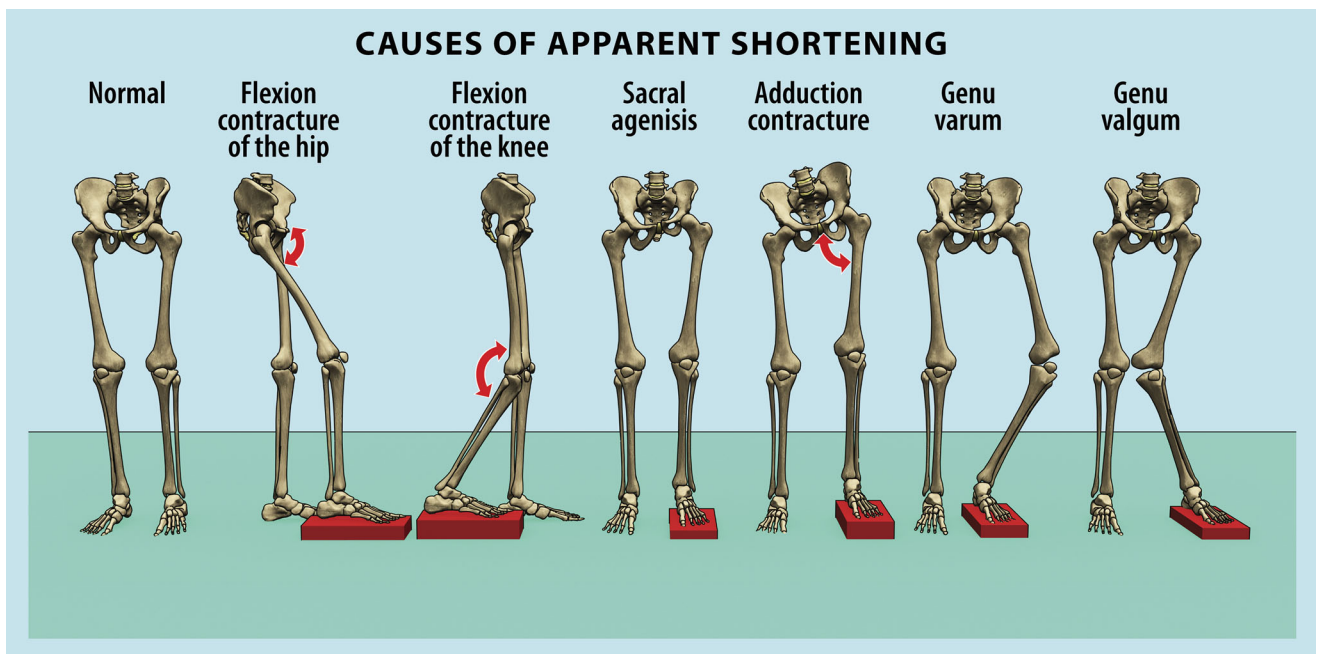


Fig. 6 Causes of apparent limb length discrepancy

- Which bone and/or joint is affected (femur, tibia, knee, or ankle joint)?
- Which segment of the bone is affected (epiphysis, metaphysis, or diaphysis)?
- Where is the apex of the deformity?
- What is the magnitude of the deformity?

The next step is to decide **whether or not the deformity needs to be corrected**. In other words, what are the indications for surgery? The decision to surgically address a deformity should take into consideration symptomatology, radiological assessment, the functional limitations of that deformity, the potential psychosocial impact of surgery, and the ability of surgery to improve these problems. In general, if function is affected, then surgery is indicated. The **goal of correcting any deformity** is to improve function and restore normal mechanical alignment of the lower limbs and thus prevent degenerative changes in the articular cartilage.

Having decided to proceed with surgical correction of the deformity, the next question is **how to correct the deformity**: is it by acute or gradual correction? If it is decided to proceed with an **acute correction**, then what type of osteotomy should be performed: closing, opening, neutral wedge, dome, or oblique osteotomy. One must consider how to stabilize the osteotomy: by internal or external fixation. To increase the accuracy and ease of acute correction, **fixator-assisted plating or nailing** techniques could be enlisted. The second option is **gradual correction** of the deformities by either **growth modulation** (in skeletally immature patients) or with external fixators or internal devices. The third option is **combined acute and gradual correction**, where one or more deformities are acutely corrected and then gradual correction is used for the remaining deformities, usually limb length discrepancy.

Radiological Assessment of Lower Limb Deformities

The first step is to obtain appropriate X-rays of the entire lower limbs standing with patellae pointing forward (usually the patella can be seen on the X-rays), as well as AP and lateral views of affected bones.

The following parameters are analyzed:

- (I) Mechanical and anatomical alignment of the whole lower limb as well as that of individual bones
- (II) Joint orientation lines
- (III) Joint orientation angles
- (IV) Apex of the deformity as determined by the CORA (center of rotation of angulation)

Mechanical Alignment of the Lower Limbs (Weight-Bearing)

Frontal Plane Alignment

Each long bone has two axes: mechanical and anatomical (Fig. 7).

The **mechanical axis** of a long bone is represented by a line joining the centers of the joints proximal and distal to that bone. The **anatomical axis** passes through the center of the diaphysis and is represented by a line joining the center of the transverse diameter of the diaphysis through several points along the bone:

- **Mechanical Axis** of the whole lower limb (Fig. 7a).
 - Is a straight line from the center of the femoral head to the center of the ankle or middle of tibial plafond.

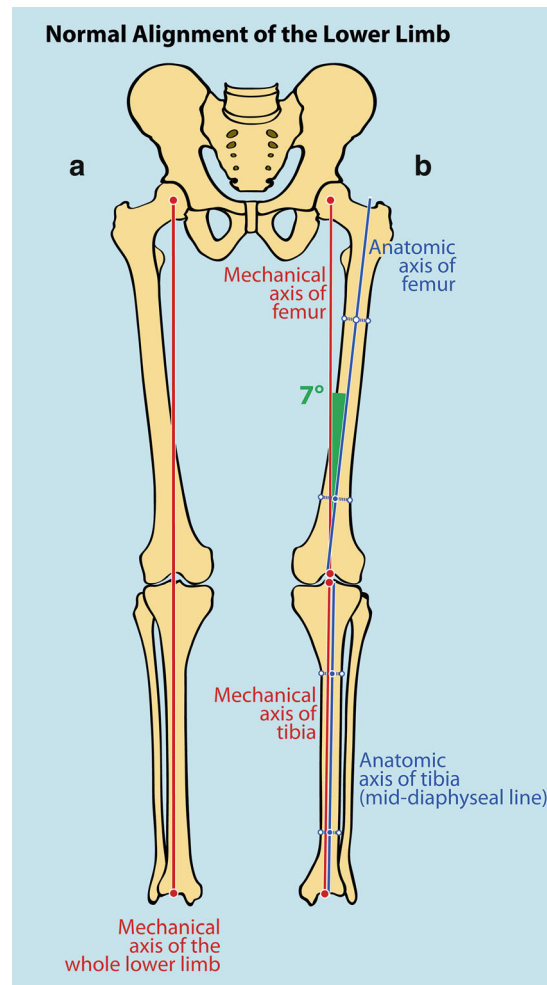


Fig. 7 (a) Mechanical axis of the whole lower limb. (b) Mechanical and anatomical axes of the femur and tibia

- This is always a straight line.
- Falls just medial to the center of the knee (up until 8 mm).
- Measures varus/valgus angulation.
- **Mechanical and anatomical axes of individual bones (Fig. 7b):**
 - (a) **Femur mechanical axis**
From center of the femoral head to center of the knee (different from the anatomical axis)
 - (b) **Femur anatomical axis**
Is a mid-diaphyseal line: straight in the frontal plane
Curved in the sagittal plane
 - (c) **Tibia mechanical axis**
Line from the center of the knee to the center of the ankle
 - (d) **Tibia anatomical axis**
Mid-diaphyseal line
- In the tibia, anatomical and mechanical axes are parallel and for practical purposes are the same
- **Mechanical axis deviation (MAD) or malalignment (Fig. 8).**
 - Represents loss of colinearity of the hip, knee, and ankle in the frontal plane.
 - Is the distance between the mechanical axis of the whole lower limb and the center of the knee. Could also be expressed in percentage.

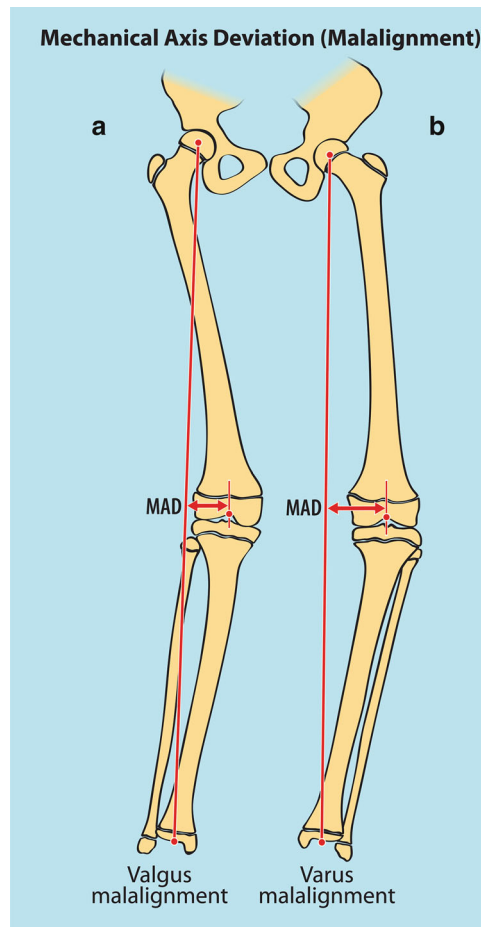


Fig. 8 (a) Valgus mechanical axis deviation (valgus malalignment). (b) Varus mechanical axis deviation (varus malalignment)

- As mechanical axis falls medial to the center of the knee, MAD up to 8 mm is considered normal.
- Any MAD greater than 8 mm (some authors consider 15 mm) medial to the knee center is considered varus malalignment.
- Any MAD lateral to the center of the knee is considered valgus malalignment.
- In general, malalignment in the frontal plane is much more serious than in the sagittal plane. The consequences of frontal plane malalignment on the knee (varus/valgus) are well described and documented and may lead to degenerative osteoarthritis, while the consequences of malalignment in the sagittal plane are less well defined. The knee joint is a uniaxial joint allowing no motion in the frontal plane, and any degree of malalignment in the frontal may be detrimental. That is not the case in the sagittal plane, where motion in the sagittal plane occurs all the time during walking, sitting, and other activities.
- MAD can occur secondary to bony deformities in the femur or tibia and joint deformities in the knee or ankle (due to ligamentous laxity or joint incongruity such as medial plateau depression in Blount's disease).

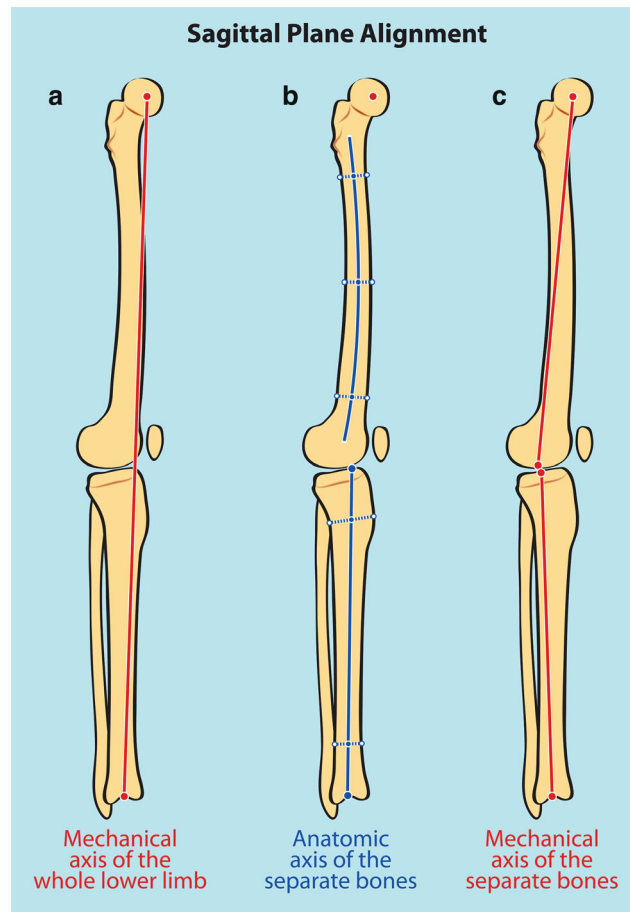


Fig. 9 Sagittal plane alignment. (a) Entire lower limb (falling through anterior part of the knee). (b) Anatomical axis of the femur (not a *straight line*) and tibia (*straight line*). (c) Mechanical axis of femur and tibia

Sagittal Plane Alignment

Whole lower limb falls just in front of the center of the knee joint line (Fig. 9)

- (a) **Femur mechanical axis**
From center of the femoral head to center of knee
- (b) **Femur anatomical axis**
Is a mid-diaphyseal line: curved in the sagittal plane
- (c) **Tibia mechanical axis**
Line from the center of the knee to the center of the ankle
- (d) **Tibia anatomical axis**
Line from the anterior one fifth of the proximal tibia to the center of the ankle joint

Joint Orientation Lines Assessment

This represents the relation of the joint axis to the anatomic and mechanical axis of a bone. Joint orientation lines are drawn on both frontal and sagittal planes.

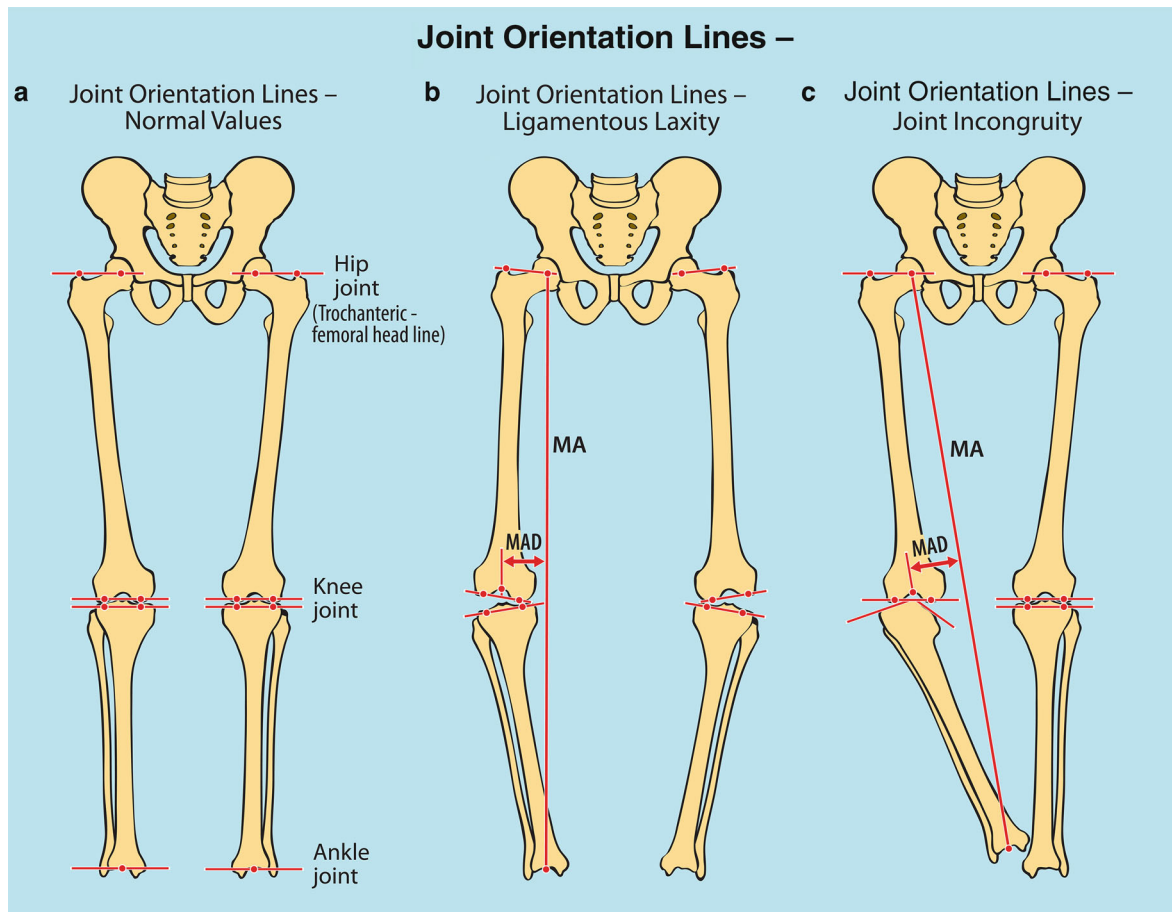


Fig. 10 Joint Orientation lines in coronal (frontal) plane. (a) Normal lines and alignment. (b) Varus malalignment due to ligamentous laxity. (c) Varus malalignment due to joint incongruity

Frontal Plane

(a) Hip joint orientation (Fig. 10a):

1. Trochanteric – femoral head line: line from the tip of greater trochanter to center of the femoral head
2. Femoral neck line: line drawn from the hip joint center to several points that bisect the diameter of the femoral neck

(b) Knee joint orientation:

Represents the relation of the knee joint line to the distal femur and proximal tibia

- Normally is in valgus 3° .
- This is the most important measurement.
- Represented by lines joining the two femoral condyles and a line joining the two tibial plateaus. These 2 lines should be parallel (more than 2° considered abnormal and a source of MAD).
- Joint line congruence angle (JLCA) is the angle between these two lines.

If not parallel, this is caused either by joint laxity (such as in children with achondroplasia) (Fig. 10b) or by articular surface incongruity (such in Blount's disease with depressed medial tibial plateau) (Fig. 10c).

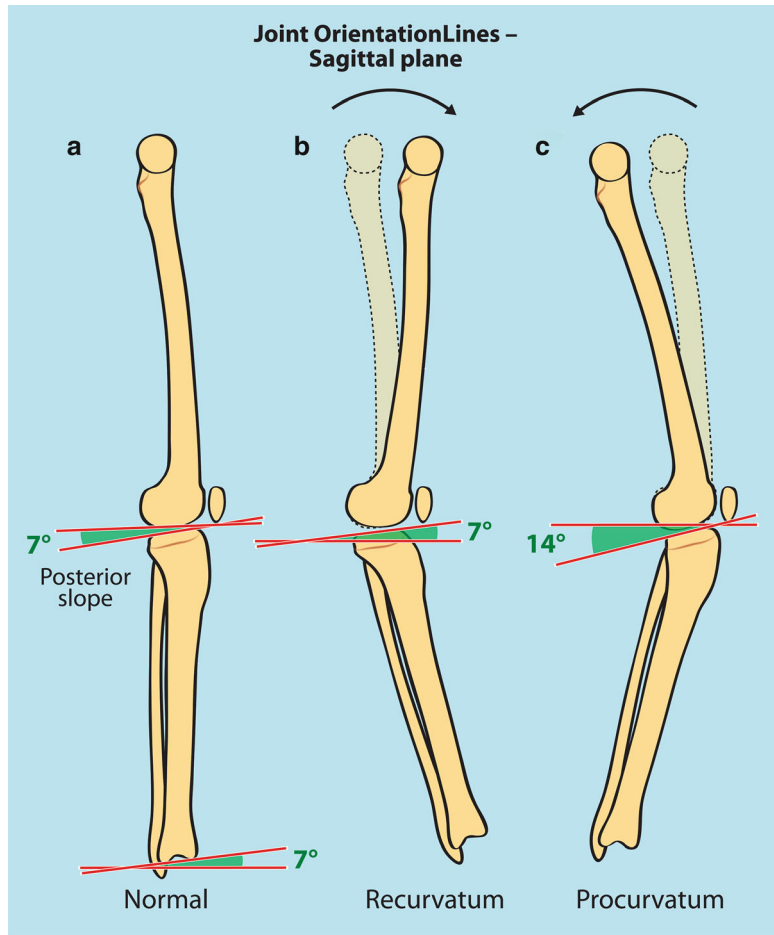


Fig. 11 Joint orientation lines in sagittal plane. (a) posterior slope of the tibial plateau (normal 7–9°) and anterior slope of the tibial plafond (normal 7–10°). (b) Tibia recurvatum with anterior slope of 7°. (c) Tibia procurvatum with exaggerated posterior slope of 14°

(c) Ankle joint orientation:

- Line drawn along the tibial plafond
- Parallel to the floor or slight valgus (up to 8°)

Sagittal Plane

(a) Knee joint orientation (Fig. 11):

- A line drawn along the tibial plateau
- Normally 7–9° posterior slope

(b) Ankle joint orientation line:

- A line drawn through the most distal points of the anterior and posterior distal tibia
- Normally, about 7–10° anterior slope

Joint Orientation Angles

These are angles formed between the joint lines and either the mechanical or anatomic axis of separate bones.

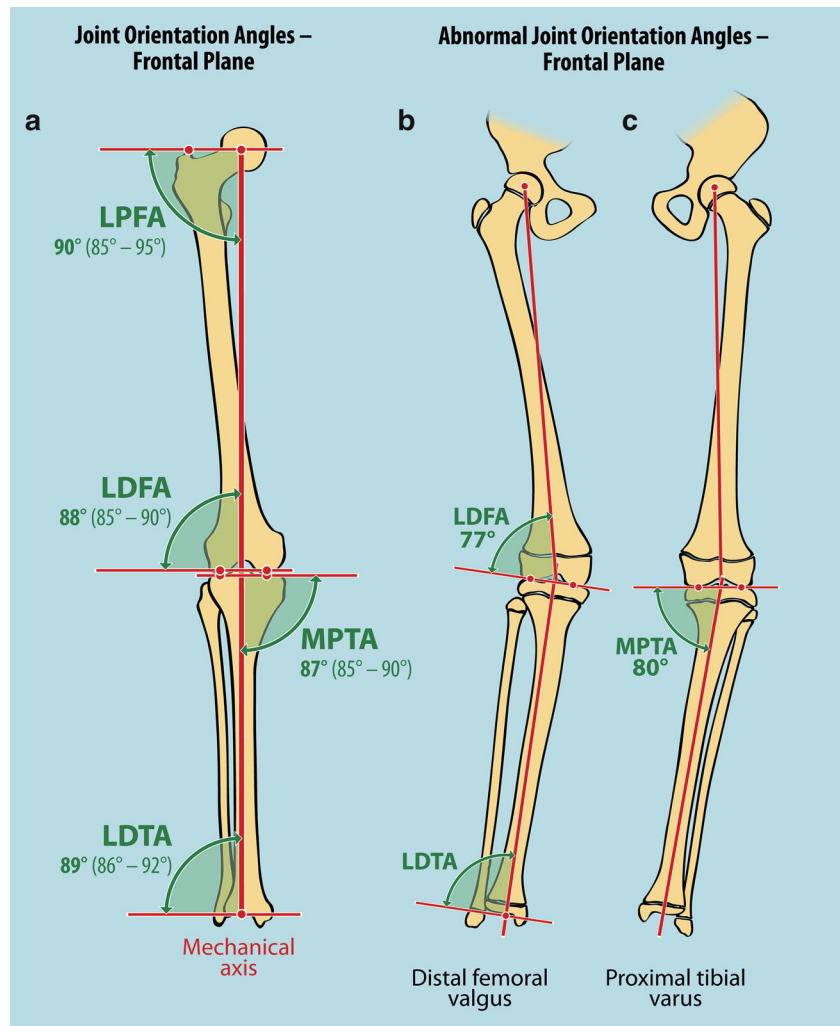


Fig. 12 Joint orientation angles in frontal plane. (a) Normal values. (b) mLDFA of 77° causing distal femoral valgus. (c) mMPTA of 80° causing proximal tibia varus

Frontal Plane (Fig. 12)

- **LDFA (Lateral Distal Femoral Angle)**. This measures the angle between the distal articular femoral surface and either the mechanical or anatomical axis of the femur. The distal femoral articular surface is in slight valgus of one or two degrees when mechanical LDFA is measured and in about 7° of valgus when the anatomical LDFA is measured (Fig. 12a).
- **MPTA (Medial Proximal Tibial Angle)**. This measures the angle between the proximal tibial articular surface and the mechanical or anatomical axis of the tibia. The proximal tibial articular surface is in about 1 – 3° varus with both mechanical and anatomical axis.
- **LDTA (Lateral Distal Tibial Angle)**. This measures the angle between the distal tibial articular surface and the anatomical or mechanical axis of the tibia (both are the same). It measures about 90°.

Abnormal joint orientation angles are demonstrated in Fig. 12, showing distal femoral valgus (Fig. 12b) and proximal tibia vara (Fig. 12c).

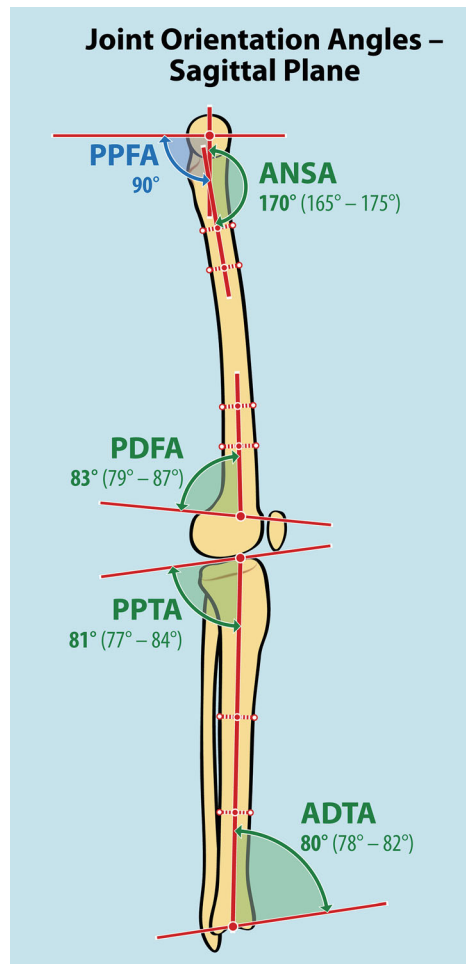


Fig. 13 Joint orientation angles in sagittal plane: normal values

Sagittal Plane (Fig. 13)

- **PPFA (Posterior Proximal Femoral Angle).** This is measured between the mid-diaphyseal line of the neck of the femur and the line across the physis or physal scar of the femoral head. Normally 90°.
- **ANSA (Anterior Neck Shaft Angle).** It is measured between the sagittal plane mid-diaphyseal line of the proximal femur and the mid-diaphyseal line of the neck of the femur. About 170°.
- **PDFA (Posterior Distal Femoral Angle).** This is measured between the sagittal distal femoral joint line and the mid-diaphyseal line of the distal femur. Usually about 83° (Fig. 13).
- **PPTA (Posterior Proximal Tibial Angle).** This represents the angle between the proximal tibial surface and the mechanical axis of the tibia. It is usually about 81°.
- **ADTA (Anterior Distal Tibial Angle).** This represents the angle between the distal articular surface and mechanical axis of the tibia. It is usually about 81°.

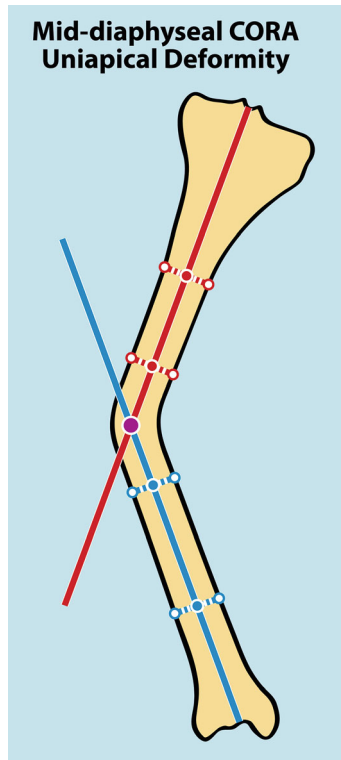


Fig. 14 Uni-apical deformity at the mid-diaphyseal region of tibia. CORA is located at the intersection of the anatomical axis of the proximal and distal segments of the tibia

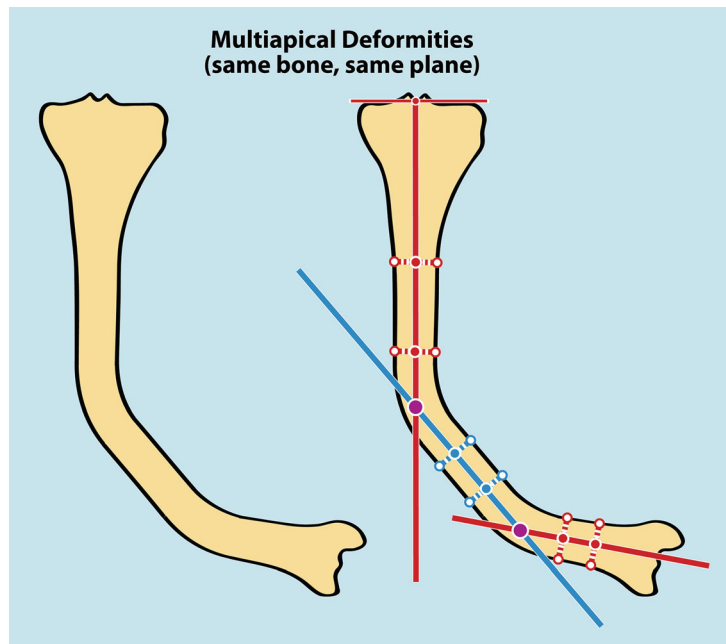


Fig. 15 Multi-apical deformities of tibia. Double CORA present at the intersection of the anatomical axes of the proximal, middle, and distal segments of the tibia

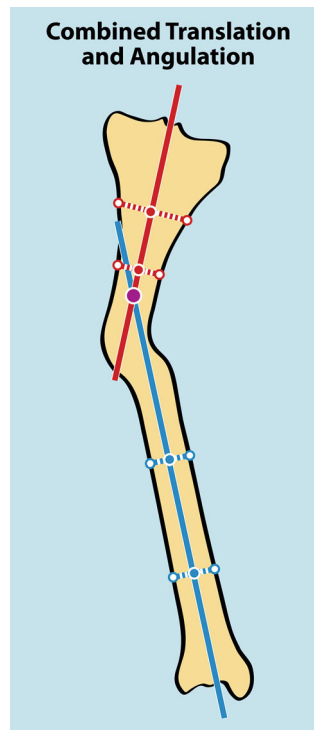


Fig. 16 When apex of the deformity and CORA do not correspond, a translational deformity is present

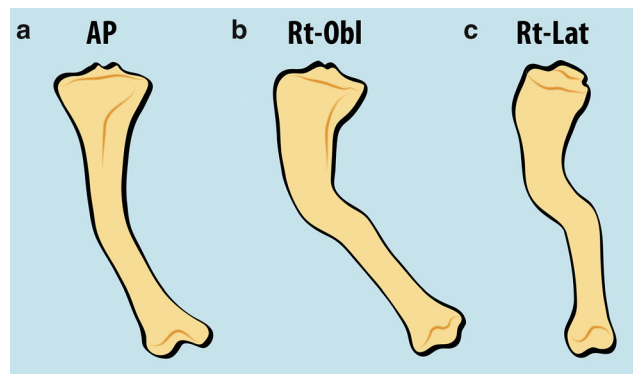


Fig. 17 Presence of multiplanar deformities in frontal plane (a), oblique plane (b), and sagittal plane (c). In the presence of multiplanar deformities, the deformity in the oblique plane is always greater than either the frontal or sagittal plane deformity

Determining the Apex of the Deformity or CORA (Centre of Rotation of Angulation)

- Used to define where the apex of the deformity is located within the bone.
- Determining the CORA is crucial for surgical planning of correction of any angular deformity and will serve as the site of osteotomy or hinge.
- If deformity is **diaphyseal**, the anatomical axis should be used. The apex of the deformity or CORA is the intersection of the diaphyseal lines of proximal and distal fragments (Fig. 14).

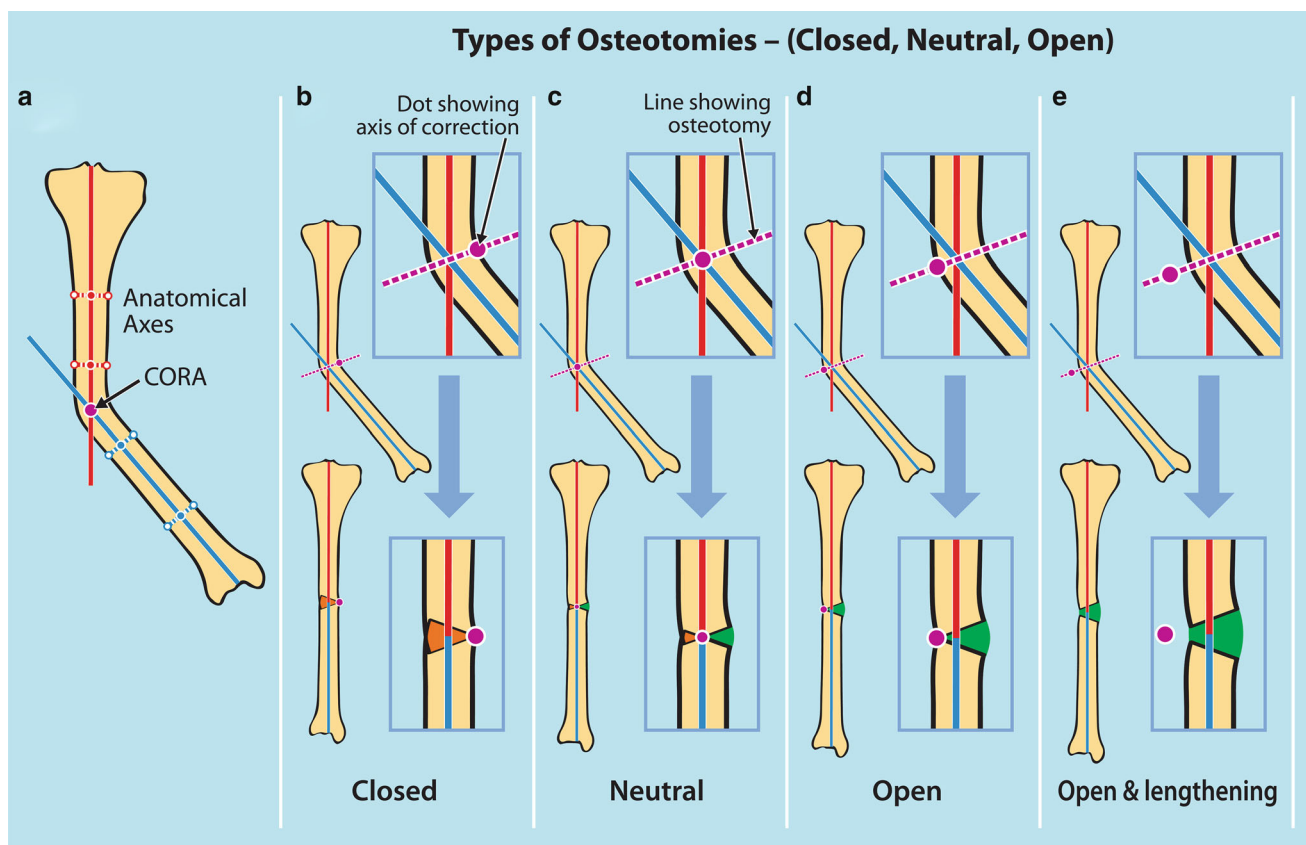


Fig. 18 Types of osteotomies and the impact of axis of correction position. All osteotomies in this figure are placed upon CORA and apex of deformity. (a) Mid-diaphyseal deformity. CORA and apex of deformity are the same. (b) If axis of correction is situated on the concave side of the deformity, a closing wedge osteotomy is produced. (c) If axis of correction is situated in the mid-diaphyseal area (the same

as CORA and apex of the deformity), a neutral osteotomy is produced. (d) If axis of correction is situated on the convex side of the deformity, an opening wedge osteotomy is produced. (e) If the axis of correction is situated outside the diaphysis, distraction is produced, together with the opening wedge osteotomy. The further the axis of correction is from the diaphysis, the greater the distraction is

- If the deformity is **metaphyseal or juxta-articular** (epiphyseal), the CORA is determined by the intersection of a line perpendicular to the joint orientation line and the mid-diaphyseal line of the deformed segment or bone (Figs. 20 and 21).
- More than one CORA may exist in the same bone (multi-apical deformity) (Fig. 15).
- If CORA and apex of the deformity do not coincide, then there is an additional translational deformity (Fig. 16).
- If the CORA is present on both the frontal and sagittal planes, then an oblique deformity exists. The magnitude of an oblique plane deformity is always greater than what it measures in either the frontal or sagittal planes (Fig. 17).
- The impact of the anatomical location of the axis of correction on the type of osteotomy – closed, open, and neutral – is shown in Fig. 18.
- The impact of placement of the osteotomy relative to CORA and axis of correction on the resulting translation is shown in Fig. 19.

Malalignment test. This includes performing all the previously mentioned measurements: mechanical alignment of the whole lower limb and of separate bones, calculating MAD, drawing joint orientation lines, measuring joint orientation angles, and determining the site and amount of the CORA or CORAs. It should be emphasized, however, that all of these measurements are static and not dynamic.

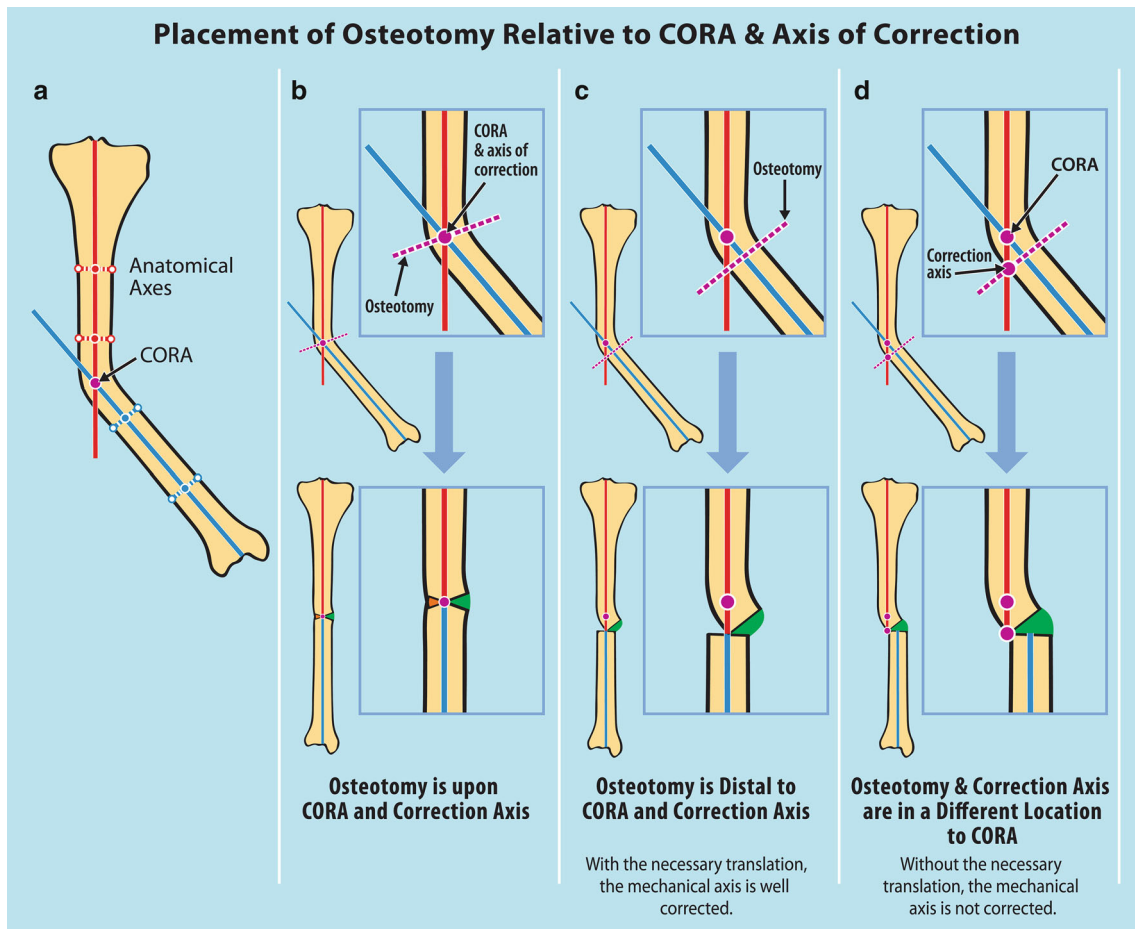


Fig. 19 The impact of placement of osteotomy relative to CORA and axis of correction. **(a)** Mid-diaphyseal deformity. CORA, and apex of deformity are the same. **(b)** Osteotomy performed upon CORA and axis of correction. **(c)** Osteotomy performed distal to CORA and axis of

correction. Mechanical axis is corrected because of the translation. **(d)** Osteotomy and axis of correction are in a different location than CORA. Mechanical axis not corrected, because there is no translation

By using this systematic approach, the core 6 questions (previously mentioned) could then be answered and the deformity fully appreciated:

- What is the plane of the deformity (frontal, sagittal, or oblique)?
- What is the direction of the deformity (varus/valgus, anterior/posterior)?
- Which bone and/or joint is affected (femur, tibia, knee, or ankle joint)?
- Which segment of the bone is affected (epiphysis, metaphysis, or diaphysis)?
- Where is the apex of the deformity?
- What is the magnitude of the deformity?

Examples of step-by-step approach in the assessment of various lower limb deformities are shown in Figs. 20, 21, 22, and 23:

- Figure 20: Distal femoral valgus deformity
- Figure 21: Proximal medial tibial deformity
- Figure 22: Uni-apical mid-diaphyseal deformity of tibia
- Figure 23: Double apical diaphyseal deformity of tibia

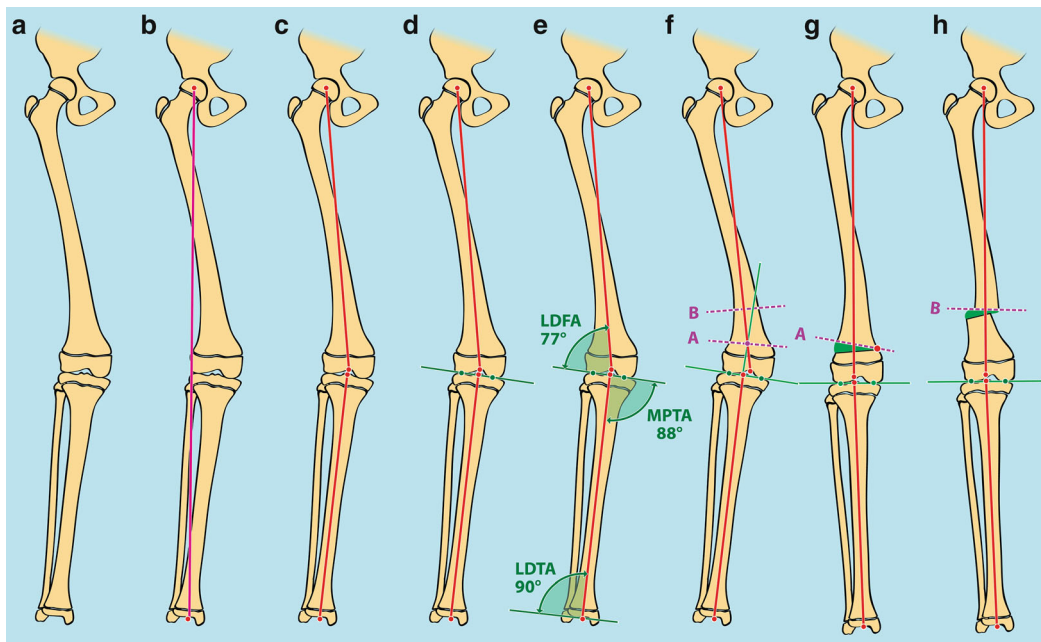


Fig. 20 Example of distal femoral valgus deformity – step-by-step approach. (a) Diagram showing the deformity. (b) Mechanical axis of entire limb showing valgus malalignment. (c) Mechanical axis of femur and tibia. (d) Joint orientation line of knee. (e) Joint orientation angles: mLDFA 77°, MPTA 88°. (f) Red dotted lines showing two different levels of osteotomy. (g) If osteotomy performed upon CORA and axis of

correction (situated on lateral cortex on the same line as the CORA), then an opening wedge is produced, and there is no translation. (h) If osteotomy performed proximal to CORA and axis of correction is on the lateral cortex on same line as osteotomy, then translation is required to maintain mechanical alignment

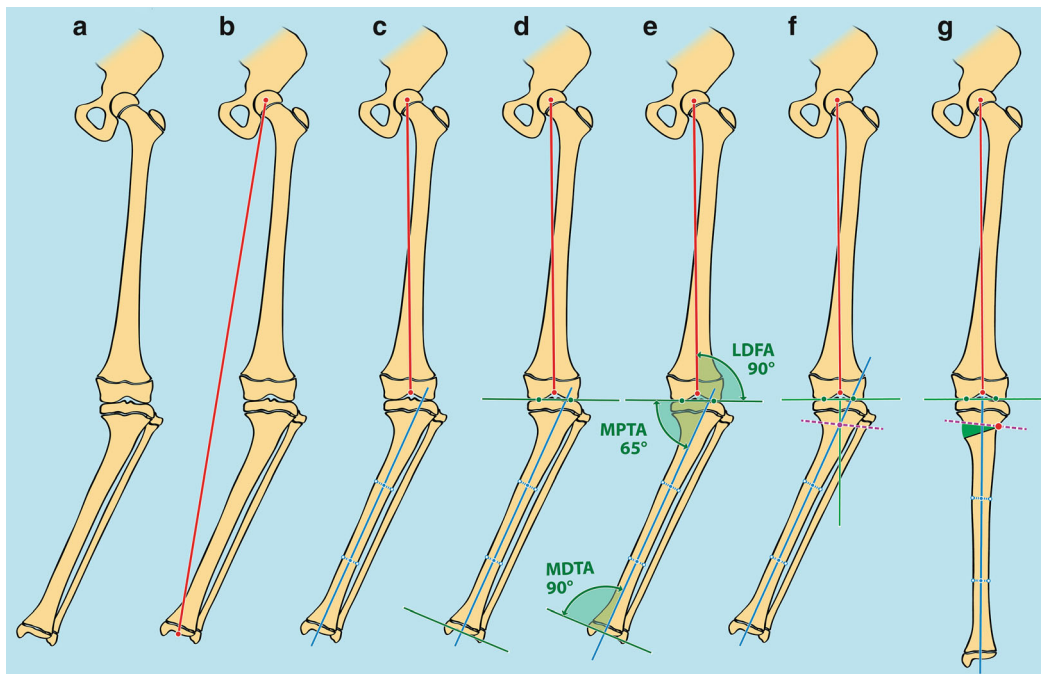


Fig. 21 Example of proximal medial tibial deformity – step-by-step approach. (a) Diagram showing the deformity. (b) Mechanical axis of entire limb showing varus malalignment. (c) Mechanical axis of femur and anatomical axis of the tibia. (d) Joint orientation lines of the knee and ankle. (e) Joint orientation angles: mLDFA 90°, MPTA 65°, MDTA

90°. (f) Red dotted line showing line of osteotomy at CORA. (g) Correction of the deformity causing an opening wedge osteotomy as apex of correction is on the convex side of the deformity (shown by the red dot)

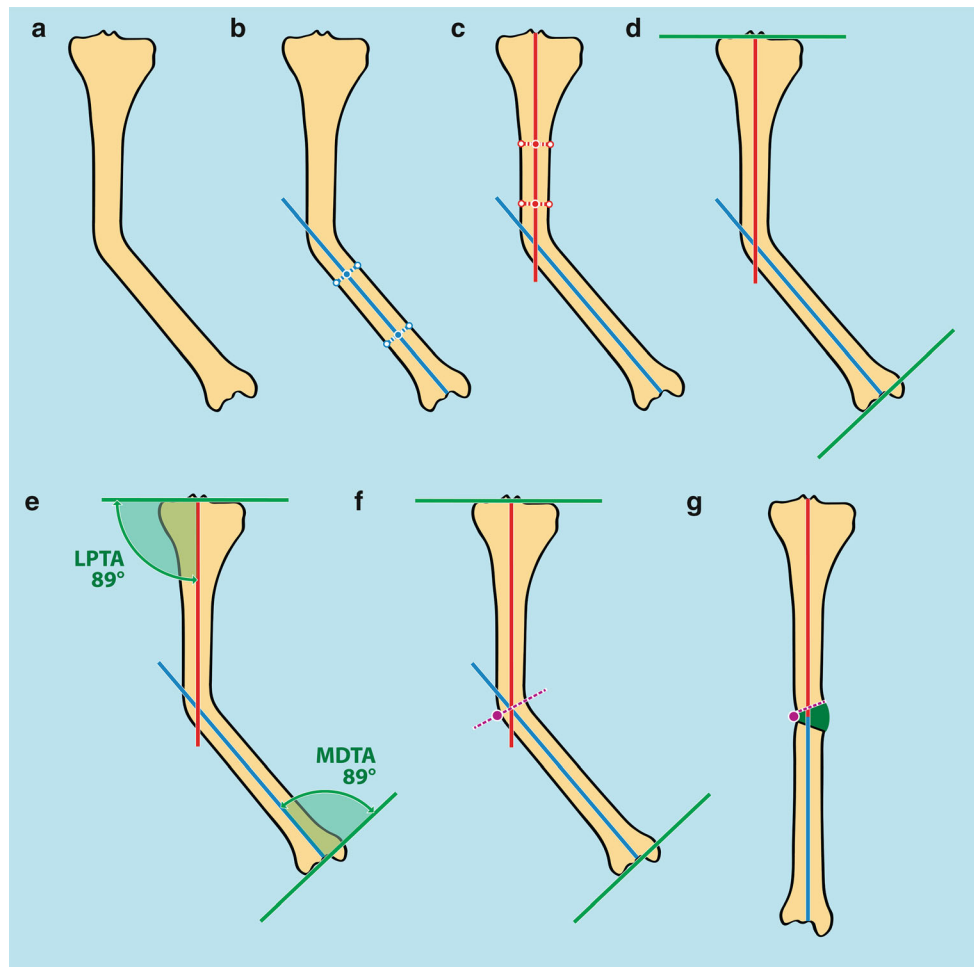


Fig. 22 Example of uni-apical mid-diaphyseal deformity of the tibia – step-by-step approach. (a) Diagram showing the deformity. (b) Anatomical axis of distal tibial segment. (c) Anatomical axis of proximal tibial segment and CORA. (d) Joint orientation lines of the knee and

ankle. (e) Joint orientation angles LPTA 89° and MDTA 89° showing that the deformity is diaphyseal. (f) Osteotomy performed upon CORA. Axis of correction lies on the convex side same line as CORA. (g) Opening wedge osteotomy with restoration of anatomical axis of tibia

Acute Versus Gradual Correction

Several factors should be taken into consideration before deciding on whether an acute or gradual correction should be performed. These include:

- **Age of the patient.** Uniplanar deformities in very young children can be safely and successfully corrected by gradual correction (growth modulation) with 8 plates.
- **Amount to be corrected.** It is generally accepted that deformities less than $15 - 20^\circ$ can be adequately and safely addressed with an acute correction, while deformities greater than this are better addressed by gradual correction.
- **Site of the deformity.** Excessive stretching of the surrounding neurovascular structures is always a concern when performing acute correction, specially if these structures are anatomically located on the concave site of the deformity, as in the case of valgus deformities of the distal femur and proximal tibia. In these cases, the common peroneal nerve is vulnerable and at risk of neuropraxia; therefore, prophylactic decompression of this nerve should be performed prior to the acute correction. The same applies around the ankle, where a tarsal tunnel release may be indicated before proceeding with an acute correction. On the

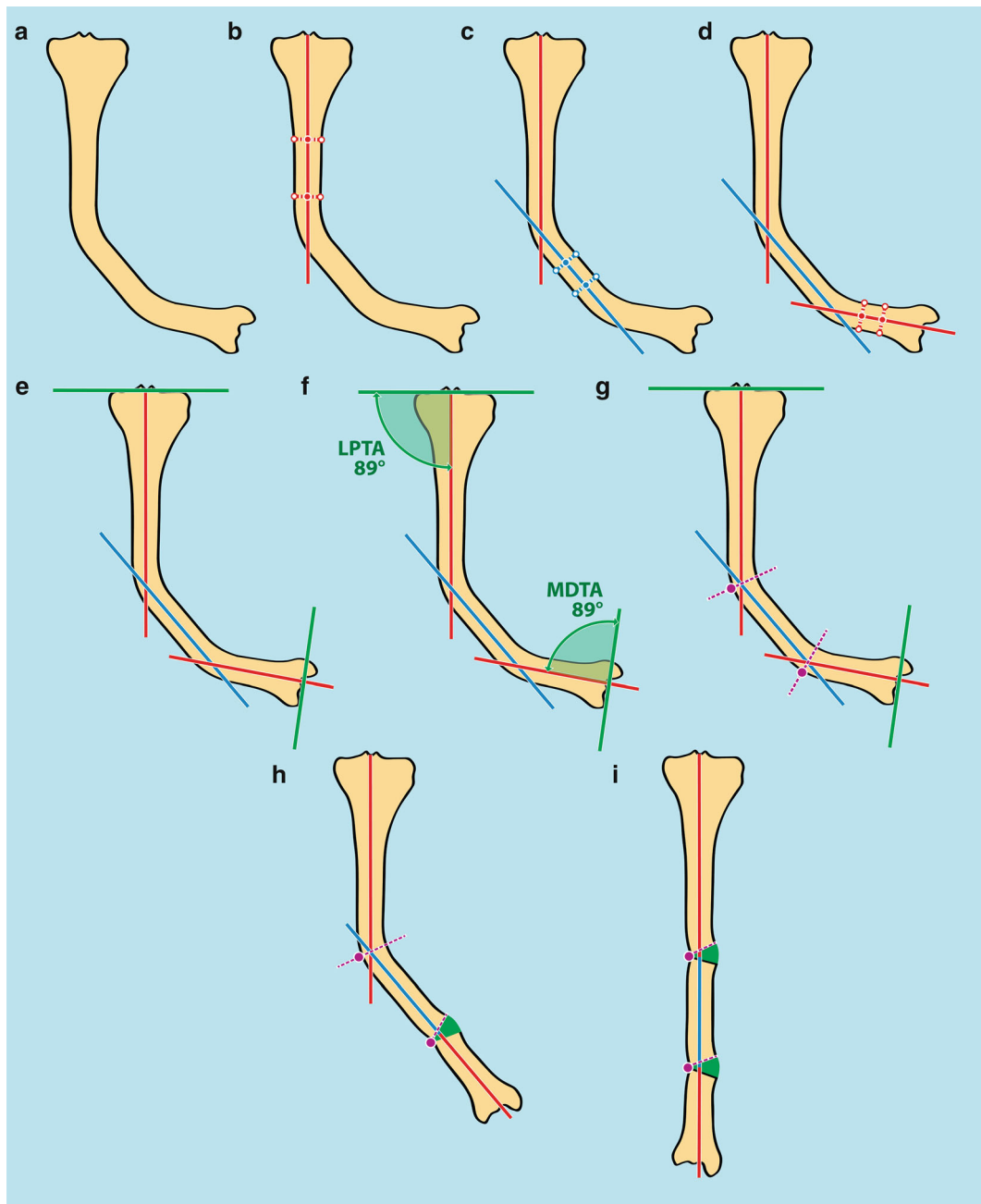


Fig. 23 Example of double apical diaphyseal deformity of the tibia – step-by-step approach. (a) Diagram showing deformity. (b) Anatomical axis of proximal segment. (c) Anatomical axis of middle segment. (d) Anatomical axis of distal segment with double CORA. (e) Joint orientation lines. (f) Joint orientation angles. (g) Lines of osteotomies upon

both CORA. (h) Deformity correction at distal CORA causing an opening wedge osteotomy as axis of correction is on the convex side of deformity. (i) Deformity correction at proximal CORA also causing an opening wedge osteotomy as axis of correction is on the convex side of the deformity

other hand, acute correction of diaphyseal deformities of the femur is less likely to cause neurovascular problems.

- **Status of the surrounding soft tissues.** Previous surgeries or scarring due to burns or trauma often lead to soft tissue fibrosis and disturbed anatomy. In these cases, extensive dissection should be avoided as this may further damage the soft tissues. Furthermore, the dissection may be technically difficult as all the anatomy is abnormal making it challenging to recognize the vital structures.

- **Quality of the bone to be corrected.** In some cases of severe osteopenia (such as osteogenesis imperfecta), the bones are so weak and soft that they may be unable to withstand the stresses of external fixators, and in such cases an acute correction and intramedullary stabilization may be indicated.
- **Associated limb length discrepancy.** If there is an associated limb length discrepancy, then a gradual correction that could address all the deformities simultaneously is indicated.
- **Amount of bone to be resected.** If an acute correction is contemplated, then shortening of the bone at the site of the deformity – in order to accommodate the soft tissue contractures – will probably be necessary, and this should be planned preoperatively and clearly explained to the patient and family. This is especially true for rigid foot deformities that are corrected with osteotomies and acute correction.

Preoperative planning should address all the above mentioned issues, and each case should be individualized.

Gradual Correction

In the skeletally immature patient, this could be carried out either by growth modulation with 8 plates or external fixators. In skeletally mature patients, osteotomies and gradual distraction with various types of unilateral, circular, or hybrid fixators are the only techniques available.

Advantages of Gradual Correction with 8 Plates

“The best osteotomy is NO osteotomy” (John Herzenberg). Growth modulation has radically changed our approach to the correction of long bone deformities in the skeletally immature patient. Whenever possible, it is always better to use growth modulation. It is a minimally invasive surgery compared to osteotomy. It can be performed at a very young age (as young as the age of 2 years). When correction is obtained, the plate can be removed, or one of the screws, generally the metaphyseal one, can be removed leaving the plate and epiphyseal screw in place so that if the deformity recurs it can be easily reapplied percutaneously. Most importantly, it is not a permanent correction. This may avoid more extensive surgery in the form of osteotomies whether for gradual or acute correction. However, as seen in several cases of the atlas, growth modulation is not always successful and may not yield satisfactory results in cases of severe and/or multiple deformities (adolescent Blount’s, skeletal dysplasias, rickets). Furthermore, the correction with 8 plates takes a more prolonged time than with the use of external fixators. In addition, growth modulation has its maximum effect in the first decade and may be less reliable when it is applied near skeletal maturity.

Advantages of Gradual Correction with External Fixators

These are numerous and include:

1. Minimal invasive surgery and minimal soft tissue dissection. This is mostly a percutaneous technique.
2. Can generate new bone (in cases of gradual open wedge osteotomy).
3. Extremely versatile.
4. Allows adjustments during correction of the deformities.
The inability to obtain a standing hip to ankle radiograph during surgery limits the precision of an intraoperative correction. With external fixation stabilization, the position can be changed acutely or gradually after a standing hip to ankle radiograph is obtained and the appropriate mechanical axis analysis is performed.
5. Allows certain amount of axial loading, which is beneficial for bone healing.
6. Can be used in the presence of acute and chronic infection.

7. It is easier to obtain an accurate reduction with gradual correction, specifically if multiplanar deformities are present.
8. In severe deformities, a bone resection can be avoided.
9. Less risk of neurovascular complications and compartment syndrome that may occur with acute corrections.
10. Simultaneous limb lengthening is possible
11. The use of external fixators allows immediate full weight-bearing and allows functional use of the limb.

The **disadvantages of gradual correction** include all the problems associated with prolonged time needed to wear the external fixator while the newly formed bone consolidates, necessitating multiple clinic visits and missing school days, potential for psychosocial problems, prolonged rehabilitation, and all other medical problems including pin site infection, pain, and swelling.

Therefore, we believe gradual correction using external fixators is **indicated** if there is an associated limb length discrepancy requiring lengthening by distraction osteogenesis, extensive soft tissue scarring from previous surgeries, trauma or burns, multiple complex deformities and severe bony deformities.

Acute Correction

Acute correction offers several advantages. Usually all the deformities are corrected in one surgery only, a quicker return to daily activities is usually possible (although the patient may be non-weight-bearing or toe touching) and the absence of any of the problems associated with external fixation. The use of fixator-assisted acute correction could increase the accuracy of acute correction.

Disadvantages of acute correction include a lack of post-op adjustability: No further adjustment of the correction could be made. Furthermore, any associated LLD could not be addressed at the same time.

Combined Gradual and Acute Correction

In some cases of multiple deformities, especially when both femur and tibia are affected, a viable alternative is acute correction of the deformities in one bone (usually the femur) and gradual correction of the other, as discussed in several cases in the atlas. The femoral deformities are addressed by acute correction (whether standard technique or fixator assisted), and the tibial deformities are addressed by gradual correction with external fixators. This avoids having two external devices (on femur and tibia) and allows simultaneous correction of all deformities in the affected limb, with the least “cumbersome” fixation.

References and Suggested Reading

- Brinker MR, O'Connor DP (2012) Principles of malunions. In: Rockwood CA, Bucholz RW, James C-B, Heckman JD, Paul T (eds) Rockwood and Green's fractures in adults, 7th edn, vol 1. Lippincott Williams & Wilkins, Philadelphia, pp 641–664
- Hamdy RC, McCarthy JJ (2011) Management of limb-length discrepancies. Monograph series, vol 45. American Academy of Orthopaedic Surgeons, Rosemont
- Paley D (2002) Principles of deformity correction. Springer, Heidelberg/Berlin
- Rozbruch SR, Ilizarov S (2007) Limb lengthening surgery. Informa Health Care, New York/London