

1

History, Physiology, Modality Options, and Safety for Diagnostic Imaging of the Oral Cavity

Brenda L. Mulherin

Lloyd Veterinary Medical Center, Iowa State University College of Veterinary Medicine, Ames, IA, USA

CONTENTS

History of Diagnostic Imaging, 1
Philosophy of Diagnostic Imaging, 2
Radiographic Indications, 3
Intraoral Dental Radiographic Equipment, 3
Radiographic Imaging, 7
Radiographic Densities, 9
Digital Image Creation, 10
Advanced Imaging Modalities, 10
Definitions Relating to Imaging Modalities, 13
Computed Tomography Window Width and Window Level, 14
Other Common Viewing Windows, 16
Radiation Safety, 16
Radiation Safety Equipment Inspection 17
References, 20

History of Diagnostic Imaging

Discovery of X-rays

8 November 1895 was the extraordinary discovery of Roentgen rays, otherwise known as X-rays [1, 2]. X-rays were discovered by a German physicist named Wilhelm Conrad Roentgen (Figure 1.1). Roentgen published a paper regarding this unique discovery entitled “On a new kind of rays” in *Sitzungsberichte der Wurzburger Physik.-Medic.-Gesellschaft*. on 28 December 1895 [1, 2]. This date is now considered the true discovery of X-rays [2]. In Roentgen’s research, his wife Bertha Roentgen assisted in acquiring the first radiographic image of the human body [3]. She placed her hand on the photographic plate, and the X-ray beam was applied to her hand. This experiment yielded the first X-ray image of the bones and soft tissue of Bertha’s hand and her wedding ring [3] (Figure 1.2). Interestingly, during the days of research in his laboratory, Roentgen did not know what kind of radiation he was experimenting with, so he referred to the waves as X-rays, which is how

they are still known today [2]. Early in the discovery of radiology, most of the radiographic images produced were taken and created by photographers, or medical experts who had interest in photography [4].

Developing of Safety Measures

Following the discovery of X-rays, Nikola Tesla tried to develop a protection shield from what he perceived the harm that could come from X-ray exposure [2]. Tesla suggested that by placing an aluminum plate between the object of interest and the X-rays, there would be a reduction in the amount of X-ray energy received, hence the concept of the inverse square law [2].

Shortening of Exposure Time

Historically, X-ray energy was continuously emitted to the object of interest anywhere from 15 to 60 minutes at a time. In 1896, Professor Mihajo Idvorski Pupin from Columbia University, also known as Michael Pupin, tried to find a



Figure 1.1 William Conrad Roentgen, the German physicist who first discovered X-rays. *Source:* Courtesy of John Wiley & Sons.

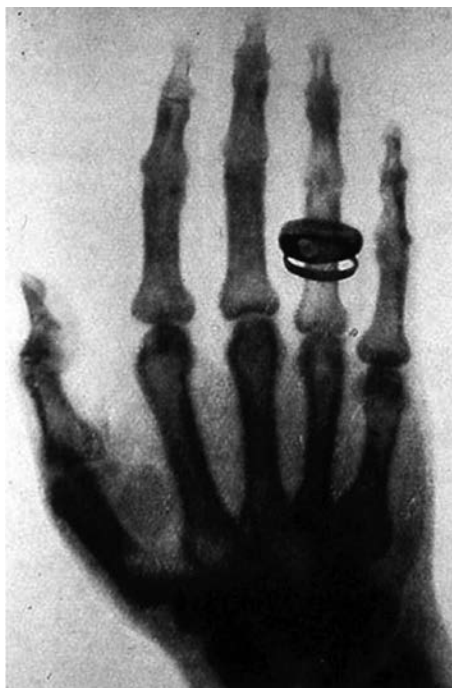

Figure 1.2 The first X-ray image of the bones and soft tissue of the hand of Bertha Roentgen. *Source:* Courtesy of John Wiley & Sons.

way to shorten the exposure time required to acquire an image [2, 4]. He placed a photographic plate behind a fluorescent screen and then applied the X-ray energy to the object of interest to create an image on the film [2, 4]. This was found to reduce the exposure time to only a few seconds [2, 4].

Glass Plates to Film

In 1896, Carl Schleusner manufactured the first glass plates to be used for radiographic image creation [4]. At the time, radiographs that were taken on glass plates were thought to be superior to those taken on film [4]. In 1914, during World War I, glass plates needed to be replaced with film as the glass needed to create the radiographic plates was manufactured in Belgium [4]. Due to the war, the supply of glass decreased, while the demand for radiographic images increased. In 1918, the first radiographic film was produced with high-speed emulsion on both sides, reducing radiation exposure and exposure times [4]. By the 1940s, non-screen radiograph film was introduced, and automatic film processors were becoming available [4].

Progression to Digital

Since the 1980s, digital radiography (DR) has slowly been replacing film in many hospitals and practices [5]. DR was quickly accepted into the veterinary profession as the speed of digital acquisition and ability to read images at computer terminals throughout the hospital allow for efficient interpretation and maximization of patient care.

The main difference between using conventional radiographic film and a digital system is in the viewing of the images. Digital radiographic images are electronically captured and viewed at a computer terminal, whereas conventional radiographic film is viewed with an illuminated view box. Transitioning to digital has significant benefits for diagnostic evaluation compared to conventional radiography. Digital systems allow a radiologist, specialist, or practitioner to evaluate images remotely. It allows for simpler storage, organization, and an easier way to compare images. Many advanced imaging methods including computed tomography (CT), magnetic resonance imaging (MRI), ultrasound, and cone beam computed tomography (CBCT) allow imaging of the body in such detail that 3D reconstructions of organs can be made. This helps to prepare the surgeon in advance for a procedure. Over the years, the application of radiation for visualization within a patient's body without surgical exploration has changed the field of medicine. These different imaging modalities have revolutionized the diagnostic field of medicine [2].

Philosophy of Diagnostic Imaging

Choosing the Appropriate Modality

It is the responsibility of the clinician to choose the imaging modality appropriate to gather the most information possible bearing in mind modality availability, ability for swift

interpretation, patient stability, and any financial considerations an owner may have. Ideally, a clinician will choose the imaging modality that is the most cost-effective and readily available yet yielding the necessary information to make a diagnosis. Radiographic imaging is of no use if the images created cannot be accurately interpreted by the clinician or at the very least, quickly distributed to an outside source that can interpret the images in an expedited manner.

Ability to Interpret Findings

The ability to interpret diagnostic images is based on the ability to interpret shadows. A comprehensive grasp of anatomy and the interaction of radiation with different structure densities is imperative to be able to evaluate areas of the body for disease conditions. Unfortunately, not everything is black and white when attempting to interpret radiographic images. Variations in patient confirmation and ranges of normal within the same species can lead the interpreter to difficulties of identifying normal from abnormal even within the same patient.

Diagnostic imaging can allow the clinician to survey an organ system, assess trauma, explore an area for a suspected neoplastic process, or allow for patient follow-up in monitoring disease progression or therapeutic effectiveness. There are many different imaging modalities that can be used to create a diagnostic picture of a specific area of interest. Each modality has its own advantages and disadvantages to their use. It is up to the clinician to decide which imaging modality is best suited to provide the diagnostic picture of what question they would like to answer. Regardless of the modality used to acquire diagnostic images, any findings should be interpreted based on a thorough examination of the patient and how those findings relate to an anesthetized oral examination and the patient's presenting complaint.

Radiographic Indications

Documentation of Disease

Dental radiographic imaging can document the amount of disease that is present within the oral cavity. It can be used to estimate the amount of bone loss that has occurred, evaluate for evidence of endodontic disease and any embedded teeth, or retained tooth roots that may be present, among other things [6].

Value of Full-Mouth Radiography

Taking full-mouth radiographs of canine and feline patients is included in the American Animal Hospital Association Guidelines regarding the dental care for dogs

and cats [7]. Full-mouth radiography is defined as a series of images taken of the teeth and bone of the jaw, both dentulous and edentulous portions [6]. The main reason full-mouth radiographs are taken is to establish a baseline to monitor for disease progression as well as determine if there is any existing disease or abnormalities present within the mouth prior to treatment.

American Animal Hospital Association Guidelines Regarding Dental Radiography

According to the most recent American Animal Hospital Association Guidelines relating to dental radiography, a person evaluating the oral cavity can underestimate the presence of disease when only examining a conscious patient compared to when intraoral radiographs are taken [7]. When intraoral radiographs are taken and combined with the oral examination findings, the examiner can only then assess the full extent of disease or any oral pathology present within an oral cavity [7]. While the ability to take intraoral radiographs is important, what is more imperative is that the practitioner has gained the knowledge and skills to interpret the radiographic findings associated with the radiographs. The American Animal Hospital Association Guidelines recommend that all dental patients receive full-mouth intraoral dental radiographs [7].

Intraoral Dental Radiographic Equipment

Generators

Dental generators come in a variety of forms. There are wall-mounted units, handheld units, and rolling units. The main difference between a dental X-ray unit and a standard radiographic unit is that the standard radiograph unit, milliamperes, kilovolts, and exposure time can be adjusted in any combination to create a diagnostic image. In a dental X-ray unit, the milliamperes and kilovolts are usually preset and are not able to be adjusted. Generally, the kilovoltage is fixed at 70–90 kVp, and the milliamperage is fixed at 10–15 mA. The only adjustment available is exposure time. Exposure time is usually displayed in impulses or seconds on the unit. Some units are designed to be preprogrammed according to the type of tooth to be radiographed or based on the size of the patient that is being radiographed: small, medium, or large.

Viewing a radiographic image depends on the size of the tube head and focal spot of the generator, in essence, the amount of radiation collimation. The smaller the focal spot, the better the image detail [8]. The distance the area

of interest is from the focal spot created by the generator is directly related to the magnification and detail of the image [8]. The closer the area of interest is to the film, the more improved image clarity as well as a lesser amount of distortion and magnification [8]. The area of interest should be as close to the film as possible to create the best image [8].

Wall-Mounted Units

Wall-mounted units are the most frequently used generators for procuring dental radiographs. Units attached to a stationary surface allow the arm to be positioned and left to procure the image without the operator being near the radiographic beam. These radiographic tube heads can be easily positioned. Frequently, they can be purchased secondhand from human dental operatories. Wall-mounted units have less drift of the positioning arm allowing for better image quality. A unit that is attached to the wall does have the limitation of being stationary and unable to be transported to a separate room if needed. For many dental procedures, there is a dedicated wet table associated with a wall-mounted unit to have the patient in proximity of the radiographic generator (Figure 1.3).

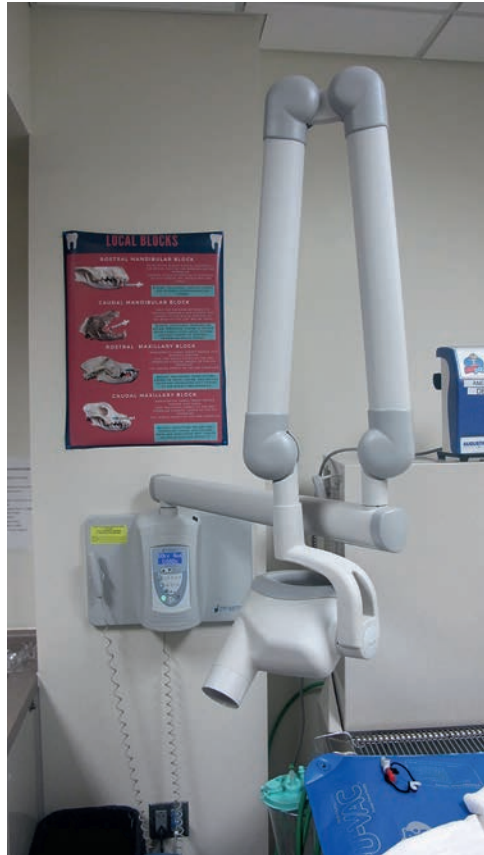

Figure 1.3 Wall-mounted radiographic generator.

Handheld Units

Handheld X-ray generators are battery-powered units that produce intraoral radiographs that can be easily transported between multiple rooms. They are compatible with digital sensors, standard film, and phosphor plates. Handheld units have an internal shielding from radiation and a scatter shield to protect the operator from direct and scattered radiation. Procuring images from a handheld unit takes practice as the positioning is based on the height, strength, and stability of the operator. Many of these units can weigh 8–10 pounds. This can cause fatigue of the operator as they are holding the unit for radiographic acquisition. When images need to be repeated, it may be difficult to reposition the unit to acquire a similar or improved image (Figure 1.4a and b).

Mobile Units/Caster-Mounted Units

Generators that are moveable can be of great benefit to the operator. These units can be moved from room to room. These units have the structure of a wall-mounted unit, with the freedom to move the generator to a different room. Depending on the unit, issues with stability have occurred with the units being disproportionally weighted, leaving them in danger of toppling over. Difficulty in being able to position the unit close enough to the patient to acquire an image may be encountered depending on the arrangement of the room and table. This is because the base of the unit needs to be positioned near or under a table to have appropriate access and positioning to the patient. This type of generator can be cumbersome and potentially a safety threat as the stabilization legs can be a tripping hazard (Figure 1.5).

Film

A dental generator needs to have some form of film to be able to release the photons against. There are three main types of film: standard film, indirect plates, and direct plates. As shown in Table 1.1, there are various film sizes that can be used which are adapted from human patients. Each type of film has specific sizes that are available to use with the generator. The flexibility of standard physical film and indirect plates allows them to be easily placed within the oral cavity of the patient to take an image. Direct plates are rigid and cannot be easily manipulated. Most commonly, intraoral radiographs for canine and feline patients use a Size 2 film. This size appears to be adequate for most small animal veterinary patients. A Size 4 film is helpful in larger breed dogs as it allows the operator to image more than one to two teeth at a time. It also allows the operator to procure an image of the whole tooth in one image rather than in multiple images for larger teeth, such as the canine tooth.




Figure 1.4 (a) Handheld radiographic generator. (b) A handheld radiographic generator has an internal radiation shielding and a scatter shield to protect the operator from radiation exposure. *Source:* Courtesy of Christopher J. Snyder, DVM, DAVDC, Founding Fellow, AVDC Oral and Maxillofacial Surgery, University of Wisconsin-Madison, School of Veterinary Medicine.

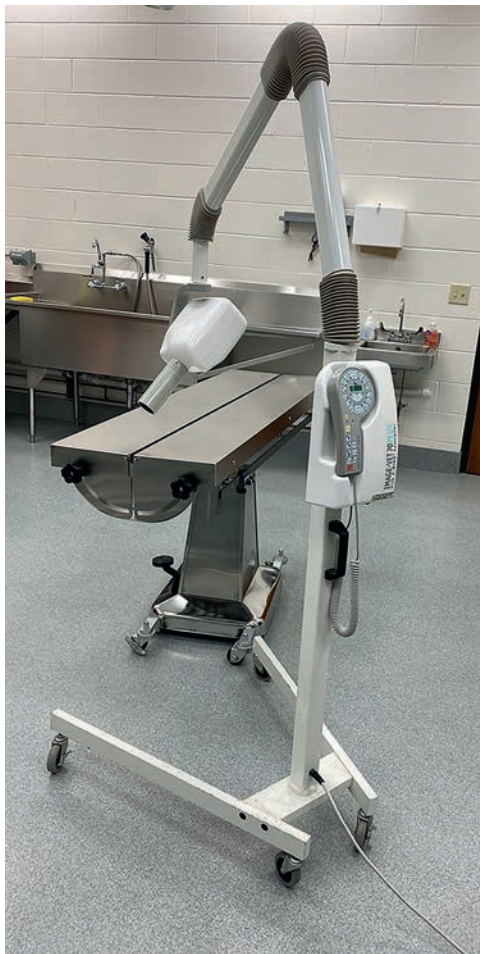

Figure 1.5 Castor-mounted radiographic generator. *Source:* Courtesy of Christopher J. Snyder, DVM, DAVDC, Founding Fellow, AVDC Oral and Maxillofacial Surgery, University of Wisconsin-Madison, School of Veterinary Medicine.

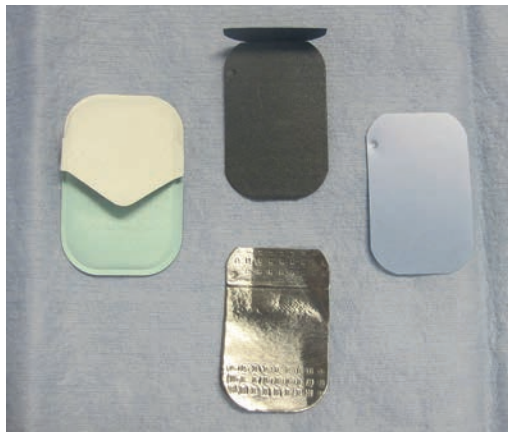
Standard Film

Standard film is tightly wrapped to avoid exposing the film itself to moisture or light. The sheet of unexposed film is wrapped in a black paper envelope. There is a lead foil sheet that protects the film from secondary radiation exposure. It is placed on the side of the film that is positioned farthest away from the generator (Figure 1.6). Since standard dental film is too small to be able to mark patient identity and medical record information, there is a “dimple” in the corner of the film to help the interpreter with orientation once the film has been exposed. The “dimple” has a concave or convex surface, depending on how you are looking at it. A concave shape curves inward, while a convex shape curves outward (Figure 1.7a and b). For proper orientation, the convex surface of the dimple should always be positioned toward the dental generator during exposure. Standard intraoral film comes in five sizes: 0, 1, 2, 3, and 4. Most commonly in veterinary patients, Sizes 0, 2, and 4 are employed for procuring oral diagnostic images [9].

Standard radiographic film can be developed either manually or with an automatic processor. Dental film can be attached to a larger film and run through an automatic processor or can be developed using a chairside developer. Automatic processors have been created to process dental film that is fully fixed and air-dried. When film is hand-processed, it is performed in four steps: developing, rinsing, fixing, and washing (Figure 1.8a and b). Using rapid processing solutions will allow the radiographic film to be processed within 90 seconds. Traditional light boxes can be used to view the films after they are processed. Due to the decreased size of the film compared to standard

Table 1.1 Table depicting the differences between the three most common types of radiographic film: standard, computed radiography (indirect) and direct digital radiography (direct) plates.

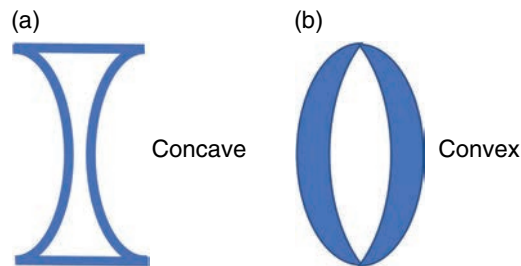
Type of film	Sizes	Chemicals	Speed of processing	Plate rigidity	Cost of replacement	Ease of retake image acquisition
Standard	0, 1, 2, 3, 4	Yes	5 min	Flexible	\$	Moderate
Computed radiography (indirect plate)	0, 1, 2, 3, 4	No	1–2 min	Flexible	\$\$	Moderate
Direct digital radiography (direct plate)	0, 2	No	3–5 seconds	Rigid	\$\$\$	Easiest

**Figure 1.6** Image of standard radiographic film opened to expose the contents. Standard film is wrapped to avoid exposure to moisture and light. The sheet of unexposed film is wrapped in a black paper envelope. There is a lead foil sheet that protects the film from secondary exposure.

radiographs, smaller viewers are utilized in most practices. Due to the nuances and limitations of this type of film, its use in veterinary medicine is obsolete and rarely used.

Digital Image Acquisition

There are two main types of digital radiographic acquisition systems: computed radiography (CR) and direct digital radiography (DDR) systems. Conventional radiographic generators or specific dental radiographic generators can be used with either system. The main difference between the two different acquisition systems lies in the film that is used. The CR system uses a physical flexible imaging plate, and the DDR system uses a rigid sensor or radiographic recording device. Digital acquisition systems should produce an image of diagnostic quality and have similar or less radiation exposure as to what is needed for standard dental film [10]. They should also be compatible with most conventional X-ray generators, have their information processed like any other formatted digital imaging and communications in medicine (DICOM) image, and be able to be processed in a timely manner [10].

**Figure 1.7** (a) An indentation, or “dimple,” is present on standard radiographic film to help the reader interpret orientation of the image. If the “dimple” is positioned so that it has an inward curve, the reader is looking at the concave surface. (b) If the “dimple” is positioned so that the surface curves outward, the reader is looking at the convex surface. The convex surface should always be positioned toward the generator during exposure, point to point.

Computed Radiography (CR) Photostimulable Phosphor (PSP) Plates (Indirect Plates)

This method of obtaining an intraoral radiograph involves taking the image on a phosphor plate and then transferring the image to a computer to be interpreted. Older photostimulable plates must be erased before taking an additional image, or the operator risks superimposition of multiple images on the same plate. Most photostimulable phosphor (PSP) plate systems now automatically erase the image from the system after transferring the previous image to the computer. The time from radiation exposure to digital image interpretation for the PSP systems can range from a few seconds to a few minutes depending on the system. There are five common phosphor plate sizes used for dental radiographic procurement: 0, 1, 2, 3, and 4. When cared for properly, most PSP plate systems can be used hundreds of times before they need to be replaced. The plates are thin and flexible and act like standard film, but with the benefit of being able to manipulate and store images digitally on a computer and reuse them multiple times (Figure 1.9). The main disadvantage of the CR system includes the increased anesthetic time required for retaking radiographic images due to the need to remove




Figure 1.8 (a) Image depicts a hand processing unit with the lid closed, protecting the processing fluids. (b) Image depicts the open hand processing unit showing the containers for the different solutions: developer, rinse, fixer, and rinse solutions. *Source:* Courtesy of Jill Medenwaldt, CVT, VTS-D, University of Wisconsin-Madison, School of Veterinary Medicine.

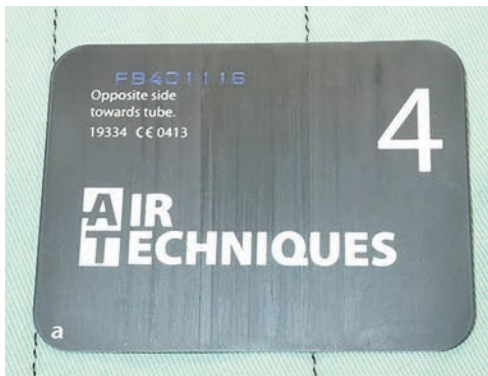

Figure 1.9 Computed radiography (CR) Size 4 image sensor: indirect plate. *Source:* Courtesy of Chad Lothamer, DVM, DAVDC, University of Tennessee College of Veterinary Medicine.

the plate from the oral cavity to process the image. Advantages of this system include the cost to replace the plate if it becomes damaged and the increased selection of plate sizes compared to the DR system.

Digital Radiography (DR) Image Sensors (Direct Plates)

Most direct digital sensors consist of either a charge-coupled device (CCD) or a complementary metal oxide semiconductor (CMOS) which is sensitive to light [9]. These sensors also have a scintillator layer which converts X-ray energy into light to create an image [9]. The sensors are directly connected to a computer to process the information to create an image within a few seconds (Figure 1.10a and b). This type of radiographic plate requires less radiation and is the most efficient of the intraoral dental radiography imaging modalities to

acquire the images. Positioning is easier with these units because the sensor does not need to leave the oral cavity to acquire and process an image. The main disadvantages of a direct system are the sensor size and its durability. The largest size currently available for a digital sensor is a Size 2. Direct plates are rigid and directly attached to the computer. If they are dropped, bitten, or bent, this will adversely affect the sensor and the radiographic image, potentially necessitating replacement of the sensor, which can be costly (Figure 1.11a and b). The benefits of a direct system are the speed of image acquisition and easier ability to retake images if there are positional alterations that need to be made or artifacts appearing on the image.

Similarities of Indirect and Direct Plates

Both direct and indirect digital plate images can be altered on the computer for underexposure or overexposure. Images from both systems can be manipulated to magnify an area of interest. The images are also easily transferred digitally to another clinician for interpretation or to the clients through a computer.

Radiographic Imaging

Basic Unit of an X-ray

The basic component of an X-ray is composed of photon energy [11]. This is expressed as a unit of energy called the electron volt (eV). X-rays are a form of radiant energy that has a short wavelength and is capable of penetrating hard




Figure 1.10 (a) Image depicts the DR system (direct radiography) plate which is attached directly to the computer. (b) A Size 2 sensor wrapped in its storage container. This sensor is in a sleeve which is changed out between uses to keep the sensor clean and to avoid cross-contamination of saliva and other fluids between patients.

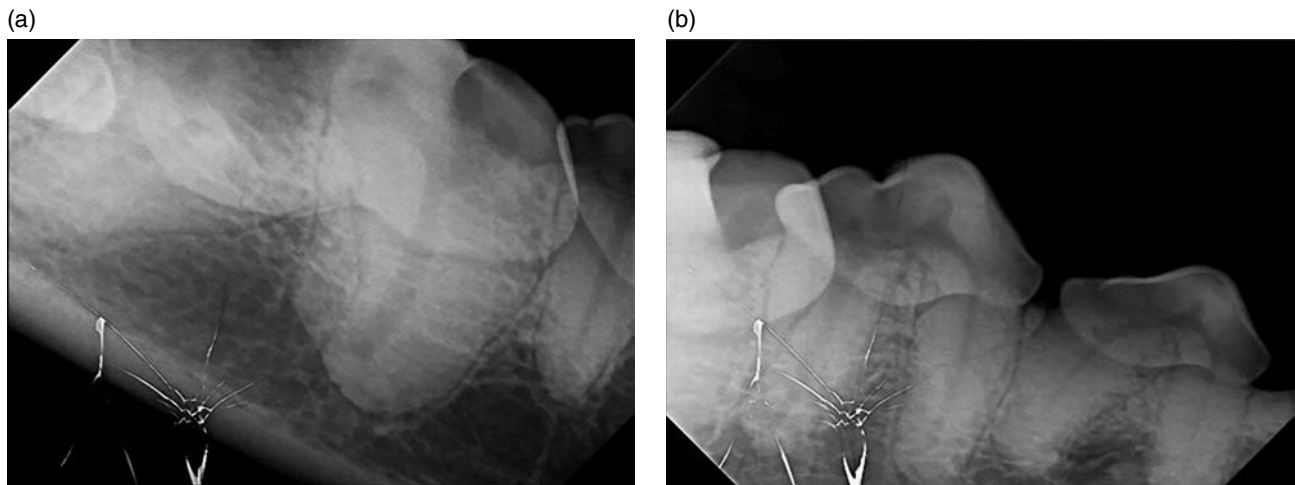


Figure 1.11 (a) Foreshortened image of the right mandible of a canine patient. The white spiderweb appearance on the sensor is damage to the direct plate. (b) Foreshortened image of the right mandible of the same patient. The radiographic image also depicts not including at least 2 mm of the apex of the root, for a diagnostic image. The white spiderweb appearance depicts damage to the sensor, making it difficult to interpret the radiographic findings.

and soft tissues alike [8]. Photons are either absorbed through tissues or pass through the tissues with minimal interference to expose an X-ray film. An X-ray is produced when electrons moving at a high rate of speed interact with a suitable material. During the interaction, as the electrons hit the material, they are either slowed down, change their direction, or are completely absorbed by the material. The energy is converted into heat and X-rays to produce an image. The radiographic tube head, or generator, is designed to direct these interactions and control this process.

Milliamperes (mA), Kilovoltage Peak (kVp), and Exposure Time

When looking at a standard X-ray generator, there are usually three controls that can be adjusted: mA, kVp, and exposure time (Figure 1.12).

mA control stands for milliamperes of energy released. This controls the number of electrons that are freed from the filament and ultimately the number of X-rays that are produced and measured per second. The number of X-rays



Figure 1.12 Image of a standard radiographic generator. There are three controls that can be adjusted: milliamperes (mA), kilovoltage peak (kVp), and exposure time.

produced is directly proportional to the number of electrons released. Therefore, the higher the mA, the larger the number of electrons released. Milliamperage-second controls the quantity of X-rays that are emitted.

kVp or kilovoltage peak is the amount of voltage that is applied across the radiographic tube head. It is referred to as the speed at which the electrons travel to the target. The higher the kVp, the more rapid the travel of the electrons and the more kinetic energy or heat is created. kVp controls the quality of the X-ray beam (wavelength).

Exposure time controls the duration of time at which radiation is being emitted. The duration of exposure is directly correlated with the number of X-rays produced.

There is also a direct correlation between the mA and seconds in that the result of the mA and the exposure time is equivalent to the number of X-rays that are produced:

$$\begin{aligned} \text{mA} (\# / \text{seconds}) \times \text{time} (\text{seconds}) \\ = \text{mAs} (\text{total number of X-rays}) \end{aligned}$$

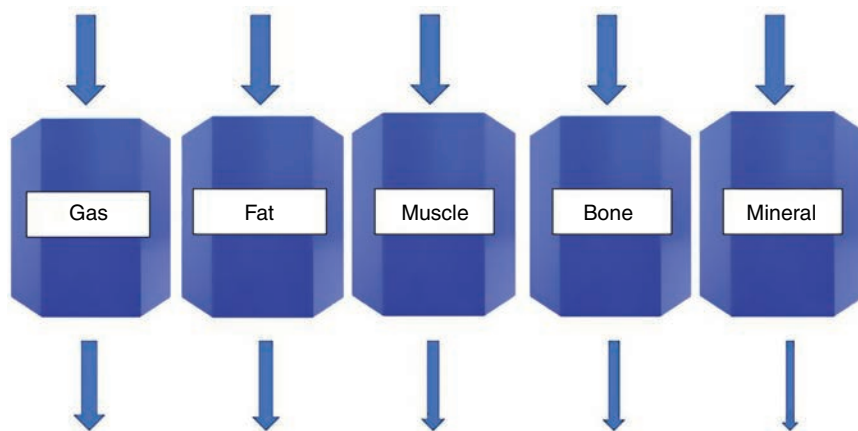
Radiographic Densities

When describing radiographic density, the interpreter needs to be able to describe the degree of opacity of the tissues. There are five different radiographic opacities that can be observed based on the density of the material [8]. The materials that produce different opacities are gas, fat, muscle, bone, and mineral [8] (Figure 1.13). The density of air allows most of the radiographic electrons to pass freely to the film causing an increased exposure, therefore increasing the blackness of a film [8]. Alternatively, the density of bone and mineral will absorb more electrons creating a further radiopaque shadow on the film [8]. Overall, thicker tissues will reduce the number of X-rays that ultimately reach the film compared to thinner tissues.

Radiopaque

Radiopaque is used to describe the degree of whiteness on a radiographic image. The degree of whiteness depends on the density of the area of interest. The denser the area, the more the X-ray beams are absorbed. The terms increased or decreased opacity can also be used to describe the degree of opaqueness of the material. The degree of opacity should be used to describe the organ or structure in relation to what the structure should look like under normal circumstances (Figure 1.14).

Figure 1.13 Illustration of radiographic densities. Gas allows the majority of radiographic electrons to pass freely to the film, followed by fat and then muscle. Bone and mineral will absorb more electrons creating a radiopaque shadow on the film.



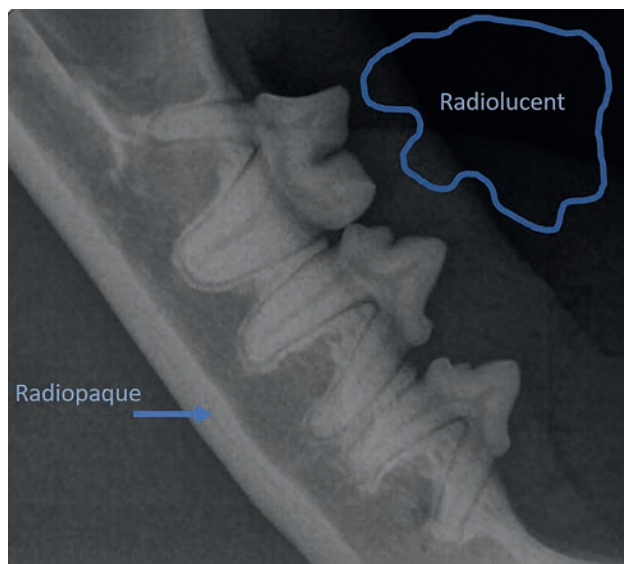


Figure 1.14 Radiograph of a normal right mandible of a feline patient. Radiopaque is used to describe the degree of whiteness of an image, and radiolucent is used to describe the degree of blackness of an image. The denser the area, the more radiopaque or white the structure is on the radiograph, the less dense the area, the more radiolucent or black the structure is.

Radiolucent

Radiolucent is used to describe the degree of blackness on a radiographic image. The degree of blackness depends on the lack of density of the area. Radiolucent objects do not absorb a significant amount of radiographic energy, rather the beams of radiation pass through the object unrestricted. Again, a change in the radiolucency of an object should be interpreted in relation to what the organ or structure should look like under normal circumstances.

Tissues that have a greater thickness will absorb more photons than thinner tissues. The greater the tissue absorption, the fewer the number of photons that expose the film and hence the more radiopaque the image is created on the film (see Figure 1.13).

Digital Image Creation

Creation of a Digital Image

The creation of a digital radiographic images involves three steps: a measurement of the transmission of the pattern of radiation emitted to the patient, converting the measurement into a digital format, and viewing the processed digital information with a computer [10].

Digital Imaging and Communications in Medicine Format (DICOM)

A digital file used in medical imaging is a DICOM file. This stands for Digital Imaging and Communications in Medicine format. Most DICOM files are in a standard format to allow different computer hardware and programs to be able to create and produce an image [10]. DICOM images can be transferred outside of the generating clinic for interpretation by sending through a web-based program [10]. The interpreter usually downloads the program along with the digital image information to allow the viewer to see and interpret the images [10]. DICOM files can be stored within an electronic repository to help manage all radiographic imaging modalities. When digital storage systems are utilized with a picture archiving system (PACS), transferring information between practitioners can be seamless.

Pixels

A digital image is composed of pixels. Radiographic imaging is an exercise in interpreting shades of gray. Each pixel is attached to a specific shade of gray. The greater the number of pixels, the larger the file size. The size of the pixel relates to the spatial resolution of an image [10]. This relates to the clarity and detail of an image. The computer program and hardware system determine the size of pixels as it arranges and assigns them to the digital radiographic image [10]. As a general statement, the more pixels an image has, the better the image quality, but at some point, the quality cannot be improved by increasing the number of pixels.

Advanced Imaging Modalities

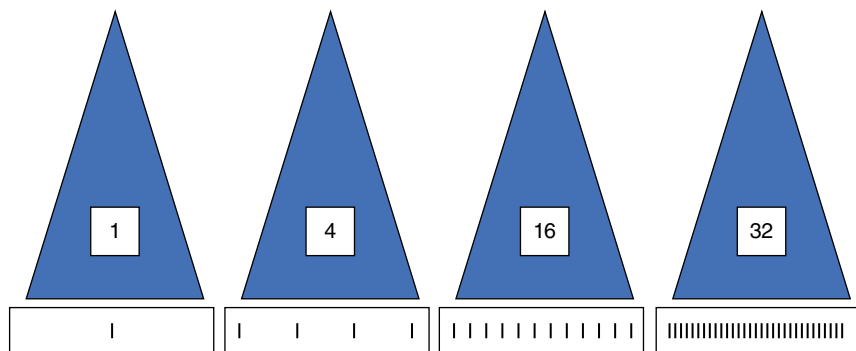
Computed Tomography

The imaging modality of CT (Figure 1.15) is commonly used for the evaluation of the brain, sinus and nasal cavities, orbit, mediastinum, lung, liver, adrenal glands, elbow joint, and spine [12]. This imaging modality creates a cross-sectional reconstruction of the area of interest through ionizing radiation from an X-ray tube. A fan-shaped collimated beam of radiation is generated on one side of a patient, and multiple detectors on the opposite side of the patient measure the amount of radiation transmission through the tissue slice from the patient [12]. The density of the tissue depicts how much radiation is passed through the tissue compared to how much the radiation is absorbed. For example, gas allows radiation to pass through unobstructed. The amount of radiation passing through gas at

Figure 1.15 Computed tomography unit.

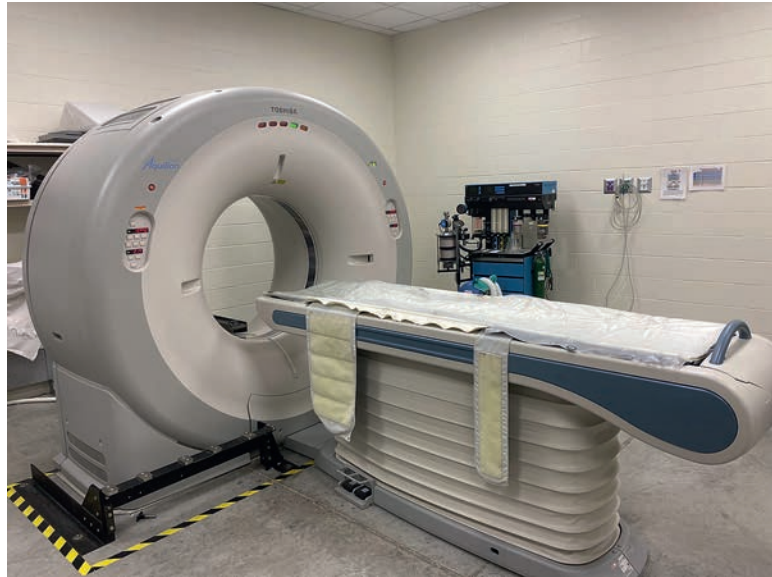

Figure 1.16 Illustration of the information gathering capacity of a multislice computed tomography unit. Increasing the number of slices a computed tomography unit can collect will increase the amount of information gathered to create a more detailed reconstruction.



the beginning is similar to the amount of radiation at the end of the emission. In contrast, if the same beam of radiation passes through mineral or bone, the density of these materials is far greater than gas. Therefore, more radiation is absorbed by these structures, and the amount of radiation present at the end of the emission is far less than when radiation was first emitted.

Increasing the number of slices a CT unit can collect will increase the amount of information gathered about an area of interest. The more information gathered can help create more detail of the reconstructed area (Figure 1.16). It is thought that with an increased slice thickness, there is a reduced diagnostic quality of the images created and there is an increased amount of image noise which can lead to distortion of the image [13]. The more the slices collected, hence the smaller the slice thickness, the better the detail of the area of interest as more information can be gathered with multiple slices. Currently, tissue thickness can be from 0.5 to 10 mm and usually takes only a few seconds to acquire an image. Currently, a 3-mm slice

thickness is thought to produce the best diagnostic quality and as well as the least amount of image distortion [13]. As the unit rotates around the patient, multiple measurements are taken from various directions to create a reconstructed image of the area of interest. The massive amount of data collected from the multiple images recreates the desired area of interest. The smaller the slice thickness, the larger the volume of data collected. There is significantly superior differentiation of soft and hard tissues within the images, and the ability to produce images without superimposition of the overlying structures makes this a very good imaging modality.

Commonly, intravenous contrast agents are injected to help differentiate between lesions and the normal parenchyma of a tissue [12]. Contrast media can also aid in the vascular anatomy and patency of vessels within the area of interest [12]. Using a contrast agent can assist in visualizing defects in an area including hemorrhage and infection, as well as accumulation of the agent in abnormal tissues, potentially indicating neoplasia.

Spatial resolution is the ability of an imaging modality to differentiate between adjacent objects or structures. Spatial resolution for a CT image is dependent on the number of projections and the number of detectors [14]. The resolution of areas with low contrast is highly determined by the filtering ability of the X-ray beam [14]. When the X-ray beam is less filtered, the beam releases more radiation due to the tissues absorbing more radiation, producing a higher contrast image [14]. When the beam is more filtered, it reduces the radiation exposure but also results in images that are lower in contrast [14].

Cone Beam Computed Tomography (CBCT)

Advancement of dental radiographic imaging modalities has progressed to the use of CBCT (Figure 1.17a and b). The ability to generate a three-dimensional image to create a complete diagnostic picture is vital to a clinician's ability to treat a patient. Using a CBCT unit has shown superior image quality while still allowing for three-dimensional reconstruction of the structures within the orofacial region. A CBCT unit employs a radiographic source, image detector, computer, and a monitor to display the images created. It differs from a conventional CT unit by using cone beam geometry rather than a collimated beam. The detectors within the standard CT unit are arranged in rows while in CBCT flat panels or image intensifiers are used. The CBCT

rotates around the patient only once, collecting its volume of information on the flat panel detectors. The radiation source of the CBCT unit rotates synchronously to acquire a 360° depiction of the area of interest [15]. The standard CT unit rotates around the area of interest multiple times and collects information with multiple scans, while a CBCT rotates once, thus reducing the radiation exposure to the patient. The volume of raw data acquired by the CBCT unit is processed and reconstructed by computer software to be viewed on a display unit, similar to a conventional CT unit. Compared to a conventional multidetector unit, cone beam images have superior diagnostic quality in assessing anatomical structures [15]. CBCT technology allows for better spatial resolution allowing the interpreter to better differentiate subtle differences between objects that are next to each other, such as teeth and bone. Electrical requirements for these units are standard, and the investment costs for a CBCT unit are less than a conventional CT unit. CBCT technology offers three-dimensional imaging and superior image creation of the dentoalveolar structures at a lower cost than a conventional CT unit [15]. It also uses a similar radiation exposure to intraoral radiography, making it a very viable option for the clinician to use for diagnostic imaging of the oral cavity. CBCT is an excellent imaging modality for evaluating bone and teeth, but not soft tissues or potential neoplastic conditions. The contrast resolution of this modality makes it difficult to differentiate between

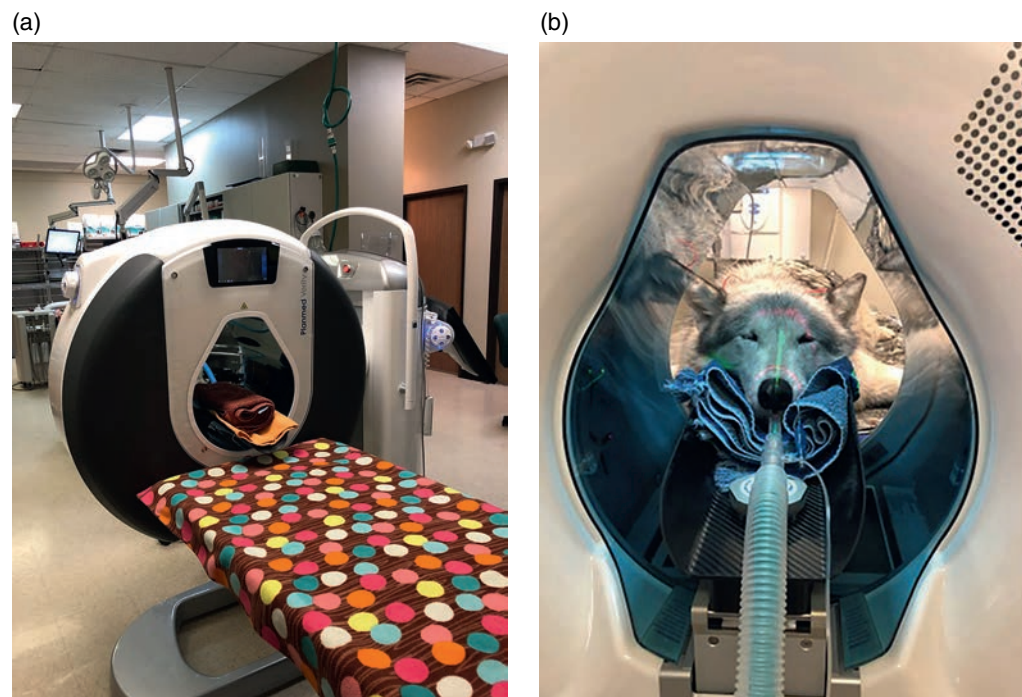


Figure 1.17 (a) Cone beam computed tomography unit. Photo courtesy of Scott MacGee, DVM, DAVDC, Companion Animal Dentistry of Kansas City. (b) Cone beam tomography unit with a canidae species in the scanner. *Source:* Courtesy of Scott MacGee, DVM, DAVDC, Companion Animal Dentistry of Kansas City.

slight changes in soft tissue structures, therefore making it a less desirable modality for evaluating neoplastic conditions. CBCT is an excellent imaging modality for evaluating periodontal disease, endodontic disease, and for tooth resorption in both canine and feline patients. It is also a good modality to evaluate maxillofacial trauma. CBCT has been shown to have superior diagnostic quality in comparison with dental radiographs for the evaluation of periodontal disease in brachycephalic breed dogs [16]. Using CBCT has also been shown to be very effective in evaluating patients for furcation exposure and intrabony defects [17]. Compared to intraoral radiographs, CBCT has been shown to be effective in the detection of apical lucencies as well, making it an excellent imaging modality for cases with suspected endodontic disease [18].

Magnetic Resonance Imaging

MRI is a diagnostic modality that uses magnetic fields and radio waves to create an image [12] (Figure 1.18). An MRI utilizes a high and low magnetic field and a coil to detect the frequency and signal created by changes in the cellular composition within an organ to produce an image which is viewed on a computer. Tissues within the body absorb and release energy in different ways and levels [12]. Water produces a high MR signal, while bone and collagenous tissues produce a low MR signal [12]. An MRI produces exceptional contrast and differentiation of the soft tissues of the body. This type of imaging modality does not use ionizing radiation.

When using this imaging modality, care needs to be taken to identify patients or operators who have ferromagnetic implants, foreign bodies, or other metallic devices or objects on or within their bodies. Examples of such items include bullets, vascular staples, shrapnel, or other objects containing metal. These items may travel through soft and hard tissues leading to additional injury. Items may also become potential projectiles within the MRI unit or the room due to the intense magnetic field that is created during the use of this imaging modality (Figure 1.19). More information regarding the use of MRI can be found in Chapter 10.

Definitions Relating to Imaging Modalities

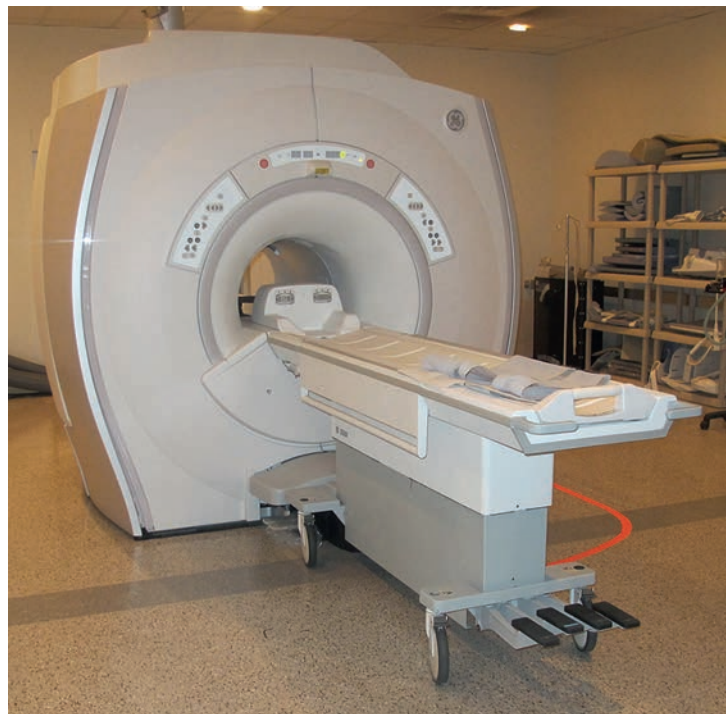Sagittal Plane

Sagittal plane divides the area of interest in a vertical plane. A sagittal plane divides the area into left and right halves. For veterinary patients, this is in a lengthwise plane from the tip of the nose to the tip of the tail from the right side to the left side (Figure 1.20). This plane is also called vertical plane parallel to the median plane.

Transverse Plane

Transverse plane divides the area of interest in a horizontal plane. A transverse plane divides the area into a top and bottom half for human patients. For veterinary patients,

Figure 1.18 Magnetic resonance imaging unit.



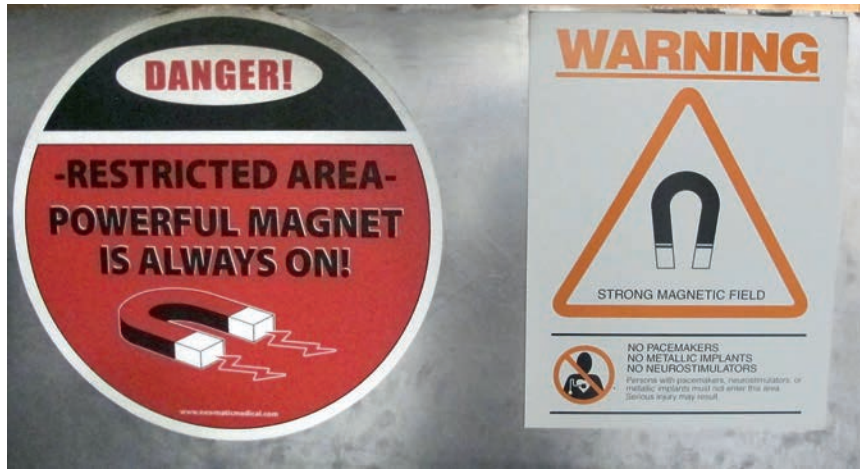

Figure 1.19 Image depicts warnings frequently found outside of a magnetic resonance imaging unit. Metallic objects can become projectiles within the unit due to the magnetic field created by this imaging modality.




Figure 1.20 Photograph depicts a sagittal plane. A sagittal plane divides the area of interest into right and left halves.

this is in a plane from the tip of the nose to the tip of the tail from the front to the back, like slicing a loaf of bread lengthwise (Figure 1.21). This plane is also called the axial plane.

Dorsal Plane

Dorsal plane divides the area of interest parallel to the spine. A dorsal plane divides the area parallel with the long axis of the body. This divides the body from the top of the skull lengthwise to the bottom of the toes, from top to bottom (see Figure 1.21). This plane is perpendicular to the sagittal and the transverse planes.

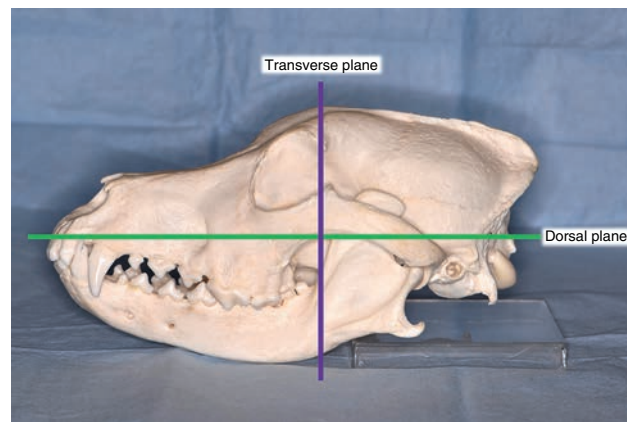


Figure 1.21 Photograph depicts the transverse and dorsal planes. A transverse plane divides the area of interest into a top and bottom half. A dorsal plane divides the area of interest parallel to the spine.

Computed Tomography Window Width and Window Level

CT images can be viewed by standard settings set by the computer program. How a study is viewed is dependent on the information collected from the CT unit and how it is windowed. Windowing is the process by which the different shades of gray are contrast-enhanced to produce an image. The different windows change the appearance of an image to highlight specific areas within the chosen location to feature particular structures. Proper windowing of a CT study can significantly impact the ability of a clinician to interpret the normal anatomy as well as any pathology that may be present. Therefore, prior to interpretation, the most appropriate window for the area of interest should be chosen.

Window Width

Window width measures the range of CT numbers. A CT number is directly related to the intensity of an X-ray beam as it travels through hard and soft tissues and its grayscale value. A grayscale value is assigned based on its brightness of a three-dimensional element or voxel, relative to water [19]. The range of CT numbers is displayed on the image as it is being interpreted. CT numbers are measured in Hounsfield units (HU). Images can be displayed with HU on a scale from -1000 to +3000 HU, for over 4000 different shades of gray [20] (Table 1.2). The HU value is based on the density of a tissue to absorb radiation from the X-ray beam. The scale is arbitrarily based on the premise that water is defined as being zero HU and air is defined as -1000 HU [21]. The higher the HU value, the denser the area. A HU that falls below the lowest value of the window width will show as black, and any value of window width above the highest HU value on the image will show white [19]. The human eye can only discern about 40 different shades of gray [21]; thus, using the most appropriate window for viewing the images is of utmost importance.

The wider the window width, the more CT numbers will be displayed causing the transition from dark to light to

occur over a larger transitional field. As the window width increases, a larger change in the density of the tissues will be needed to alter the change in HU or shade of gray. This will decrease the contrast of an image, and structures will be more likely to be viewed similarly, despite having different densities. Therefore, a larger window width will cause the interpreter to have difficulty discerning the different attenuations between similar density tissues, such as soft tissue.

A wide window width, e.g. >+1500, is better for evaluating areas with significantly different attenuating values, such as the lungs where air-filled structures are closely associated with fluid or blood-filled structures. A wide window width is also an excellent choice for evaluating bone.

A narrow window width, e.g. <+800 HU, is excellent when evaluating areas of similar attenuation, such as soft tissues. Decreasing the window width will create a greater increase in the contrast of an area. As the window width decreases, a significantly smaller change in a tissue's density will result in a change in the grayscale color on the image. This narrowing of the window width will allow similarly dense structures to have more obvious shades of white to gray to black assigned to allow the interpreter to visualize subtle differences in similarly dense tissues.

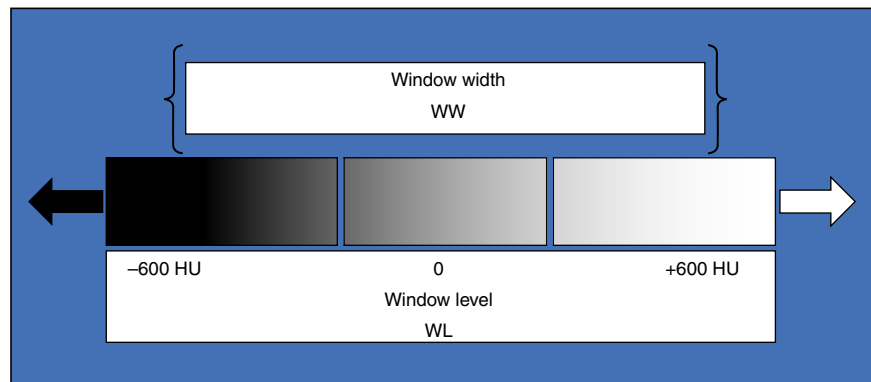
Table 1.2 Illustration of the grayscale value assigned to common gas and material densities related to their Hounsfield units assigned based on the gas or tissue's ability to absorb radiation.

Tissue type	Hounsfield unit
Bone	+400 to +1000 or higher
Soft tissue	+40 to +80
Water	0
Fat	-60 to -100
Lung	-400 to -600
Air	-1000

Window Level

The window level is often referred to as the window center. The window level is related to the midpoint of the CT numbers displayed on the image. It refers to the brightness and darkness of an image. Decreasing a window level will cause the image to be brighter and increasing the window level will cause the image to be darker (Figure 1.22). As the window level is increased, a higher HU value will be needed for a tissue density to be brighter or white, whereas decreasing the window level will require less HU for a tissue density to be displayed as bright or white.

Figure 1.22 Illustration of window width and window level. The window width determines the shades of gray or Hounsfield units of an image. The window level is related to the midpoint of the shades of gray. Window level refers to the brightness and darkness of an image.



Other Common Viewing Windows

Bone Window

A bone window is best used to view bone in detail and when trying to differentiate from the cortex and the medulla. It is usually set at a window width of 2000–3000 HU and a window level of around 1000 HU. A bone window helps to visualize subtle details within the bone [22]. Soft tissue structure detail is much less obvious due to the lack of density in these tissues [22]; therefore, the other modality windows should be considered when evaluating soft tissue structures. Evaluation of fine details such as mineralized areas or bony structures is better visualized with a bone window [22].

Soft Tissue Window

A soft tissue window is used to evaluate most organs. It is usually set at a window width of around 200–400 HU and a window level of 20–60 HU. However, it is not a good window for evaluating lung parenchyma, due to the density of this tissue being air-filled.

Radiation Safety

Radiation Safety Apparel

It has been found through the advancement of diagnostic imaging modalities that there is indeed some risk associated with exposing patients to ionizing radiation and intravenous contrast agents [23]. The development of radiation safety procedures began in the 1930s with the invention of lead aprons (Figure 1.23) and lead gloves [23] (Figure 1.24). In the years and decades that followed, advancement and production of thyroid shields (Figure 1.25) and leaded protective eyewear (Figure 1.26) have attempted to make using these radiation imaging modalities safer to the radiology technician [23].

Collimation

Utilizing collimation instruments to narrow the X-ray beams to reduce scatter radiation and increasing the speed of exposure were found to reduce excessive radiation exposure [23]. An X-ray beam is restricted by the amount of collimation that the radiographic tube head creates. Not focusing the collimation beam on the area of interest only will allow for more radiation to be released and expose the patient to unnecessary radiation. Most dental units have a very narrow beam of radiation released and do not have the ability to be collimated as the beam is already as narrow as possible to create a diagnostic image relating to the film size.




Figure 1.23 Lead aprons can be used to prevent scattered radiation exposure.



Figure 1.24 Lead gloves can be worn to prevent scattered radiation exposure to the extremities.



Figure 1.25 Thyroid shields can be worn to prevent scattered radiation exposure.



Figure 1.26 Lead glasses can be worn as part of the personal protective equipment to protect the radiology technician's eyes.

As Low As Reasonably Achievable (ALARA)

Exposure to ionizing radiation in any amount could induce side effects of radiation exposure. Minimizing the amount of radiation that a patient or operator is exposed to is imperative to avoid potentially fatal side effects (Figure 1.27). The guiding principle of radiation safety is to act in accordance with the principle of as low as reasonably achievable (ALARA) [24]. This principle is to create an environment

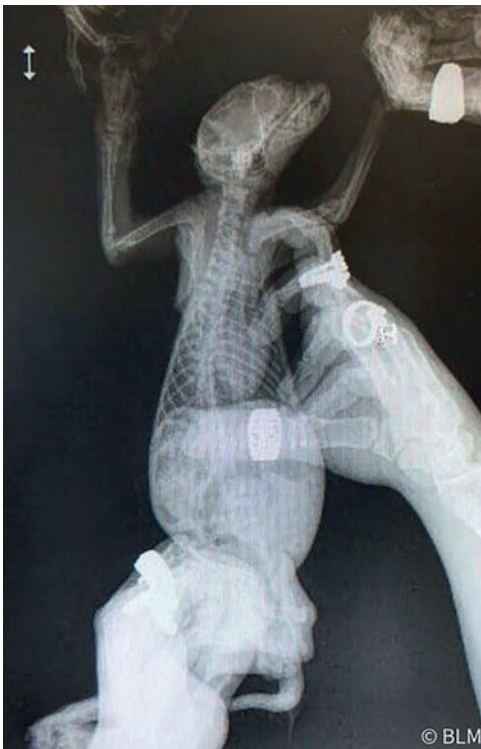

Figure 1.27 Image depicts poor radiation safety of the radiology technician. Minimizing the amount of radiation exposure to the patient and the operator is important to avoid potentially fatal side effects.

in which the radiation exposure is ALARA [24]. It is extremely important to increase the education and awareness of the effects of ionizing radiation to the patient and choose a diagnostic imaging modality that minimizes the amount of radiation exposure to all involved [24].

Time, Distance, and Shielding

There are three basic measures that you can apply to achieve the lowest amount of radiation delivered to the user as well as the patient. These measures include time, distance, and shielding [25].

Time

Minimizing the amount of time that is spent near a radiation source is imperative to help reduce radiation exposure. Time and exposure can be reduced with the use of sedation or anesthesia for better precision in positioning, as well as improved positioning for uncooperative patients. This reduces the need for retakes based on poor positioning. Fortunately, this is not usually an issue in dental radiographic procurement in veterinary patients as sedation or general anesthesia is required to generate the images.

Distance

Maximizing the amount of distance from the radiation source will thereby reduce the dose of radiation received. Distance and dose are inversely related, therefore increasing the distance from the radiation source will reduce the dosage of radiation received. The operator should try to stand at least 6 ft away from the radiographic tube head and at a 90–135° angle from the primary beam [7, 9].

Shielding

Placing something between the radiation source and the object being irradiated will reduce the radiation received by the object. Effective shielding is dependent on the source of radiation. Lead doors, shields, and tabletop barriers are available to help shield the operator from radiation exposure (Figure 1.28a and b).

Radiation Safety Equipment Inspection

Protective Apparel

The reduction in radiation exposure begins with the radiology technician wearing radiation protective equipment. Personal protective equipment such as lead aprons, lead shields, thyroid shields, radiation dosimeter, and lead gloves can be utilized to avoid scattered radiation exposure [7] (Figure 1.29).



Figure 1.28 (a) Lead doors can be used as protection against radiation exposure. Placing a shield between the radiation source and the radiology technician will help to reduce scatter radiation. This can be used in addition to personal protective equipment. (b) Lead shields can also be used for radiation protection.



Figure 1.29 Model demonstrating appropriate personal protective equipment: wearing a lead apron, thyroid shield, lead glasses, and lead gloves.

The operator needs to be protected from three sources of radiation: the primary beam, secondary radiation emitted from the patient, and finally leakage of radiation from the machine housing unit or radiographic tube head [7].

Contrary to popular belief, the use of lead shields and aprons is not to protect the patient or the operator from the primary beam of radiation. Their purpose is to prevent scattered radiation exposure. Personal protective equipment used for shielding against radiation exposure should be evaluated at least annually for signs of visible cracks, tears, and areas of wear [11, 26]. Radiation protective equipment can be damaged when stored inappropriately. All protective equipment should be stored properly to prevent cracks in the lead shielding, therefore decreasing its protectiveness [26] (Figure 1.30). Improperly stored equipment can lead to deterioration of the lead-impregnated vinyl [27]. Inspections of the radiation protective equipment are necessary for the health and safety of the radiology technicians as well as the patients, depending on what type of protection is being used [27]. The protective apparel should also be radiographed in any area that appears to have physical damage to reduce unexpected radiation exposure and verify the lead within the apparel is not damaged [26] (Figure 1.31). Monitoring parameters are also available to observe the levels of radiation in a specific area over time or a specific person over time (Figure 1.32a and b).

Care of Radiation Safety Equipment

Radiation protection equipment should be inspected before each use for signs of defects, tears, or creases in the lead. Lead aprons should be properly hung by the shoulders on a rack when not in use and not folded or crumpled on the floor [27]. All equipment should be kept clean and dry, attempting to keep it free of blood and other body fluids as well as away from sources of heat [27]. If the protective

equipment becomes soiled, refrain from cleaning with chemicals or putting the equipment in the laundry. It should only be spot-cleaned or hand-washed with mild soap and left to hang dry. If any equipment is found to be defective, it should be removed from service until it can be inspected for safety for continued use.




Figure 1.30 Image depicting appropriate storage of thyroid shields to prevent damage to the lead lining.

Radiation Safety Inspection Protocol

A radiation safety inspection protocol should be made for clinics utilizing any form of radiation. An individual or group of individuals should be identified to be responsible for the regular visual and radiographic inspection of all protective equipment. Protocols for conducting safety equipment inventory and inspection of the equipment should be done on a regular basis. Criteria for the replacement of any damaged equipment should be clear. Radiation protection equipment should be supplied for all staff members in appropriate numbers and sizes to fit the needs of all individuals at the clinic with potential exposure to radiation [27]. Individuals utilizing the protective equipment should have a contact person to notify them if there appears to be an issue with the fit or integrity of the equipment [27]. Radiation protective equipment should be marked with a unique identification system to refer to when evaluating



Figure 1.31 Lead aprons should be radiographed to evaluate for any cracks in the lead shielding and to verify there is no unexpected radiation exposure.

(a)



(b)



Figure 1.32 (a) Dosimeters are used to assess the amount of radiation for a given area or a specific person. This image depicts a single dosimeter for a given area. (b) Wall of dosimeters of individuals who may be exposed to radiation within a clinic setting.



Figure 1.33 (a) Personal protection equipment should be marked with individual identifiers when evaluating the protective equipment for its integrity. For example, unique identifiers can be stitched on the thyroid shields help to identify each shield. (b) A cattle identification marker was used to uniquely identify the lead aprons individually.

the integrity of the equipment [27] (Figure 1.33a and b). Different criteria can be used to identify whether the protective equipment may be defective or have decreased integrity. Some clinics may choose to examine their equipment with radiography or fluoroscopy, while others may only perform the initial visual inspection of the equipment

for any obvious defective areas. They are then again evaluated only when suspected to be defective. A written or computerized log of defects and need for replacement should be kept. Further guidance on radiation safety guidelines can be found by contacting the Joint Commission on Accreditation of Healthcare Organizations.

References

- 1 Roentgen, W.C. (1896). On a new kind of rays. *Nature* 53 (1369): 274–276.
- 2 Babic, R.R., Babic, G.S., Babic, S.R., and Babic, N.R. (2016). 120 years since the discovery of X-rays. *Med. Pregl.* 69 (9–10): 323–330.
- 3 Hubar, J.S. (2017). Part one: fundamentals: history: discovery of X-rays. In: *Fundamentals of Oral and Maxillofacial Radiology* (ed. J.S. Hubar), 32–42. New Jersey: Wiley.
- 4 Haus, A.G. and Cullinan, J.E. (1989). Screen film processing systems for medical radiography: a historical review. *RadioGraphics* 9 (6): 1203–1224.
- 5 Mattoon, J.S. (2006). Digital radiography. *Vet. Comp. Orthop. Traumatol.* 19: 123–132.
- 6 Verstraete, F.J., Kass, P.H., and Terpak, C.H. (1998). Diagnostic value of full mouth radiography in dogs. *Am. J. Vet. Res.* 59: 686–691.
- 7 Bellows, J., Berg, M.L., Dennis, S. et al. (2019). 2019 AAHA dental care guidelines for dogs and cats. *J. Am. Anim. Hosp. Assoc.* 55: 49–69.
- 8 Owens, J.M. and Biery, D.N. (1999). Principles of radiographic interpretation. In: *Radiographic Interpretation for the Small Animal Clinician*, 9–13. Baltimore: Williams & Wilkins.
- 9 Roy, C.G. (2018). Canine and feline dental radiographic technique. In: *Textbook of Veterinary Diagnostic Radiology*, 7e (ed. D.E. Thrall), 39–57. St. Louis: Elsevier.
- 10 Robertson, I.D. and Thrall, D.E. (2018). Digital radiographic imaging. In: *Textbook of Veterinary Diagnostic Radiology*, 7e (ed. D.E. Thrall), 23–38. St. Louis: Elsevier.
- 11 Thrall, D.E. and Widmer, W.R. (1998). Radiation physics, radiation protection, and darkroom theory. In: *Textbook of Veterinary Diagnostic Radiology*, 3e (ed. D.E. Thrall), 1–19. Philadelphia: W.B. Saunders.
- 12 Owens, J.M. and Biery, D.N. (1999). The scope of diagnostic imaging in small animal practice. In: *Radiographic Interpretation for the Small Animal Clinician*, 1–8. Baltimore: Williams & Wilkins.
- 13 Alshipli, M. and Kabir, N.A. (2017). Effect of slice thickness on image noise and diagnostic content of single-source-dual energy computed tomography. *J. Phys. Conf. Ser.* 851 (1): 1–6. <https://doi.org/10.1088/1742-6596/851/1/012005>.
- 14 Rogella, P., Kloeters, C., and Hein, P.A. (2009). CT technology overview: 64-slice and beyond. *Radiol. Clin. N. Am.* 47: 1–11. <https://doi.org/10.1016/j.rcl.2008.10.004>.

- 15 Soukup, J.S., Drees, R., Koenig, L.J. et al. (2015). Comparison of the diagnostic image quality of the canine maxillary dentoalveolar structures obtained by cone beam computed tomography and 64-multidetector row computed tomography. *J. Vet. Dent.* 32 (2): 80–86.
- 16 Doring, S., Arzi, B., Kass, P.H., and Verstraete, F.J. (2018). Evaluation of the diagnostic yield of dental radiography and cone-beam computed tomography for the identification of dental disorders in small to medium sized brachycephalic dogs. *Am. J. Vet. Res.* 79: 62–72.
- 17 Eshragi, V.T., Malloy, K.A., and Tahmasbi, M. (2019). Role of cone-beam computed tomography in the management of periodontal disease. *Dent. J.* 7 (57): 1–9. <https://doi.org/10.3390/dj7020057>.
- 18 de Paula-Silva, F.W.G., Santamaria, M., Leonardo, M.R. et al. (2009). Cone-beam computerized tomographic, radiographic, and histologic evaluation of periapical repair in dogs' post-endodontic treatment. *Oral Surg. Oral Med. Oral Pathol. Oral Radiol. Endod.* 108: 796–805.
- 19 Barnes, J.E. (1992). Characteristics and control of contrast in CT. *RadioGraphics* 12: 825–837.
- 20 d'Anjou, M.A. (2018). Principles of computed tomography and magnetic resonance imaging. In: *Textbook of Veterinary Diagnostic Radiology*, 7e (ed. D.E. Thrall), 71–95. St. Louis: Elsevier.
- 21 Frederiksen, N.L., White, S.C., and Pharoah, M.J. (2009). Advanced imaging. In: *Oral Radiology Principles and Interpretation*, 6e (ed. S.C. White and M.J. Pharoah), 207–224. St. Louis: Elsevier.
- 22 Xue, Z., Antani, S., Long, L.R. et al. (2012). Window classification of brain CT images in biomedical articles. In: *AMIA Annual Symposium Proceedings*, 1023–1029. National Library of Medicine, National Center for Biotechnology Information Epub 3 November 2012.
- 23 Scatliff, J.H. and Morris, P.J. (2014). From rontgen to magnetic resonance imaging: the history of medical imaging. *N. C. Med. J.* 75 (2): 111–113.
- 24 Atci, I.B., Yilmaz, H., Antar, V. et al. (2017). What do we know about ALARA? Is our knowledge sufficient about radiation safety? *J. Neurosurg.* 61: 597–602.
- 25 Cheon, B.K., Kim, C.L., Kim, K.R. et al. (2018). Radiation safety: a focus on lead aprons and thyroid shields in interventional pain management. *Korean J. Pain* 31 (4): 244–252.
- 26 Matsuda, M. and Suzuki, T. (2016). Evaluation of lead aprons and their maintenance and management at our hospital. *J. Anesth.* 30: 518–521.
- 27 Michel, R. and Zorn, M.J. (2002). Implementation of an X-ray radiation protective equipment inspection program. *Health Phys.* 82 (2 Suppl): 51–53.

