

Chapter

1

General Principles of Orthopaedic Clinical Examination

Oghor Obakponovwe, Stanley Jones and Fazal Ali

Summary of General Orthopaedic Examination Principles

1. Respect your patient and ensure that he or she is comfortable.
2. Give clear instructions on what you want the patient to do.
3. Expose the region to be examined fully yet maintain dignity.
4. Observe not only the region being examined but your patient as a whole.
5. Always compare both limbs.
6. When palpating a region remember to look at the patient's face for signs of pain or discomfort.
7. Assess both active and passive range of movement.
8. Examine the joint above and the joint below and perform a neurovascular assessment.
9. Special tests can be used to help elicit or confirm findings.
10. Do not cause pain.

Clinical examination is an art that has to be learnt, as it does not come naturally. Most clinicians refine their examination routine with experience and practice. All patients must be respected, made to feel at ease and assured of their confidentiality and dignity.

A detailed history should always be taken, followed by an appropriate clinical examination.

It is often assumed that clinical examination begins on the couch. This should not be the case, as significant information can be gained by observing the patient as they enter the room for a consultation or as you approach them.

Consider using a chaperone, especially if examining the shoulder, spine or hip. If the patient is seated, they should be asked to stand as this is usually the first part of any orthopaedic clinical examination, except when the hand is being examined. You will observe

whether the patient is tall, short, obese, thin, ill, well, energetic or lethargic. Observe if there is pain or if there are stigmata of orthopaedic disease such as blue sclera (osteogenesis imperfecta), café-au-lait spots (neurofibromatosis), multiple exostoses (diaphyseal aclasis, Figure 1.1) etc.

In addition to the patient's gait pattern, the presence of limb deformities, the use of walking aids and orthotic braces or prosthetic devices should also be noted. This is particularly relevant when examining the lower limbs and spine.

Examples of gait patterns include:

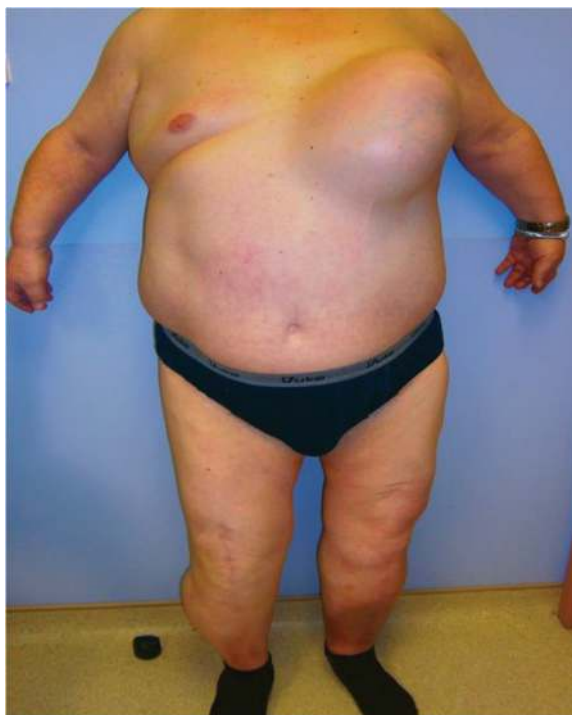

Figure 1.1 Patient with diaphyseal aclasis (hereditary multiple exostosis). Note the short limbs, bowing of the forearm, swellings around the knees and the large tumour in the left pectoral region.

General Principles of Orthopaedic Clinical Examination

- Antalgic gait caused by pain stemming from the sole of the foot to the hip. The stance phase of the affected limb is shortened, lessening the loading time of the painful limb.
- High stepping gait is seen in patients with hereditary sensorimotor neuropathy or those with a foot drop.
- Shuffling gait is typical of neurological conditions, such as Parkinson's disease, and frequently leads to an increased risk of falls secondary to loss of balance and coordination.

The clinical signs and associated deformities of some clinical conditions, e.g. hallux valgus, may be so characteristic that the diagnosis can be made without a full clinical examination. However, this is not always the case, and an examination carried out in a systematic manner not only instils confidence in the patient but also avoids missing important and salient clinical signs.

The system of *look, feel, move* advocated by Apley¹ is recommended, although when examining the wrist, elbow and foot and ankle *look, move, feel* is advised by the authors.

The part of the musculoskeletal system being examined must be suitably exposed; for example, when examining the shoulder, the patient should be undressed to the waist. The patient's sense of modesty should always be preserved. The use of a strapless garment or appropriate screen to cover sensitive areas should be practised and a chaperone considered for every examination. The patient must be given clear instructions on which clothes to take off. The ease or difficulty of undressing and any associated pain experienced whilst doing so are useful information that help in the assessment. In addition, it is advisable to expose both limbs for comparison even though only one limb may be affected.

Examination of paediatric patients requires skill and flexibility. Children are not small adults. Remember to look at the parents as the patient may be presenting with an inherited clinical condition. Involve the parents as much as possible. Useful information can be acquired by observing and adopting methods of play rather than using a rigid system of examination as previously suggested.

Equipment

The basic equipment required for orthopaedic examination includes a tape measure, goniometer and tendon hammer. In addition, a pen, key and coin are required for assessment of hand function (Figure 1.2).




Figure 1.2 Equipment required for examination.

Look

Inspection is an integral part of a physical examination. It begins the sequence and should always be undertaken before palpation and movement. It also forms an important part of palpation and movement.

It is important to look at the part being examined from different angles, e.g. the shoulder joint should be observed from the front, back and side and the axilla must also be inspected. Inspection of the foot is not complete without examining the sole and between the toes. Whilst observing a limb, any scars, skin colour changes, swelling, bruising, muscle wasting and alteration in shape or posture are noted. Skin colour changes may be the result of infection, vascular compromise or pain syndrome.

Scars may be the result of injury or previous surgery or infection and may be a clue to the underlying problem (Figure 1.3).

Swelling may be localised or diffuse. Localised swelling and its location with respect to the underlying anatomical structures usually give a clue as to the possible cause, e.g. a well-defined swelling in the radioulnar aspect of a wrist is likely to be a ganglion, and a swelling on the medial joint line of the knee is likely to be a meniscal cyst.

Diffuse swelling confined to a joint may be the result of:

- Synovial fluid from an inflammatory process such as rheumatoid arthritis or osteoarthritis

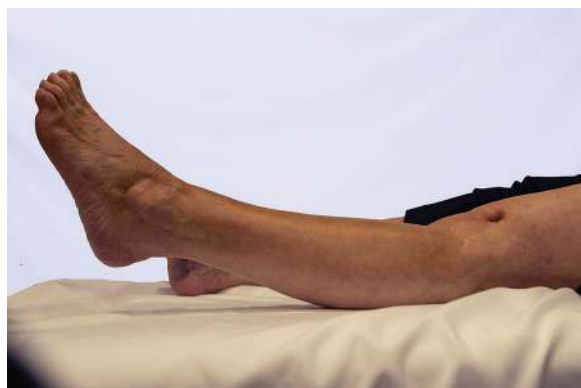

Figure 1.3 The location of scars is a clue to the underlying injury or surgery. This patient has a transverse scar, which may indicate damage to the extensor mechanism. In this case, the patient had a direct impact injury which resulted in a lacerated patella tendon which was repaired and a posterior cruciate ligament (PCL) injury that was untreated. Hence, there is recurvatum as she tries to straight leg raise.

- Blood (haemarthrosis) from a recent injury, blood coagulation defect or medication such as warfarin
- Pus from an infection

Diffuse swelling affecting part or an *entire limb* in a patient with orthopaedic injuries or recent orthopaedic intervention, particularly pelvic and lower limb surgeries, should arouse a differential diagnosis of a venous thromboembolic event, which warrants further investigations.

Bruising is usually the result of trauma to tissues owing to a recent injury or surgery.

Muscle wasting may arise from disuse because of pain, other abnormality or muscle denervation. Muscle wasting is quantified by comparing the affected limb with the normal limb or by measuring the circumference of the limb at a fixed point from a bony landmark.

Alteration in shape or posture may be caused by a congenital anomaly, skeletal dysplasia, joint degeneration or the sequelae of a previous injury.

Finally, inspection should conclude by looking for and describing any orthosis or walking aid.

In clinical examinations at a junior level, it is desirable to describe both positive and negative findings. In more senior examinations, inspection should still be complete, but is performed much more rapidly with only positive and important negative findings expressed. Examiners may become agitated if senior candidates spend too much time on inspection.

Feel

Irrespective of the joint being examined palpation should always be carried out in a systematic manner with reference to the anatomic landmarks. The details of how to carry out a satisfactory palpation of the various joints are discussed in the relevant chapters, but an essential aspect of palpation is that the examiner must not only look at the joint being examined but also look at the patient's face to appreciate any areas of tenderness (Figure 1.4).

Ensure that hands are washed or antiseptic gel is used. Rubbing your hands together to warm them makes palpation more comfortable for the patient.

Some joints, such as the hip, spine and shoulder, are deeper and therefore significant information may not be gained from palpation compared to the more superficial joints such as the hand, elbow, knee, foot and ankle. By knowing the surface anatomy of these joints, tenderness over the relevant areas may lead to the diagnosis. For example, tenderness over the lateral epicondyle of the elbow indicates tennis elbow and tenderness over the medial joint line of the knee may indicate a medial meniscus tear.

If a *bony lump* is felt, there are particular aspects of the lump that must be described: site, size, consistency, margin, tenderness, multiplicity.¹ Each of these features can give particular information with regards to the diagnosis and if benign or malignant. For example, a lump nearer to the joint is more likely to be a tumour compared to a mid-shaft lump; a lump with a well-defined margin is more likely to be benign; a benign tumour is usually hard, whereas a malignant one can give the impression that it can be indented; multiple bony lumps are uncommon, but if present can suggest hereditary multiple exostosis or even Ollier's disease.

Sensory Testing

There are various methods of testing sensory deficit in a peripheral nerve lesion. There is usually overlap between the nerves, but mapping an area of sensory loss is usually determined firstly by light touch. This is usually performed with a piece of cotton wool with the patient closing their eyes (Figure 1.5). A Semmes-Weinstein monofilament can be used for light touch; this is especially useful in the foot, where it has been shown to be a reliable and specific method of assessing protective sensation.²

Following light touch, sharp sensation with a pin can be assessed. It should be noted that following

General Principles of Orthopaedic Clinical Examination

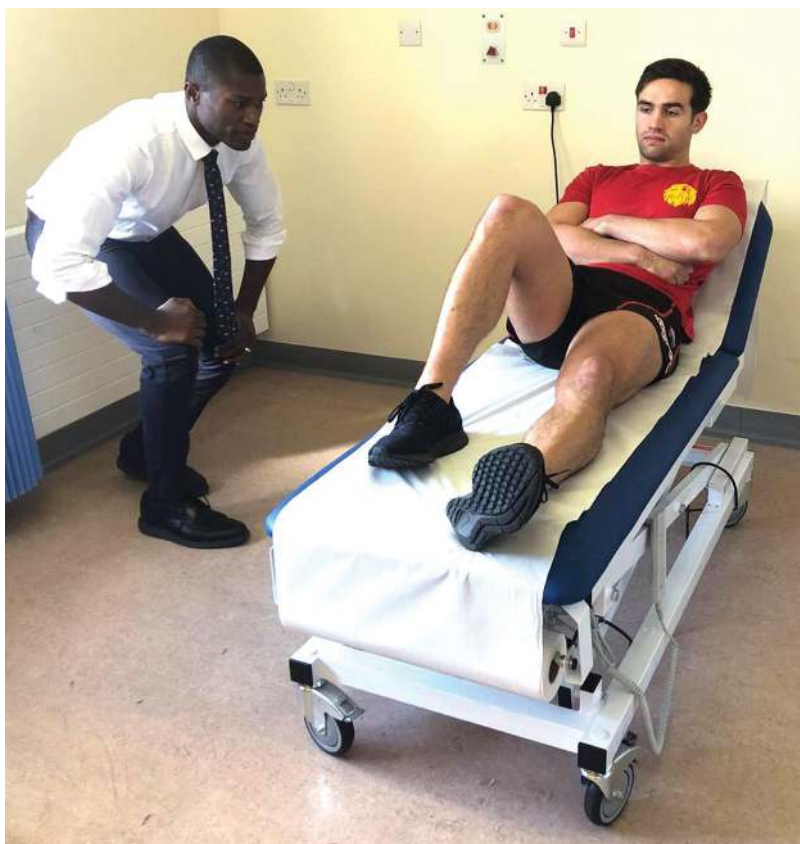
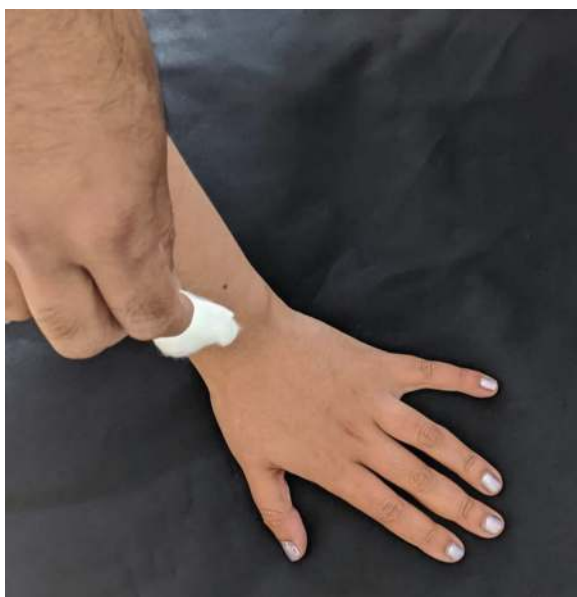
Figure 1.4 Observe the patient closely whilst examining. Look at the joint or limb and always remember to observe the face.



4

Figure 1.5 Cotton bud used for light touch.

a peripheral nerve injury, pinprick sensation usually returns before light touch.

In the hand, where the tactile ability of the hand is so refined, *two-point discrimination* is a useful way of assessing nerve deficit. Normally someone can differentiate two sharp points placed 5 mm apart. In performing this test, the patient closes his or her eyes and is asked whether they can feel one or two points by randomly pressing one or two tips onto the skin. If the patient is unable to discriminate the two tips placed 5 mm apart, this distance is then increased and the test repeated (Figure 1.6).

Move

Both active and passive range of movement of the joint being examined should be assessed. It is advisable to carry out active range of movement before passive as this gives the examiner an idea of the functional range of movement and any associated pain. The patient must be given clear instruction or a demonstration of the range of movement to be

General Principles of Orthopaedic Clinical Examination



Figure 1.6 Testing two-point discrimination.

assessed. Demonstration is sometimes the best method of communicating to the patient.

It is always advisable to compare the range of movement of the symptomatic with the asymptomatic or normal joint, and the range achieved should be recorded in degrees as measured by a goniometer.

With regards to movement, some points should be noted:

- Sometimes it may not be possible to assess active range of movement in certain situations (such as with a very young child or a patient with cerebral palsy or neurological disturbance).
- Tendon, muscle or nerve injury may preclude active movement, and in these situations only passive movement can be assessed. However, be aware that the patient may use gravity or a trick movement to move the affected joint, thus misleading the examiner.
- In certain conditions, such as following injury or surgery, a tendon may heal at a longer length. Here there may be a difference in active and passive movements. For example, in a chronic quadriceps rupture when the patient is asked to straight leg raise, there may be an extensor lag that is only evident after passive extension of the knee joint is performed.
- Excessive passive joint movement or movement in abnormal planes may be the result of generalised ligamentous laxity or ligament/bony abnormality. Generalised ligamentous laxity can be assessed fully using Beighton's scoring system (Figure 1.7). A total score greater than or equal to 4 indicates hypermobility. In a child, this may be a score of 5 or 6.³
- A joint that is grossly degenerate may have limited active or passive range of movement.

- Complete loss of (active and passive) movement may be the result of previous surgery, e.g. in a patient who has had a previous arthrodesis.

Table 1.1 summarises normal joint range of movement and acceptable positions of surgical fusion.^{4,5,6}

Power

Muscle strength is an integral part of the neurological assessment and is best carried out in a systematic manner from proximal to distal and recorded using the Muscle Research Council (MRC) scale (Table 1.2). It is important to understand how to differentiate between grade 2 and grade 3 by eliminating gravity (Figures 1.8 and 1.9). In general, this can be accomplished by examining the joint movements in a plane that is 90 degrees from that in which gravity acts.

Correctly identifying the signs of a neurological lesion may be important in helping to distinguish between an upper motor neuron (UMN) lesion and a lower motor neuron (LMN) lesion. In an UMN lesion paralysis affects movement rather than muscle. Muscle wasting is slight and usually due to disuse, whereas in an LMN lesion the wasting is pronounced.

Table 1.3 provides a summary of the differences between the two.

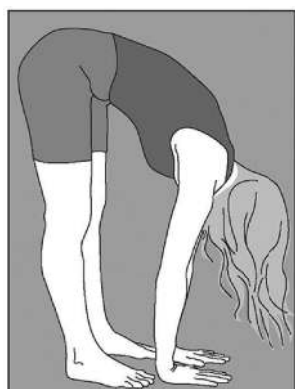
Gait

It is important that normal gait be understood when examining a patient, especially with regards to the lower limb and the spine. It is only then can pathology that affects the gait be picked up.

The prerequisites for normal gait are:

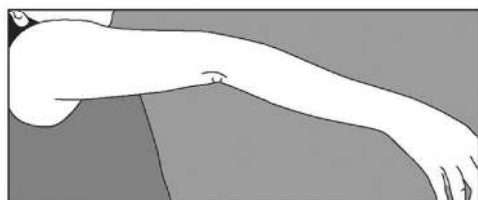
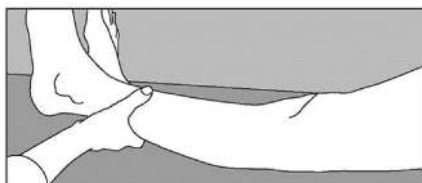
- Stability in stance
- Foot clearance in swing
- Pre-positioning of the ankle in swing

General Principles of Orthopaedic Clinical Examination

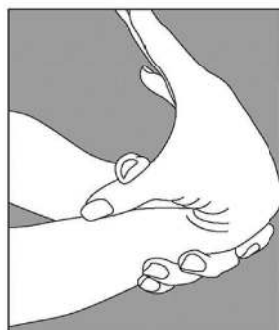

Score one point if you bend and place your hands flat on the floor without bending your knees.

Score one point for each Knee that hyperextends



Score one point for each elbow that hyperextends



Score one point for each thumb that will bend back backwards to touch the forearm.

Score one point for each hand when you can bend the little finger MCP joint back beyond 90°

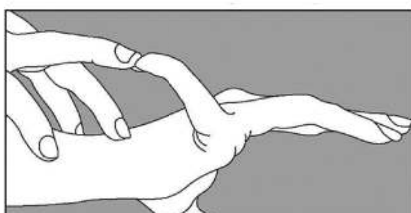


Figure 1.7 Assessing Beighton's score. Note that four pairs of tests are passive and one test is active (spine).
 MCP, metacarpophalangeal

- Adequate step length
- Energy conservation

When describing the gait of a patient, this can only sound proficient if certain definitions are understood. The important ones are explained below. In addition, Figure 1.10 illustrates the varied positions of the parts of the lower limb through the gait cycle.

Gait cycle: Point in time from initial contact of one foot to initial contact of the same foot.

Step: From initial contact of one foot to the initial contact of the contralateral foot.

Stride: Period from initial contact of one foot to initial contact of the same foot. Therefore, there are two steps in a stride.

Cadence: Number of steps per minute.

Stance: Period when the foot is on the ground. It starts with initial contact and finishes with toe off. Stance makes up 60% of the gait cycle.

Swing: Period when the foot is off the ground. It starts at toe off and finishes with initial contact. Swing makes up 40% of the gait cycle.

During stance phase, three foot and ankle rockers can be described in sequence (Figure 1.11). In the first rocker (heel rocker), there is initial contact with heel strike followed by plantarflexion of the ankle. In the second rocker (ankle rocker), there is tibial advancement over the foot achieved by ankle dorsiflexion. In the third rocker (forefoot rocker), there is

General Principles of Orthopaedic Clinical Examination

Table 1.1 Average range of movement (ROM) of some of the joints in the body. The acceptable positions of surgical fusion for the various joints are also shown.

	Range of motion	Position of surgical fusion
Cervical spine	Flexion: 80° Extension: 50° lateral flexion: 45° rotation: 80°	
Thoraco-lumbar spine	flexion(thoracic): 45° flexion (lumbar): 60° lateral flexion: 30° rotation (thoracic): 40°	
Shoulder	Flexion: 165° Extension: 60° Abduction: 170° internal rotation: 70° external rotation: 100°	20°–25° (30° avg) 15°–20° (30° avg) 40°–50° (30° avg)
Elbow	Flexion: 140° Extension: up to –10° Supination: 80° Pronation: 75°	90° if unilateral, 110° vs 65° if bilateral
Wrist	Dorsiflexion: 75° palmar flexion: 75° radial deviation: 20° ulnar deviation: 35°	10°–20°
Hip *at 90° flexion	Flexion: 120° Extension: 10° Abduction: 45° Adduction: 25° internal rotation*: 45° external rotation*: 50°	20°–30° 0°–5° 5–10°
Knee	Flexion: 135°	10°–15° (flexion) 0°–7° (valgus)
Ankle	Dorsiflexion: 20° Plantarflexion: 50°	neutral (dorsiflexion) 5° (hindfoot valgus) 5°–10° (external rotation)
Foot	Inversion: 20° Eversion: 10°	
Thumb	IP joint flexion: 80° IP joint extension: 15° MCP joint flexion: 55° opposition- able to touch tip of little finger	15°–30° 20°–25°
Fingers	MCP joint flexion: 90° MPJ passive hyperextension: up to 40° PIP joint flexion: 100° DIP joint flexion: 80°	index 25°, long 30°, ring 35°, small 40° index 40°, long 45°, ring 50°, small 55° 10°
Great toe	MTP joint flexion: 40° MTP joint extension: 70° IP joint flexion: 60° IP joint extension: 0°	10°–15° dorsiflexion; also slight valgus/neutral rotation

DIP, distal interphalangeal; IP, interphalangeal; MCP, metacarpophalangeal; MTP, metatarsophalangeal; PIP proximal interphalangeal

Table 1.2 MRC grading for motor power

Grade	
0	No muscle contraction
1	Flicker of contraction
2	Movement with gravity eliminated
3	Movement against gravity
4	Movement against gravity and some resistance
5	Full power

heel rise caused by forefoot dorsiflexion and ankle plantarflexion.

In children, there are some differences in gait that are more evident in the younger child:

- Wider base of support
- Flat foot strike instead of heel strike
- Greater knee flexion in stance
- Leg externally rotated in swing
- Cadence higher
- Absence of reciprocal arm swing

As the child gets older, these become more like the adult pattern. For example, heel strike, knee flexion and external rotation become adult pattern by 2 years. Walking base and arm swing by 4 years.

Further Examination

Special Tests

In addition to the triad of *look, feel, move*, other tests specific to the part being examined may be required to enable the examiner to reach a diagnosis, e.g. the anterior draw or Lachman's test for anterior cruciate ligament insufficiency. The various tests will be discussed later in this book in the respective chapters. Each test has a variable sensitivity and specificity. Table 1.4 shows some of these values. It can be seen that very few clinical tests are reliable on their own. A combination of clinical tests may be of greater diagnostic value, e.g. combining Neer's and Hawkins–Kennedy tests to make the diagnosis of subacromial impingement.¹⁸

The examiner must be prepared to examine the joint above and below the main joint being examined, as the patient may be presenting with referred pain. For example, a patient with a slipped upper femoral epiphysis may present with knee pain, and failure to examine the hip joint will cause the examiner to miss the diagnosis. In addition, pathology in one joint may directly affect adjacent joints.

General Principles of Orthopaedic Clinical Examination

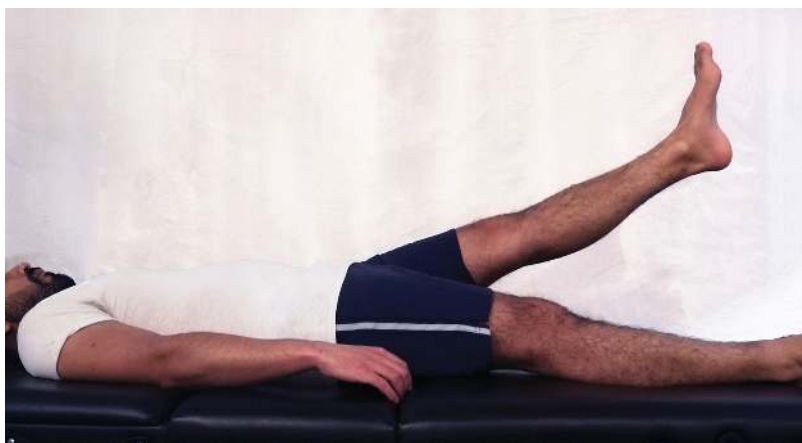

Figure 1.8 Testing MRC grade 3 motor power of the quadriceps.

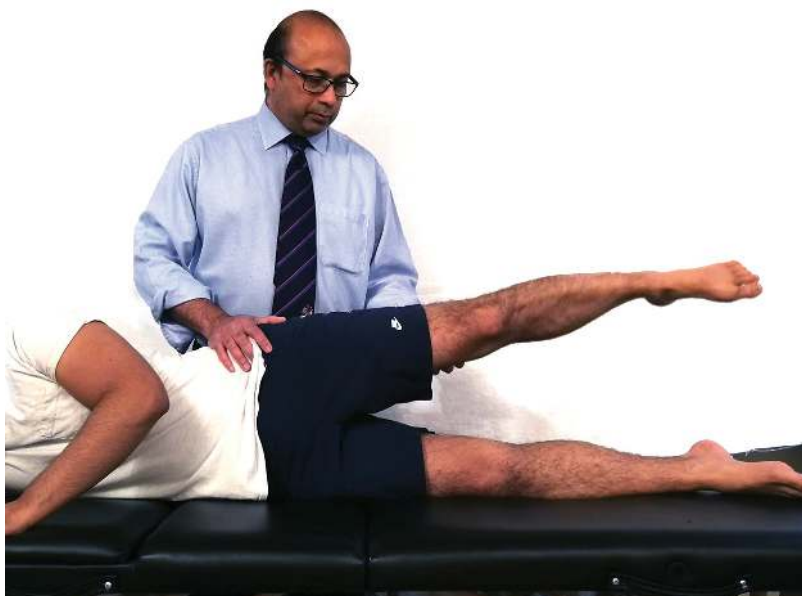

Figure 1.9 Testing MRC grade 2 motor power of the quadriceps with the effect of gravity eliminated.

Neurovascular Assessment

A neurovascular assessment is also an important aspect of any examination. It is important to ascertain if there is a true neurological deficit or if neurological symptoms are mimicking musculoskeletal symptoms. In some instances (e.g. in patients with nerve palsy), it may be necessary to undertake this assessment early on in the examination after inspection.

In the neurological assessment, it is not good enough to assess only power. Tone must also be assessed because it is possible to have reduced power in the presence of either increased or decreased tone.

8

The tendon reflex is also regarded as a reliable pointer to the segmental level of a dysfunction.

Vascular symptoms such as vascular claudication may mimic musculoskeletal symptoms.

Advanced Corner

We all may be faced with clinical scenarios that challenge us, and for these it is important not only to stick to first principles but also to have a degree of flexibility in order to adapt our examination routine to elicit clinical signs and come to logical conclusions.

General Principles of Orthopaedic Clinical Examination

Table 1.3 The characteristics of upper motor neuron and lower motor neuron lesions

	Upper motor neuron	Lower motor neuron
Site of lesion	Brain and spinal cord (above ant. horn cells)	Anterior horn cells, nerve root and peripheral nerve
Muscle wasting	Muscle mass maintained (some disuse atrophy)	Rapid muscle wasting
Tone	Increased	Decreased
Power	Decreased	Decreased
Tendon reflexes	Increased	Decreased
Pathological reflexes	Plantar response upgoing (Babinski's sign) Abdominal reflex absent (depending on spinal level)	Plantar response normal or absent Abdominal reflex present
Fasciculations/fibrillations	Absent	Could be present

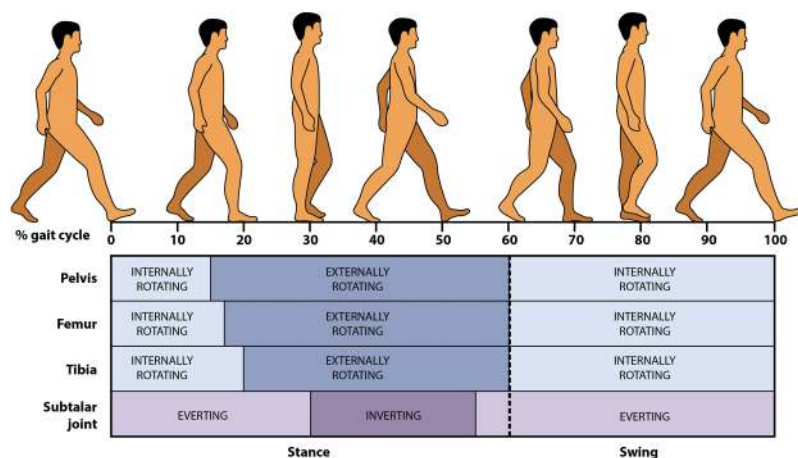


Figure 1.10 Illustration showing the position of the ankle, pelvis, femur, tibia and subtalar joints through the gait cycle.

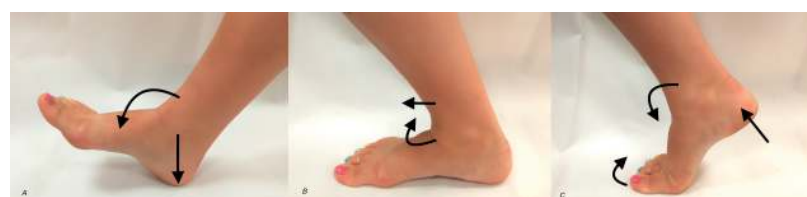

Figure 1.11 The three rockers. (A) Heel rocker with heel strike followed by ankle plantarflexion. (B) Ankle rocker with tibial advancement achieved by ankle dorsiflexion. (C) Forefoot rocker where heel raise is caused by forefoot dorsiflexion and ankle plantarflexion.

Clinical tips for these scenarios are invaluable, but in some cases the clinical presentation may be one that you have not encountered before, and these require you, the clinician, to think on your feet and formulate an appropriate examination sequence. It always helps if you have thought about these situations beforehand!

The following are a few examples of special scenarios where prior consideration would allow the

candidate to feel more at ease with the clinical examination:

- A patient with significant abduction deformity of the hip will present with apparent lengthening of the affected side with compensatory pelvic tilt, tiptoeing, or shoe raise of the contralateral side, or with bending of the ipsilateral knee. There is a 2.5 cm of apparent lengthening for every 10 degrees of abduction deformity. The reverse is true

General Principles of Orthopaedic Clinical Examination

Table 1.4 The sensitivity and specificity of some of the common clinical tests and signs. Note that these values are very variable in the literature therefore studies showing the average values have been chosen.

Test	Sensitivity	Specificity
Neer's sign ⁷	.76	.47
Hawkins–Kennedy test ⁷	.75	.44
Speed's test ⁸	.63	.58
Scarf (cross adduction) test ⁹	.25	.80
O'Brien's test ¹⁰	.63	.73
Kirk Watson test ¹¹	.69	.66
Tinel's sign (at wrist) ¹²	.50	.77
Phalen's test ¹²	.68	.73
Trendelenburg test ¹³	.73	.77
Lachman's test ¹⁴	.85	.94
Anterior draw test ¹⁴	.55	.92
Pivot shift test ¹⁴	.24	.98
McMurray's test ¹⁵	.55	.77
Thessaly test ¹⁵	.89	.97
Anterolateral ankle impingement test ¹⁶	.95	.88
Straight leg raise (SLR) ¹⁷	.52	.89
Allen's test ¹⁹	.73	.91

for adduction deformities, with patients presenting with apparent shortening to the same scale.

- Measuring limb length in a patient with varus or valgus deformities about the knee can be challenging and should be carried out in segments to prevent inaccurate results. Measure from the anterior superior iliac spine to the lateral or medial condyle (fixed bony point) of the femur and from the condyle to the medial malleolus.
- The use of a tape measure in leg length measurement is not helpful in patients with significant foot and ankle pathology where the shortening is coming from below the medial malleolus such as in subtalar arthritis or previous calcaneal fracture. In such cases, the use of standing blocks is advised. In turn, blocks are inaccurate for measuring leg length discrepancies in patients with flexed flexion deformities of the lower limb (Figure 1.12).
- Increased lumbar lordosis may be compensatory for a fixed flexion deformity of the hip joint. In a standing position, a patient wants to be upright so they will increase their lumbar curvature to

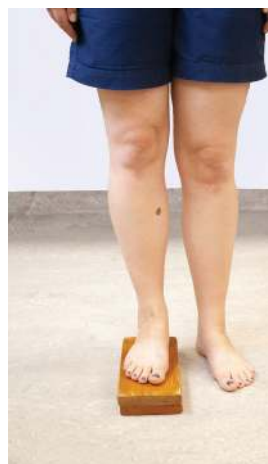

Figure 1.12 Blocks of varying thicknesses can be used to assess limb length discrepancy. These are most useful when the shortening is coming from below the medial malleolus (see text) and least useful if the patient has either a coronal or sagittal plane fixed deformity in either limb.

compensate. Up to 30° of hip fixed flexion can be compensated for by this means.

- Thomas test can be carried out in a variety of conditions with slight modifications to the examination technique. In a patient with a fixed spine, such as ankylosing spondylitis, proceed as normal but bear in mind that complete elimination of the lumbar lordosis with progressive hip flexion, as described, will not be possible.
- If asked to perform Thomas test on a patient who has a contralateral arthrodesis of the hip how do you proceed? Answer: Lift that leg by the heel and allow the pelvis to tilt and reduce the lumbar lordosis.
- In a patient with a total hip replacement, when performing Thomas test, avoid flexing that hip beyond 90° to minimise the risk of dislocation. It can be safer to ask the patient to flex their hip to the point where they still feel secure (i.e. a patient-controlled Thomas test).
- When you are asked to examine a patient with a limb amputation, it is prudent in such cases to first perform a thorough inspection. Assess the residual limb length, the suture line, scar mobility, skin condition and sensation, bony/weight-bearing prominences and the soft tissue envelope. Look at orthoses or prostheses that may be present. Always remember to look for clues as to why the patient had an amputation. For example, in a lower limb amputation examining