

Contents

1 Introduction to Dental Anatomy, 1

- Pretest Questions, 1
- Formation of the Dentitions (Overview), 2
- Nomenclature, 2
- Formulae for Mammalian Teeth, 2
- Tooth Numbering Systems, 2
- Division Into Thirds, Line Angles, and Point Angles, 9
- Tooth Drawing and Carving, 10
- Measurement of Teeth, 11
- Pretest Answers, 19

2 Development and Eruption of the Teeth, 20

- Pretest Questions, 20
- Clinical Considerations, 20
- Variability, 21
- Malformations, 21
- Chronology of Primary Dentition, 21
- Development and Eruption/Emergence of the Teeth, 22
- Dentitions, 25
- Neuromuscular Development, 28
- Transitional (Mixed) Dentition Period, 29
- Loss of Primary Teeth, 30
- Permanent Dentition, 31
- Size of Teeth, 32
- Dental Pulp, 32
- Cementoamel Junction, 32
- Dental Age, 33
- Tooth Formation Standards, 34
- Chronologies of Human Dentition, 35
- Types of Chronologies, 35
- Stages of Tooth Formation, 35
- Age of Attainment, 35
- Age Prediction, 36
- Maturity Assessment, 36
- Duration of Root and Crown Formation, 38
- Summary of Chronologies, 38
- Sequence of Eruption, 38
- Estimating Time of Enamel Hypoplasia, 38
- Pretest Answers, 39

3 The Primary (Deciduous) Teeth, 41

- Pretest Questions, 41
- Life Cycle, 41
- Importance of Primary Teeth, 41
- Nomenclature, 42

- Major Contrasts Between Primary and Permanent Teeth, 43
- Pulp Chambers and Pulp Canals, 43
- Detailed Description of Each Primary Tooth, 46
- Pretest Answers, 60

4 Forensics, Comparative Anatomy, Geometries, and Form and Function, 61

- Pretest Questions, 61
- Forensic Dentistry, 61
- Comparative Dental Anatomy, 64
- Facial and Lingual Aspects of All Teeth, 68
- Summary of Schematic Outlines, 69
- Form and Function of the Permanent Dentition, 69
- Alignment, Contacts, and Occlusion, 70
- Pretest Answers, 72

5 Orofacial Complex: Form and Function, 74

- Pretest Questions, 74
- Form and Function, 74
- Form Follows Function, 74
- Articulation of Teeth, 74
- Physiologic Form of the Teeth and Periodontium, 75
- Fundamental Curvatures, 75
- Proximal Contact Areas, 75
- Interproximal Spaces (Formed by Proximal Surfaces in Contact), 78
- Embrasures (Spillways), 79
- Contact Areas and Incisal and Occlusal Embrasures From the Labial and Buccal Aspect, 81
- Contact Areas and Labial, Buccal, and Lingual Embrasures From the Incisal and Occlusal Aspects, 82
- Facial and Lingual Contours at the Cervical Thirds (Cervical Ridges) and Lingual Contours at the Middle Thirds of Crowns, 84
- Height of Epithelial Attachment: Curvatures of the Cervical Lines (Cementoamel Junction) Mesially and Distally, 86
- Pretest Answers, 89

6 The Permanent Maxillary Incisors, 90

- Pretest Questions, 90
- Maxillary Central Incisor, 90
- Maxillary Lateral Incisor, 97
- Pretest Answers, 102

- 7 The Permanent Mandibular Incisors, 103**
 Pretest Questions, 103
 Mandibular Central Incisor, 103
 Mandibular Lateral Incisor, 109
 Pretest Answers, 113
- 8 The Permanent Canines: Maxillary and Mandibular, 114**
 Pretest Questions, 114
 Maxillary Canine, 115
 Mandibular Canine, 121
 Pretest Answers, 127
- 9 The Permanent Maxillary Premolars, 128**
 Pretest Questions, 128
 Maxillary First Premolar, 129
 Maxillary Second Premolar, 137
 Pretest Answers, 141
- 10 The Permanent Mandibular Premolars, 142**
 Pretest Questions, 142
 Mandibular First Premolar, 142
 Mandibular Second Premolar, 149
 Pretest Answers, 154
- 11 The Permanent Maxillary Molars, 155**
 Pretest Questions, 155
 Maxillary First Molar, 156
 Maxillary Second Molar, 164
 Maxillary Third Molar, 168
 Pretest Answers, 171
- 12 The Permanent Mandibular Molars, 172**
 Pretest Questions, 172
 Mandibular First Molar, 172
 Mandibular Second Molar, 181
 Mandibular Third Molar, 185
 Pretest Answers, 189
- 13 Pulp Chambers and Canals, 190**
 Pretest Questions, 190
 Pulp, Chamber, and Canals, 190
 Radiographs, 190
 Foramen, 192
 Demarcation of Pulp Cavity and Canal, 193
 Pulp Horns, 193
 Clinical Applications, 193
 Pulp Cavities of the Maxillary Teeth, 194
 Pulp Cavities of the Mandibular Teeth, 202
 Radiographs: Pulp Chamber and Canals, 213
 Crown and Root Fractures, 213
 Pretest Answers, 216
- 14 Dento-Osseous Structures, Blood Vessels, and Nerves, 217**
 Pretest Questions, 217
 The Maxillae, 217
 The Mandible, 222
 Arterial Supply to the Teeth, 229
 Nerve Supply to the Jaws and Teeth, 231
 Pretest Answers, 234
- 15 The Temporomandibular Joints, Teeth, and Muscles and Their Functions, 235**
 Pretest Questions, 235
 Temporomandibular Articulation, 235
 Muscles, 240
 Mandibular Movements and Muscle Activity, 245
 Pretest Answers, 248
- 16 Occlusion, 250**
 Pretest Questions, 250
 Concepts of Occlusion, 250
 Development of the Dentitions, 251
 Primary Dentition, 251
 Mixed (Transitional) Dentition, 254
 Permanent Dentition, 256
 Cusp, Fossa, and Marginal Ridge Relations, 263
 Lateral Occlusal Relations, 266
 Biomechanics of Chewing Function, 271
 Neurobehavioral Aspects of Occlusion, 272
 Oral Motor Behavior, 276
 Swallowing, 277
 Pretest Answers, 277
- 17 Clinical Application of Dental Anatomy, Physiology, and Occlusion, 280**
 Pretest Questions, 280
 Instrument Design/Usage Relating to Dental Anatomy, 280
 Oral Surgery, 282
 Periodontics, 284
 Endodontics, 287
 Restorative Dentistry, 288
 Esthetics, 289
 Variant Anatomy, 290
 Occlusion, 291
 Pretest Answers, 292
- Appendix A: Review of Tooth Morphology, 294**
- Appendix B: Tooth Traits of the Permanent Dentition, 311**
- Index, 321**

1

Introduction to Dental Anatomy

LEARNING OBJECTIVES

1. Correctly define and pronounce the nomenclature (terms) as emphasized in the bold type in this and each following chapter.
2. Be able to identify each tooth of the primary and permanent dentitions using the Universal, Palmer, and Fédération Dentaire Internationale (FDI) systems.
3. Correctly name and identify the surfaces, ridges, and anatomic landmarks of each tooth.
4. Understand and describe the methods used to measure anterior and posterior teeth.
5. Learn the tables of measurements and be able to discuss size comparisons between the teeth from any viewing angle. A useful skill at this point is to start illustrating the individual teeth with line drawings.

Pretest Questions

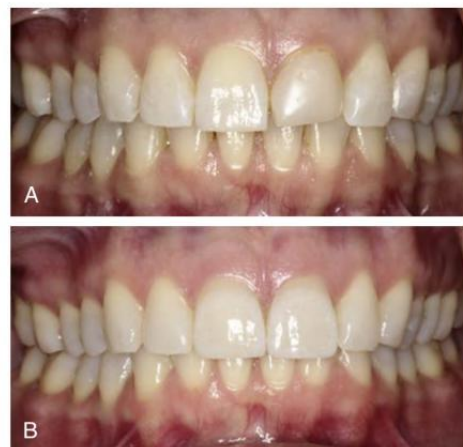1. The dental formula for the permanent human dentition is which of the following?
A. $I\ 2/2\ C\ 1/1\ M\ 2/2 = 10$
B. $I\ 2/2\ C\ 1/1\ P\ 1/1\ M\ 2/2 = 12$
C. $I\ 2/2\ C\ 1/1\ P\ 2/2\ M\ 2/2 = 14$
D. $I\ 2/2\ C\ 1/1\ P\ 2/2\ M\ 3/3 = 16$
2. The notation for the primary mandibular left canine is which of the following according to the FDI system?
A. 53
B. 63
C. 73
D. 83
3. The notation for the primary maxillary left lateral incisor is which of the following according to the Universal system?
A. D
B. G
C. E
D. F
4. Which of the following represents the name of the bone of the tooth socket that firmly fixes each tooth root?
A. Alveolar process
B. Alveolus
C. Cementoenamel junction
D. Dentinoenamel junction

5. Which of the following terms represents the surface of a tooth that is facing toward an adjoining tooth in the same dental arch?
A. Occlusal
B. Incisal
C. Facial
D. Proximal

For additional study resources, please visit Expert Consult.

Dental anatomy is defined here as, but is not limited to, the study of the development, morphology, function, and identity of each of the teeth in the human dentitions, as well as the way in which the teeth relate in shape, form, structure, color, and function to the other teeth in the same dental arch and to the teeth in the opposing arch. Thus the study of dental anatomy, physiology, and occlusion provides one of the basic components of the skills needed to practice all phases of dentistry.

The application of dental anatomy to clinical practice can be envisioned in Fig. 1.1A, where a faulty crown form has resulted in esthetic and periodontal problems that may be corrected by an appropriate restorative dental treatment, such as that illustrated in Fig. 1.1B. The practitioner must have knowledge of the morphology, occlusion, esthetics, phonetics, and functions of these teeth to undertake such treatment.



• **Fig. 1.1** Restoration of maxillary central incisors with porcelain veneers taking into account esthetics, occlusion, and periodontal health. (Case and photographs courtesy of Michael P. Webberson, DDS, Las Vegas, NV.)

Formation of the Dentitions (Overview)

Humans have two sets of teeth in their lifetime. The first set of teeth to be seen in the mouth is the **primary** or **deciduous** dentition, which begins to form prenatally at approximately 14 weeks in utero and is completed postnatally at approximately 3 years of age. In the absence of congenital disorders, dental disease, or trauma, the first teeth in this dentition begin to appear in the oral cavity at the mean age of 6 months, and the last emerge at a mean age of 28 ± 4 months. The deciduous dentition remains intact (barring loss from dental caries or trauma) until the child is approximately 6 years of age. At approximately that time, the first **succedaneous** or **permanent** teeth begin to emerge into the mouth. The emergence of these teeth begins the **transition** or **mixed dentition period**, in which there is a mixture of deciduous and succedaneous teeth present. The transition period lasts from approximately 6 to 12 years of age and ends when all the deciduous teeth have been shed. At that time, the permanent dentition period begins. Thus the transition from the primary dentition to the permanent dentition begins with the emergence of the first permanent molars, shedding of the deciduous incisors, and emergence of the permanent incisors. The mixed dentition period is often a difficult time for the young child because of habits, missing teeth, teeth of different colors and hues, crowding of the teeth, and malposed teeth.

The permanent, or succedaneous, teeth replace the exfoliated deciduous teeth in a sequence of eruption that exhibits some variance, an important topic considered in [Chapter 16](#).

After the shedding of the deciduous canines and molars, emergence of the permanent canines and premolars, and emergence of the second permanent molars, the permanent dentition is completed (including the roots) at approximately 14 to 15 years of age, except for the third molars, which are completed at 18 to 25 years of age. In effect, the duration of the permanent dentition period is 12 or more years. The completed permanent dentition consists of 32 teeth if none is congenitally missing, which may be the case. The development of the teeth, dentitions, and the craniofacial complex is considered in [Chapter 2](#). The development of occlusion for both dentitions is discussed in [Chapter 16](#).

Nomenclature

The first step in understanding dental anatomy is to learn the nomenclature, or the system of names, used to describe or classify the material included in the subject. When a significant term is used for the first time here, it is emphasized in bold. Additional terms are discussed as needed in subsequent chapters.

The term **mandibular** refers to the lower jaw, or mandible. The term **maxillary** refers to the upper jaw, or maxilla. When more than one name is used in the literature to describe something, the two most commonly used names will be used initially. After that, they may be combined or used separately, as consistent with the literature of a particular specialty of dentistry, for example, **primary** or **deciduous dentition**, **permanent** or **succedaneous dentition**. A good case may be made for the use of both terms. By dictionary definition,¹ the term *primary* can mean “constituting or belonging to the first stage in any process.” The term *deciduous* can mean “not permanent, transitory.” The same unabridged dictionary refers the reader from the definition of *deciduous tooth* to *milk tooth*, which is defined as “one of the temporary teeth of a mammal that are replaced by permanent teeth; also called *baby tooth*, *deciduous tooth*.” The term *primary* can indicate a first dentition, and the term *deciduous* can indicate that the first dentition is

not permanent but not unimportant. The term *succedaneous* can be used to describe a successor dentition and does not suggest permanence, whereas the term *permanent* suggests a permanent dentition, which may not be the case because of dental caries, periodontal diseases, and trauma. All four of these descriptive terms appear in the professional literature.

Formulae for Mammalian Teeth

The denomination and number of all mammalian teeth are expressed by formulae that are used to differentiate the human dentitions from those of other species. The denomination of each tooth is often represented by the initial letter in its name (e.g., I for incisor, C for canine, P for premolar, M for molar). Each letter is followed by a horizontal line and the number of each type of tooth is placed above the line for the maxilla (upper jaw) and below the line for the mandible (lower jaw). The formulae include one side only, with the number of teeth in each jaw being the same for humans.

The dental formula for the primary/deciduous teeth in humans is as follows:

$$\begin{array}{c} 2 \\ \hline I \\ \hline 2 \end{array} \begin{array}{c} 1 \\ \hline C \\ \hline 1 \end{array} \begin{array}{c} 2 \\ \hline M \\ \hline 2 \end{array} = 10$$

This formula should be read as: incisors, two maxillary and two mandibular; canines, one maxillary and one mandibular; molars, two maxillary and two mandibular—or 10 altogether on one side, right or left ([Fig. 1.2A](#)).

A dental formula for the permanent human dentition is as follows:

$$\begin{array}{c} 2 \\ \hline I \\ \hline 2 \end{array} \begin{array}{c} 1 \\ \hline C \\ \hline 1 \end{array} \begin{array}{c} 2 \\ \hline P \\ \hline 2 \end{array} \begin{array}{c} 3 \\ \hline M \\ \hline 3 \end{array} = 16$$

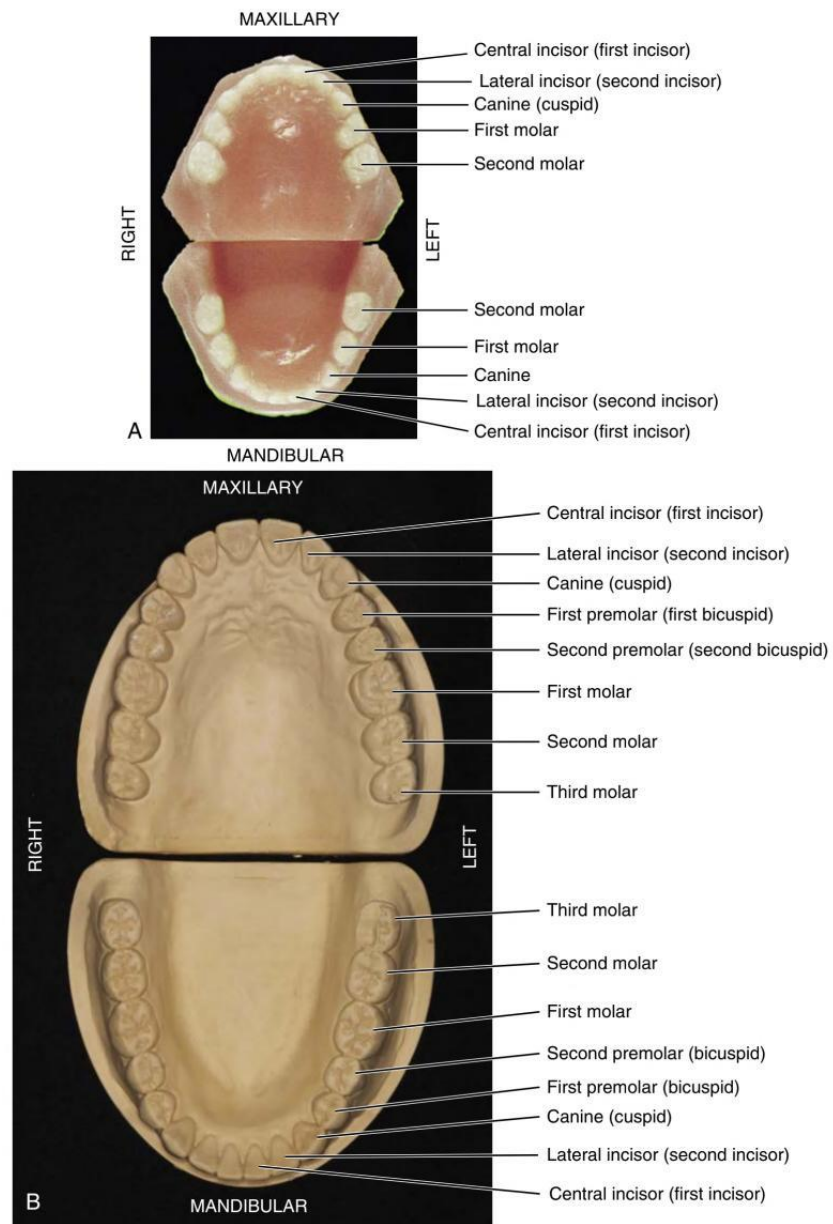
Premolars have now been added to the formula, two maxillary and two mandibular, and a third molar has been added, one maxillary and one mandibular (see [Fig. 1.2B](#)).

Systems for scoring key morphologic traits of the permanent dentition that are used for anthropologic studies are not described here. However, a few of the morphologic traits that are used in anthropologic studies² are considered in later chapters (e.g., shovel-shaped incisors, Carabelli trait, enamel extensions, peg-shaped incisors). Some anthropologists use di_1 , di_2 , dc , dm_1 , and dm_2 notations for the deciduous dentition and I_1 , I_2 , C , P_1 , P_2 , M_1 , M_2 , and M_3 for the permanent teeth. These notations are generally limited to anthropologic tables because of keyboard incompatibility.

Tooth Numbering Systems

In clinical practice, some “shorthand” system of tooth notation is necessary for recording data. Several systems are in use around the world, but only a few are considered here. In 1947 a committee of the American Dental Association (ADA) recommended the symbolic system (Zsigmondy/Palmer) as the numbering method of choice.³ However, because of difficulties with keyboard notation of the symbolic notation system, the ADA in 1968 officially recommended the “universal” numbering system. Because of some limitations and lack of widespread use internationally, recommendations for a change sometimes are made.⁴

The **Universal** system of notation for the primary dentition uses uppercase letters for each of the primary teeth: For the maxillary teeth, beginning with the right second molar, letters A through J, and for the mandibular teeth, letters K through T, beginning with



• **Fig. 1.2** (A) Casts of deciduous, or primary, dentition. (B) Casts of permanent dentition. (A, From Berkovitz BK, Holland GR, Moxham BJ: *Oral anatomy, histology and embryology*, ed 3, St Louis, 2002, Mosby.) (To view Animations 1 and 2, please go to Expert Consult.)