Contents

Contributors vi
Preface viii

SECTION I ANESTHESIA AND EMERGENCY PROCEDURES

1 Anesthesia and Emergency Procedures 2
John R. Lien and Kevin C. Chung

2 Fasciotomy for Compartment Syndrome of the Hand and Forearm 8
John R. Lien and Kevin C. Chung

3 Revision Amputation and Shortening of the Digit 14
John R. Lien and Kevin C. Chung

4 Drainage of Septic Flexor Tenosynovitis 19
John R. Lien and Kevin C. Chung

SECTION II HAND FRACTURES AND DISLOCATIONS

5 Distal Phalanx Fractures 23
John R. Fowler and Thomas B. Hughes

6 Proximal Phalanx Fractures 28
John R. Fowler

7 Metacarpal Shaft Fractures 35
John R. Fowler and Thomas B. Hughes

8 Open Reduction for Carpometacarpal Joint Dislocation 44
John R. Fowler and Robert A. Kaufmann

9 Reconstruction of Acute and Chronic Ulnar Collateral Ligament Injuries of the Thumb 50
John R. Fowler and Robert A. Kaufmann

10 Closed Reduction and Fixation of Bennett and Rolando Fractures 58
John R. Fowler and Thomas B. Hughes

SECTION III JOINTS

11 Volar Plate Arthroplasty of the Proximal Interphalangeal Joint 64
James T. W. Saunders and Amy M. Moore

12 Hemihamate Arthroplasty for the Proximal Interphalangeal Joint Fracture Dislocation 70
David Wei, Mark A. Vitale, and Amy M. Moore

13 Thumb Carpometacarpal Joint Fusion With Locking Plates 79
John M. Felder and Amy M. Moore

SECTION IV WRIST FRACTURES AND CARPAL INSTABILITY

14 Arthroscopic Examination of the Wrist 87
Emily Krauss and Amy M. Moore

15 Ligament Reconstruction for Chronic Scapholunate Dissociation 99
Mark Morris and Kevin C. Chung

16 Lunotriquetral Ligament Reconstruction Using a Slip of the Extensor Carpi Ulnaris Tendon 105
Mark Morris and Kevin C. Chung

17 Fixation of Acute Scaphoid Fractures 113
Ketan Sharma, James T. W. Saunders, and Amy M. Moore

18 Scaphoid Nonunion: Nonvascularized Bone Reconstruction 121
Matthew L. Iorio and Jason H. Ko

19 Scaphoid Fracture Nonunion: Vascularized Bone Reconstruction 128
Matthew L. Iorio and Jason H. Ko

20 Open Reduction and Fixation of Acute Perilunate Fracture Dislocation 137
Grant M. Kleiber and Amy M. Moore

21 Dorsal Capsulodesis for Scapholunate Stabilization With Extensor Carpi Radialis Longus Tenodesis 147
Mark Morris and Kevin C. Chung

22 Proximal Row Carpectomy 153
Patrick Reavey and Amy M. Moore

SECTION V DISTAL RADIUS FRACTURES

23 Distal Radius Fractures 161
Shoshana W. Ambani and Kevin C. Chung

Copyright © 2019 Wolters Kluwer, Inc. Unauthorized reproduction of the contents is prohibited.

Chung-Hand1e9781975127374-FM.indd 9 3/8/2019 9:04:01 PM

SECTION VI RHEUMATOID ARTHRITIS

24 Rheumatoid Arthritis of the Hand and Wrist 179
Shoshana W. Ambani and Kevin C. Chung

SECTION VII DEGENERATIVE DISEASE

25 Degenerative Disease of the Hand and Wrist 204
Shoshana W. Ambani and Kevin C. Chung

SECTION VIII NERVE CONDITIONS

26 Carpal Tunnel Release 225
Angelo B. Lipira and Jason H. Ko

27 Ulnar Tunnel Syndrome 234
Mary Claire Manske and Jason H. Ko

28 Cubital Tunnel Syndrome 240
Mary Claire Manske and Jason H. Ko

29 Radial Tunnel Decompression 248
Joseph Pirolo and Jason H. Ko

30 Primary Nerve Repair and Nerve Graft for Traumatic Nerve Injuries 252
Sonya Paisley Agnew and Jason H. Ko

31 Tendon Transfers for Median Nerve Injury 260
Rafael J. Diaz-Garcia and Kevin C. Chung

32 Tendon Transfers for Ulnar Nerve Injury 267
Rafael J. Diaz-Garcia and Kevin C. Chung

33 Tendon Transfers for Radial Nerve Injury 273
Rafael J. Diaz-Garcia and Kevin C. Chung

34 Tendon Transfers for Combined Median and Ulnar Nerve Injury 280
Kate Elzinga and Kevin C. Chung

35 Distal Anterior Interosseous Nerve Transfer to Motor Branch of Ulnar Nerve 291
Shelley S. Noland and Jason H. Ko

36 Nerve Transfers for High Radial Nerve Palsy 296
Shelley S. Noland and Jason H. Ko

SECTION IX TENDON CONDITIONS

37 Acute Repair of Flexor Tendon Injuries 302
Jacques A. Machol IV, Neal C. Chen, and Kyle R. Eberlin

38 Repair of Multiple Flexor Tendon Injury at Wrist Zone V (Spaghetti Wrist) 309
Jacques A. Machol IV, Neal C. Chen, and Kyle R. Eberlin

39 Staged Flexor Tendon Grafting and Pulley Reconstruction 313
Richard Tosti, Jacques A. Machol IV, and Neal C. Chen

40 Tenolysis of Flexor Tendons 321
Richard Tosti, Jacques A. Machol IV, and Neal C. Chen

41 Acute Repair of Extensor Tendon Injuries in Zones I to VI 326
Michael Smith, Jacques A. Machol IV, and Neal C. Chen

42 Stabilization of Extensor Carpi Ulnaris Tendon Subluxation With Extensor Retinaculum 333
Michael Smith, Jacques A. Machol IV, and Neal C. Chen

43 Trigger Finger Release 338
Donato Perretta, Jacques A. Machol IV, and Neal C. Chen

44 First Dorsal Compartment (de Quervain) Release 341
Donato Perretta, Jacques A. Machol IV, and Neal C. Chen

SECTION X FLAPS AND MICROSURGERY

45 Flap Coverage of Fingertip Injuries 344
Kate Elzinga and Kevin C. Chung

46 Flap Coverage of Thumb Defects 353
Kate Elzinga and Kevin C. Chung

47 Reverse Flow Radial Forearm Flap 362
Kate Elzinga and Kevin C. Chung

48 Ulnar Artery Perforator Flap 368
Kate Elzinga and Kevin C. Chung

49 Posterior Interosseous Artery Flap 374
Kate Elzinga and Kevin C. Chung

50 Free Lateral Arm Flap 382
John R. Lien and Kevin C. Chung

51 Pedicled and Free Groin Flap 385
Mark Morris and Kevin C. Chung

52 Free Anterolateral Thigh Flap 392
John R. Lien and Kevin C. Chung

53 Revascularization and Replantation of Digits 395
Mark Morris and Kevin C. Chung

54 Digital Artery Sympathectomy 404
John R. Lien and Kevin C. Chung

55 Ulnar Artery to Superficial Arch Bypass With a Vein Graft for Ulnar Artery Thrombosis 408
Mark Morris and Kevin C. Chung

Copyright © 2019 Wolters Kluwer, Inc. Unauthorized reproduction of the content is prohibited.

56 Second Toe to Thumb Transfer 416
John R. Lien and Kevin C. Chung

SECTION XI DUPUYTREN DISEASE

57 Dupuytren Contracture 424
John R. Lien and Kevin C. Chung

SECTION XII SPASTIC CONDITIONS

58 Elbow Extension Procedures 434
Paymon Rahgozar and Kevin C. Chung

59 Wrist Extension Procedures 444
Paymon Rahgozar and Kevin C. Chung

60 Finger Extension Procedures 449
Paymon Rahgozar and Kevin C. Chung

61 Lateral Key Pinch Reconstruction 454
Paymon Rahgozar and Kevin C. Chung

62 Grasp Improvement Procedures 458
Paymon Rahgozar and Kevin C. Chung

SECTION XIII CONGENITAL HAND DISORDERS

63 Release of Finger Syndactyly Using Dorsal Rectangular Flap 464
Amir H. Taghinia

64 Hypoplastic Thumb Reconstruction 473
Amir H. Taghinia

65 Reconstruction of Radial Polydactyly 482
Amir H. Taghinia

66 Index Finger Pollicization for Hypoplastic Thumb 491
Amir H. Taghinia, Brian I. Labow, and Joseph Upton

67 Second Toe-to-Thumb Transfer for Hypoplastic Thumb 498
Amir H. Taghinia, Brian I. Labow, and Joseph Upton

68 Reconstruction of Amniotic Constriction Bands 507
Amir H. Taghinia

69 Centralization for Radial Longitudinal Deficiency 514
Amir H. Taghinia, Brian I. Labow, and Joseph Upton

70 Excision of Vascular Malformation of the Hand 523
Amir H. Taghinia

SECTION XIV TUMORS

71 Lumps and Bumps of the Hand and Wrist 528
Paymon Rahgozar and Kevin C. Chung

72 Excision of Glomus Tumors 535
Paymon Rahgozar and Kevin C. Chung

73 Excision of Hemangioma of the Hand 539
Paymon Rahgozar and Kevin C. Chung

74 Excision of Metacarpal Enchondroma 543
Paymon Rahgozar and Kevin C. Chung

75 Excision of Peripheral Nerve Schwannoma 547
Paymon Rahgozar and Kevin C. Chung

76 Excision of Malignant Skin Tumors 551
Paymon Rahgozar and Kevin C. Chung

Index 557

Copyright © 2019 Wolters Kluwer, Inc. Unauthorized reproduction of the content is prohibited.

Section I: Anesthesia and Emergency Procedures

1 CHAPTER

Anesthesia and Emergency Procedures

John R. Lien and Kevin C. Chung

Copyright © 2019 Wolters Kluwer, Inc. Unauthorized reproduction of the content is prohibited.

DEFINITION

- Wrist and digital blocks are essential for patient anesthesia in the operating room and during emergency room procedures.
- Nerve blocks assist with postoperative pain control.
- Wide-awake local anesthesia no tourniquet (WALANT) involves local injection of epinephrine with lidocaine for hemostasis and anesthesia instead of applying a tourniquet and sedation. This technique is useful for minor hand procedures as well as tendon surgery.

ANATOMY

- Median nerve
  - At the distal forearm/wrist, the median nerve lies between the palmaris longus (PL) and flexor carpi radialis (FCR) tendons (FIG 1).
  - The palmar cutaneous branch (PCB) usually passes subcutaneously between the FCR and PL tendons.

FIG 1 • Median nerve anatomy at volar wrist.

FIG 2 • Ulnar neurovascular bundle anatomy at volar wrist.

- Ulnar nerve
  - At the wrist level, the ulnar nerve is radial and dorsal to the flexor carpi ulnaris (FCU) tendon (FIG 2).
  - The ulnar artery is adjacent to the radial aspect of the ulnar nerve.
  - The dorsal cutaneous branch (DCB) originates from the ulnar nerve approximately 5 cm proximal to the ulnar styloid. It crosses from palmar to dorsal near the styloid process.[1]
- Superficial branch of the radial nerve
  - The superficial branch of the radial nerve (SBRN) becomes subcutaneous approximately 9 cm proximal to the radial styloid.[2]
  - At the radial styloid, there are two to three branches of the SBRN in the subcutaneous tissue (FIG 3).
- Digital nerves
  - Four nerve branches (two palmar, two dorsal) provide sensation to each digit.
  - The common digital nerves bifurcate to the proper digital nerves at the level of the distal palmar crease.

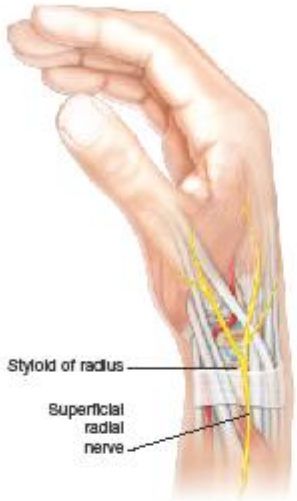

FIG 3 • Superficial branch of the radial nerve anatomy at the radial wrist.

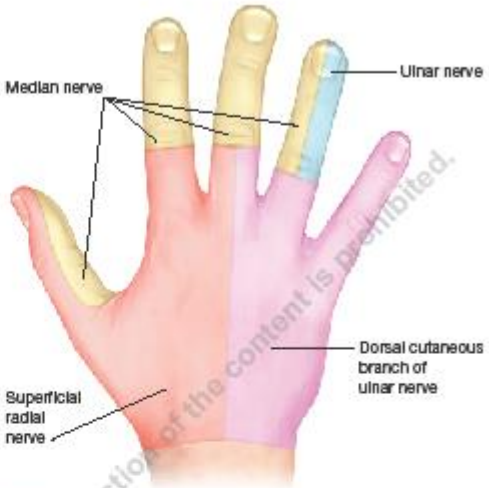

FIG 4 • Dorsal hand sensory innervation.

- The dorsal digital nerves of the thumb and small finger extend to the tip of the dorsal digit.
- The volar digital nerves supply dorsal sensation distal to the proximal interphalangeal joint in the index, middle, and ring fingers (**FIG 4**).

SURGICAL MANAGEMENT

Preoperative Planning

- Materials
  - Syringe
  - 27-gauge needle
  - Commonly used local anesthetic agents and additives
    - Lidocaine is commonly used due to its rapid onset (within 2–5 minutes of injection) and medium duration of action (2 hours for digital block).[3]
    - Bupivacaine has a slower onset of action (5–10 minutes) but longer duration of action (12 hours for digital block).[3]
    - Epinephrine additive induces vasoconstriction, which promotes hemostasis, prolongs duration of anesthesia, and reduces the systemic toxicity of the local anesthetic agent.
    - Sodium bicarbonate 8.4% additive buffers the low pH of lidocaine, decreasing injection pain.

Positioning

- Whether the procedure is in the operating room or emergency department, the patient should lie comfortably supine to minimize patient movement during the procedure.
- Hand table or Mayo stand.

Approach

- Digital block
  - Volar subcutaneous approach: This is our preferred technique as it only requires one injection and is shown to be less painful than the transthecal approach.[4]
  - Dorsal transmetacarpal approach
  - Transthecal approach
- Wrist block
  - Median nerve
  - Ulnar nerve
  - Superficial branch of radial nerve
- WALANT
  - Use 1% lidocaine with 1:100 000 epinephrine
  - Buffer the lidocaine and epinephrine in a 10:1 ratio with 8.4% sodium bicarbonate
  - Allow adequate time for the vasoconstrictive effect of epinephrine to take effect (25 minutes).[5]
- Volume of injection depends on the site of surgery (**FIG 5**).[6]

Copyright © 2019 Wolters Kluwer, Inc. Unauthorized reproduction of the content is prohibited.

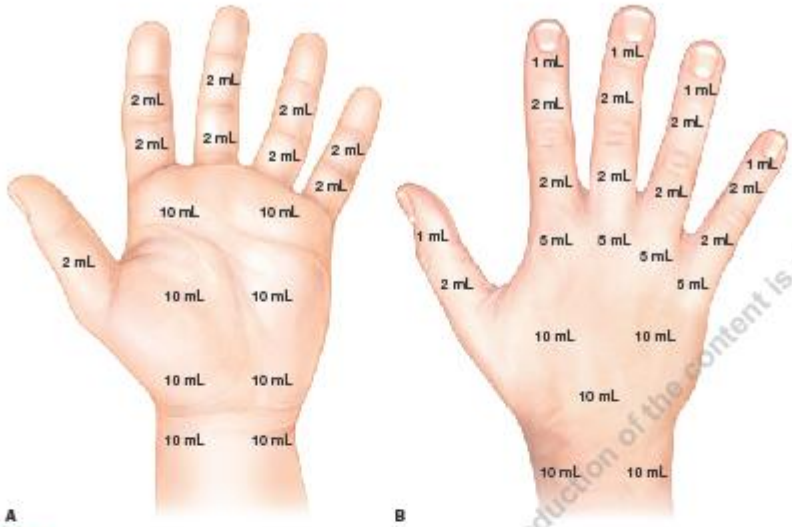

FIG 5 • Palmar (**A**) and dorsal (**B**) hand injection volumes.

Copyright © 2019 Wolters Kluwer, Inc. Unauthorized reproduction of the content is prohibited.

TECHNIQUES

Digital Nerve Block

Volar Subcutaneous Block

- Insert a 27-gauge needle at the distal palmar crease at the level of the A1 pulley (**TECH FIG 1**).
- Inject 3 mL of local anesthetic into the subcutaneous tissue. The anesthetic should cause tumescence and flow of anesthetic solution radial and ulnar to the flexor tendon sheath (see **FIG 5A**). If there is significant resistance to injection, withdraw the needle slightly.

Dorsal Transmetacarpal Block

- Identify the metacarpal head of the digit of interest.
- At this level, introduce a 27-gauge needle from the dorsal web space and advance toward the palm (**TECH FIG 2**).

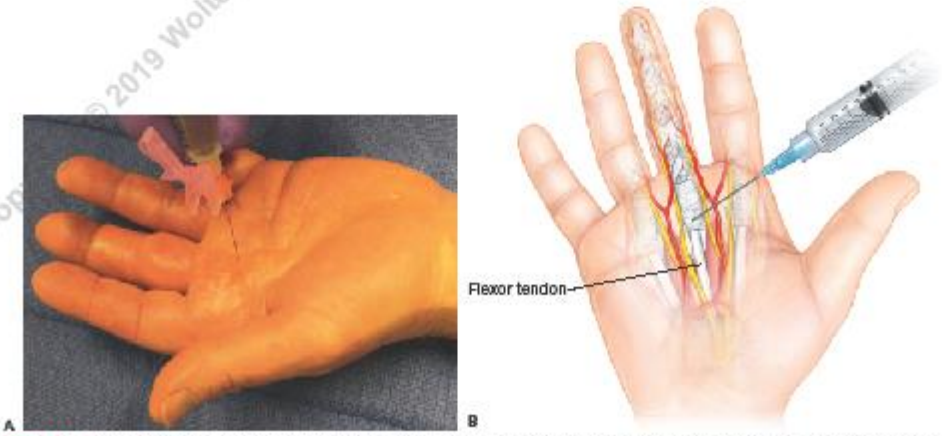

TECH FIG 1 • Middle finger volar subcutaneous block. Note tumescence radial and ulnar to the flexor tendon sheath in **A**. Note the needle is in the subcutaneous tissue superficial to the flexor tendon sheath in **B**.

A

B

TECH FIG 2 • Dorsal transmetacarpal block.

- Inject 2 mL of local anesthetic into the radial and ulnar web space to anesthetize each digital nerve. Periodically aspirate the syringe to prevent intravascular injection.

Transthecal Digital Block

- Palpate the flexor tendon sheath at the palmar digital crease.
- Insert a 25-gauge needle through the flexor tendon at this level until contact with bone.
- After bone contact, slowly withdraw the needle with gentle pressure on the syringe (**TECH FIG 3**).
- When the needle is withdrawn 1 to 2 mm, anesthetic will enter the sheath.
- Inject 2 mL of local anesthetic.

A

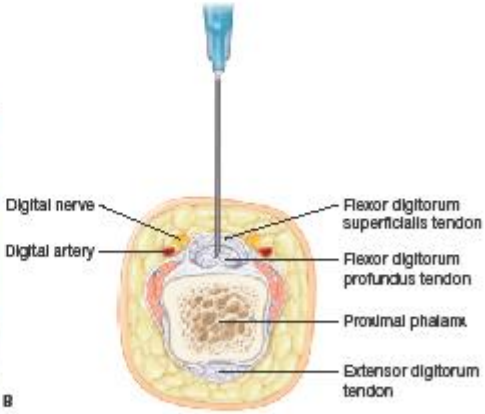

B

TECH FIG 3 • **A.** Transthecal digital block. **B.** Cross-section view.

Copyright © 2019 Wolters Kluwer, Inc. Unauthorized reproduction of the contents is prohibited.