

BASICS

section **1**



COPYRIGHTED MATERIAL

chapter 1

Epidermis in Clinical Dermatology



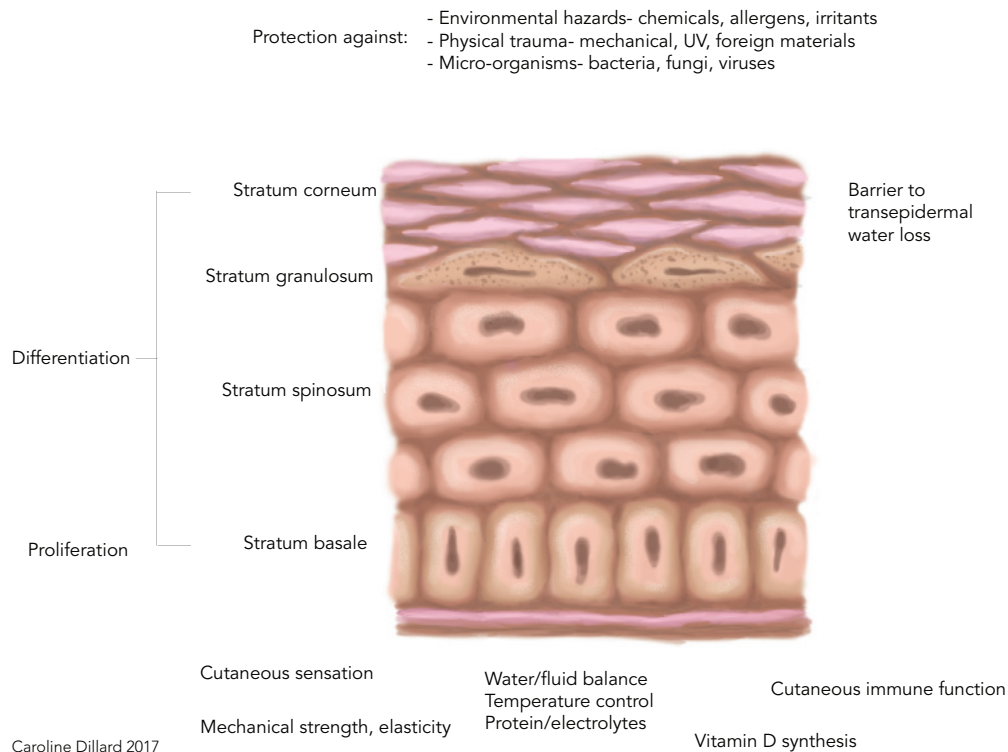
DEFINITION/OVERVIEW

- The skin is the largest organ in the body.
- Functions of the skin include (among others):
 - Physical barrier
 - Thermoregulation
 - Environmental protection
 - Immunoregulation
 - Sensory perception
 - Antimicrobial activity.
- The skin can renew itself and thus respond to a variety of hostile factors.
- The process of cell migration within the epidermis from the stratum basale to the stratum corneum (epidermal renewal) takes approximately 22 days.
- Epidermal renewal time line can be useful when discussing duration necessary for clinical improvement.
- A helpful correlation for the client may be to compare epidermal renewal to the short length of time that a suntan will last.
- The process of renewing the epidermis is a series of complex organized steps of:
 - Controlled cell renewal
 - Cell death
 - Cell removal.
- The epidermis – more specifically, the stratum corneum or “skin barrier” – has recently been the focus of research regarding the pathobiomechanisms of disease as well as for therapeutic advances.

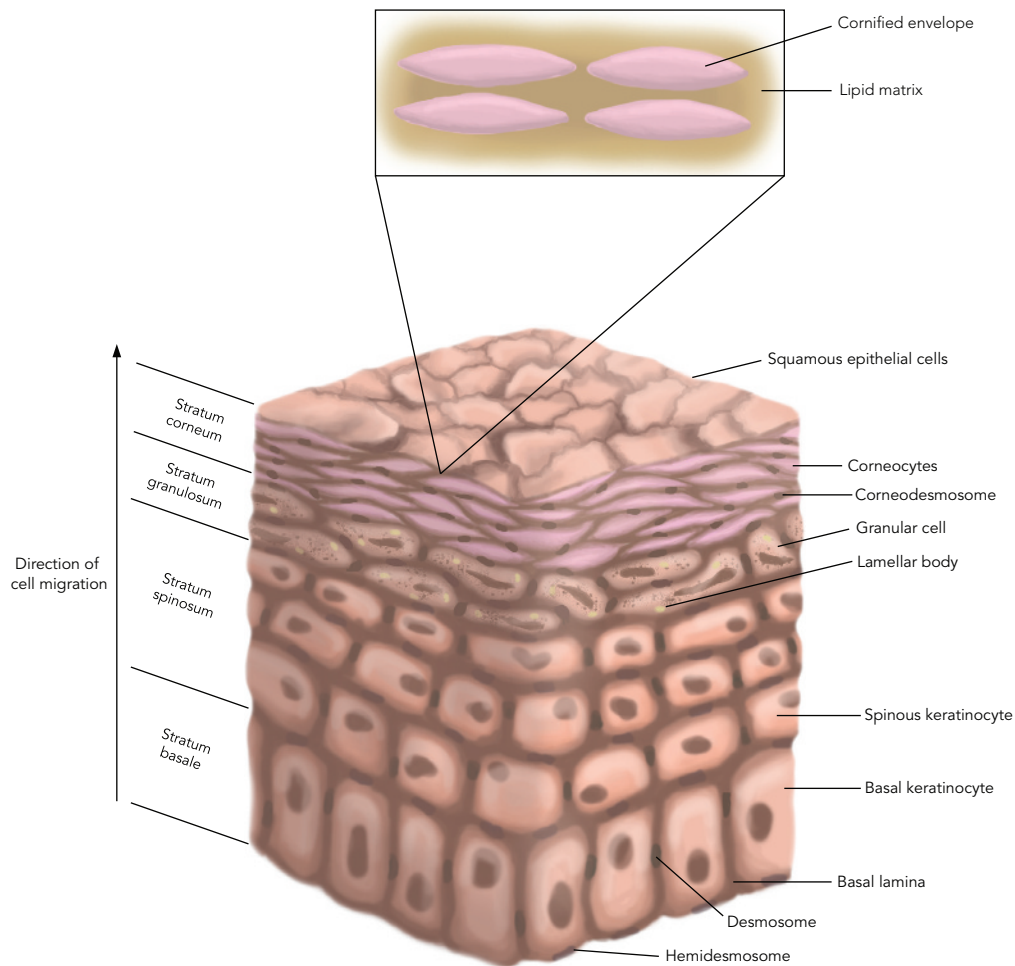
4 BASICS

STRATUM CORNEUM BARRIER

- The outer portion of the epidermis, the stratum corneum, is composed of approximately 20 overlapping layers and is considered the skin's barrier. The stratum corneum layer (Figures 1.1, 1.2):
- Controls hydration by restricting water movement into and out of the skin. (i.e., 0.5 mL water vapor is lost through the normal stratum corneum per day in human skin)
- Is the primary defense against environmental hazards such as allergens, pollutants, and irritants by continuous desquamation (renewal and removal)
- Maintains homeostasis with commensal organisms via the production of antimicrobial peptides
- Absorbs UV light to protect sensitive underlying tissue.



■ **Fig. 1.1.** Epidermal influence on homeostasis. Courtesy of Caroline Dillard.



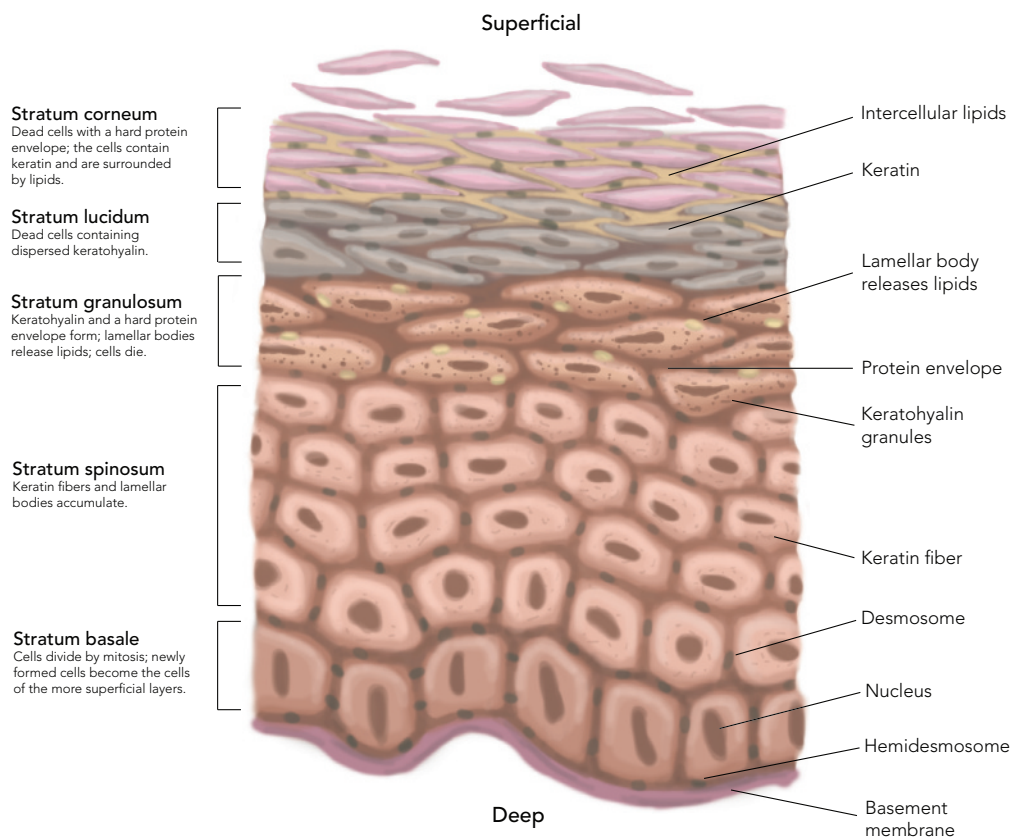
■ **Fig. 1.2.** Layers of the epidermis. Courtesy of Caroline Dillard.

PROCESS OF CORNIFICATION/KERATINIZATION

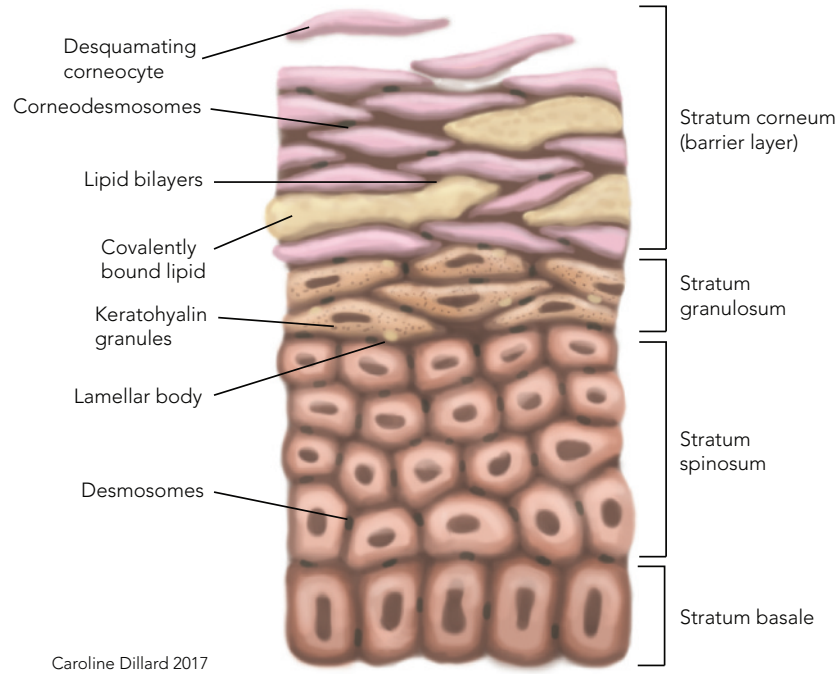
- Outline of basic steps in the cornification process to form the skin barrier (Figure 1.3).
 - Step 1: bundling of keratin within the corneocyte (keratinocyte) (Figure 1.4).
 - Step 2: replacement of the cell membrane with a thick cornified envelope (Figure 1.5).
 - Step 3: formation of lamellar lipid bilayers (Figure 1.6).
 - Step 4: desquamation (Figure 1.7).

6 BASICS

- The final product of cornification is a tough hydrophobic “bricks and mortar” layer (Figure 1.8).
- The entire process of cell migration from the stratum basale to stratum corneum during normal cornification takes approximately 22 days in the dog.
- Understanding the specific steps of cornification is vital to the understanding of various clinical disorders.
- Defects in one small step of the cornification process can influence the entire process.

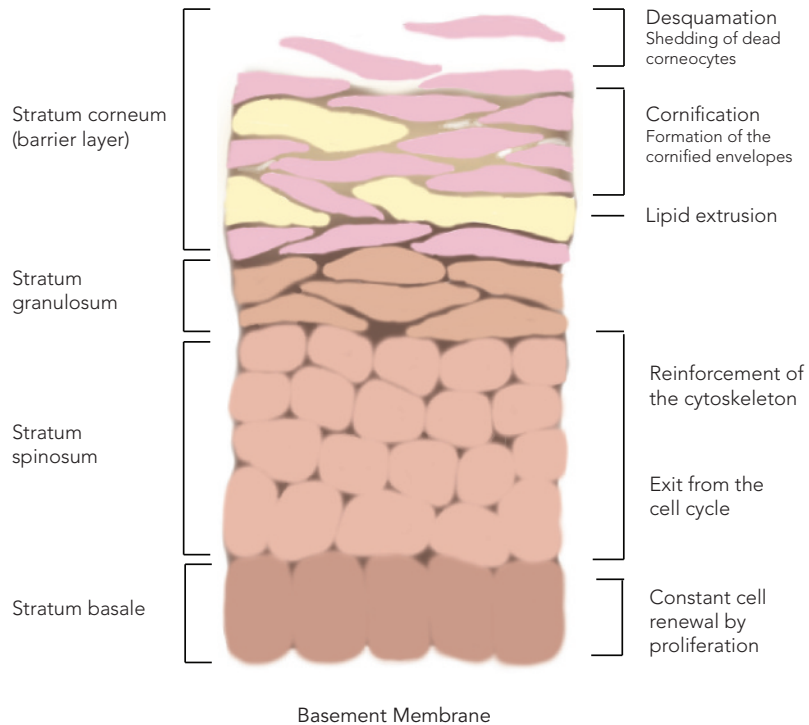


■ **Fig. 1.3.** Simplified process of cornification/keratinization. Courtesy of Caroline Dillard.



Caroline Dillard 2017

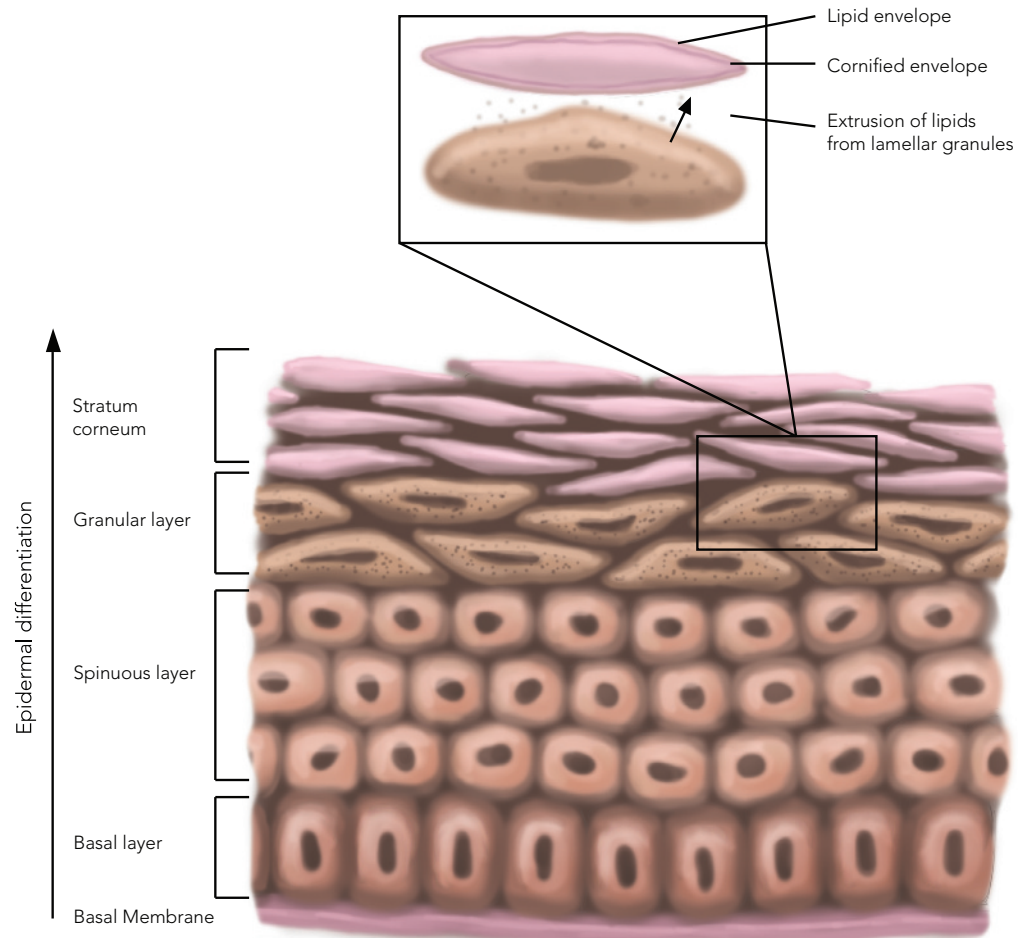
■ **Fig. 1.4.** Cornification step 1, bundling of keratin. Cell nuclei and organelles undergo proteolysis. Profilaggrin in keratohyalin granules of the stratum granulosum layer dephosphorylates to filaggrin. Filaggrin bundles loose keratin filaments in the cell into a core unit. Courtesy of Caroline Dillard.



Caroline Dillard 2017

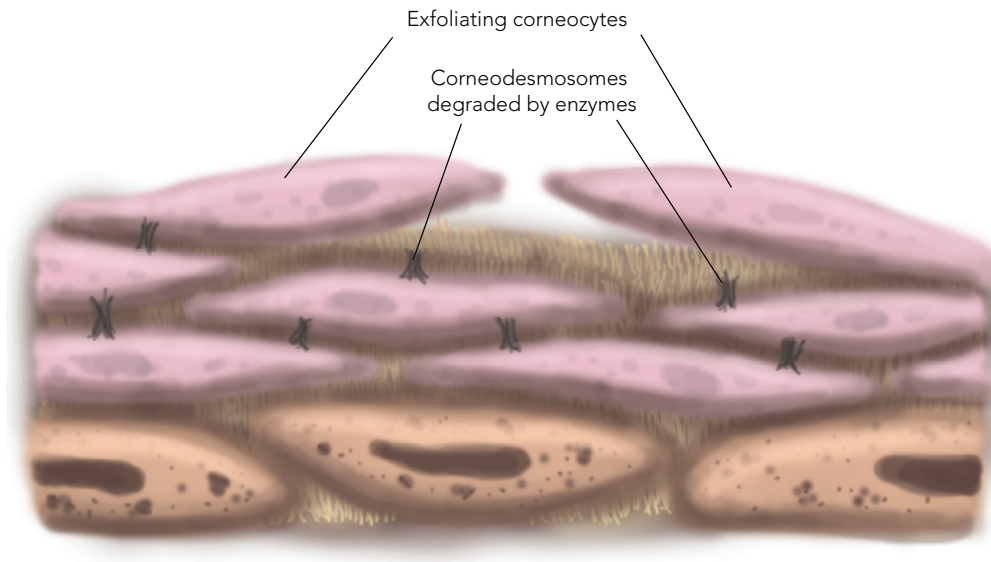
■ **Fig. 1.5.** Cornification step 2, transformation of the cell membrane into a cell envelope. Transglutaminases mediate calcium-dependent cross-linking of small peptides. Plasma membrane of the keratinocyte becomes a tough protein layer called the corneocyte envelope. Courtesy of Caroline Dillard.

8 BASICS

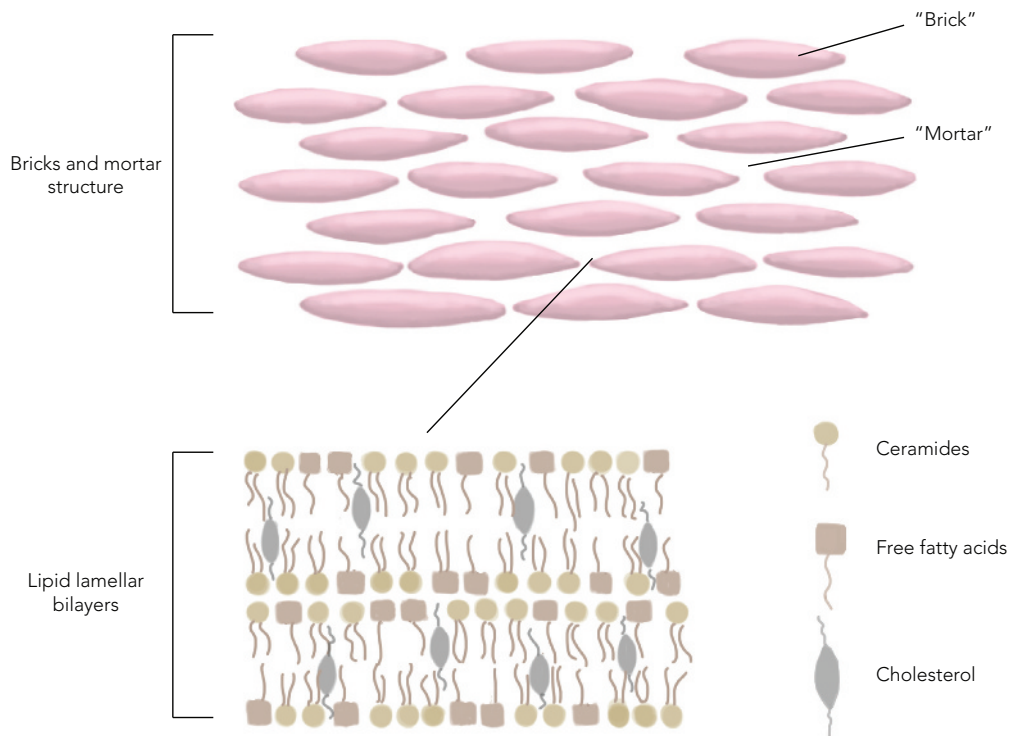


Caroline Dillard 2017

■ **Fig. 1.6.** Cornification step 3, formation of lipid bilayers. Lamellar bodies (small organelles containing lipid) are formed in the stratum spinosum. Lipid is secreted into the intercellular spaces at the level of the stratum granulosum and stratum corneum and forms into lamellar bilayers. Intercellular lipids include cholesterol, long-chain fatty acids, and ceramides. Courtesy of Caroline Dillard.



■ **Fig. 1.7.** Cornification step 4, desquamation. Proteases cleave intercorneocyte adhesions (desmosomes). Squames (exfoliating corneocytes), seen as scales or flakes, are released into the environment. Courtesy of Caroline Dillard.



■ **Fig. 1.8.** Final product of cornification is a tough hydrophobic "bricks and mortar" layer that is a biochemically active barrier; bricks (corneocytes) and mortar (lipid). Courtesy of Caroline Dillard.

CATEGORIES OF SKIN BARRIER IMPAIRMENT

- Disorders can be divided into primary and secondary issues.
- Primary: defects in proteins or enzymes necessary for normal cornification.
- Secondary: inflammatory disorders that may have a negative effect on skin barrier function.
- An extensive list of factors (enzymes, proteins, etc.) can influence and regulate the process.
- Alteration in any step can lead to barrier dysfunction and abnormalities in permeability leading to clinical disorders (e.g., canine ichthyosis).
- There is much discussion regarding the relationship of atopic dermatitis and skin barrier function.
 - It is not currently known if there is a primary defect in these patients or if the alterations in the skin barrier are secondary to inflammation.
 - Most studies have shown some level of skin barrier abnormality in dogs with atopic dermatitis – functionally, chemically, and ultrastructurally.
 - The concept of skin barrier “repair” has also become important therapeutically (oral and topical).
 - Measurement of transepidermal water loss (TEWL) is a common tool to assess skin barrier function.



COMMENTS

- The skin is the only anatomic and physiologic barrier between the animal and the surrounding environment.
- It is not a simplistic cover but a living, vital, responsive organ.
- The skin has certain predictable reaction patterns (erythema, lichenification, etc.) that can aid the clinician in the establishment of a list of differential diagnoses.
- The skin may also relay information and clues regarding systemic processes (cutaneous manifestations of systemic disease).
- The skin is the most visible organ of the body, making it of vital concern for pet owners.