

COPYRIGHTED MATERIAL

## **Section 1 Surgery of the Skin**



# Chapter 1

## Primary Wound Closure

Wound healing starts almost immediately after skin incision. Initially, blood clots form to seal the wound and provide a scaffold for cell migration. The inflammatory phase of healing starts about 6 hours after injury. White blood cells migrate into the wound to begin debridement. They also release cytokines, growth factors, and other chemicals that stimulate vessel ingrowth and tissue repair. Three to five days after injury, granulation tissue begins to replace the fibrin plug that fills the wound. Up to this point, wound strength is relatively poor. As collagen content increases, the wound gradually becomes stronger. The greatest rate of collagen accumulation occurs between 7 and 14 days after injury. After 2 to 3 weeks, the wound begins to mature as collagen content and fiber orientation change.

In clean, incised, sutured wounds, epithelium migrates across the gap within 48 hours. Epithelium will also grow downward into the incision and around sutures, making tracts that can give the appearance of infection. By 10 to 15 days after wounding, these epithelial ingrowths regress.

Wound healing can be affected by a variety of factors, including motion, tension, poor blood supply, anemia, malnutrition, corticosteroids, radiation, and antineoplastic drugs. Systemic diseases such as diabetes mellitus, hepatic or renal dysfunction, feline leukemia, or hyperadrenocorticism may delay healing. Healing is also prolonged when wounds are edematous or infected or contain foreign material or necrotic debris. The use of lasers to incise the skin will increase inflammation and risk of necrosis and decrease wound tensile strength and cosmesis compared with scalpel blade incisions. Rate of wound healing varies with species; for instance, incised wounds in cats gain strength more slowly than in dogs.

In general, primary wound closure is more likely to be successful when Halsted's principles of surgery are followed. These include gentle tissue handling, accurate hemostasis, preservation of adequate blood supply, strict asepsis, avoidance of tension, careful tissue approximation, and obliteration of dead space. In dogs and cats, skin wounds are often closed in two layers. The subcutaneous tissue is closed to reduce bleeding, dead space, and tension, and the dermis is apposed to promote rapid epithelialization.

## Preoperative management

Diagnostics and supportive care depend on the individual patient's status. Prophylactic antibiotics (one dose administered intravenously at induction and a second dose 1.5 to 6 hours later) should be considered for prolonged surgical procedures, since infection rates double when surgery time increases from 60 to 90 minutes. Wounds should be widely clipped and prepped, especially when drain placement or skin advancement is required.

## Surgery

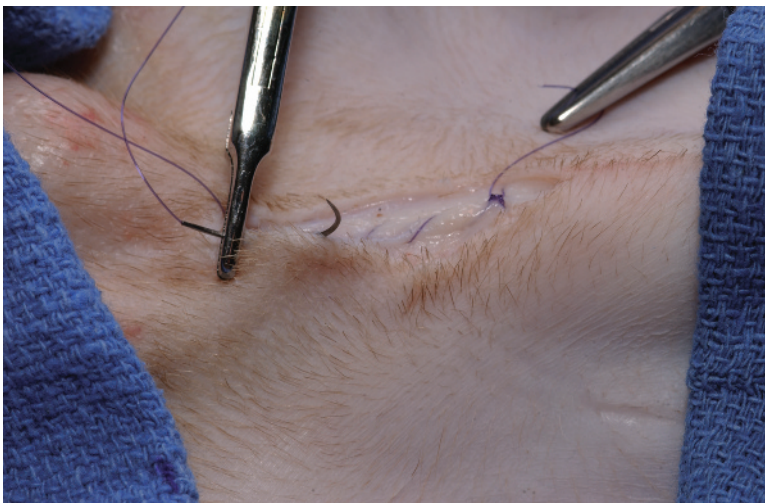Subcutaneous and skin closure can be performed with interrupted or continuous suture patterns. Interrupted patterns are preferred when wounds are under tension or tissue integrity is questionable. Continuous patterns are faster to perform and, when used in the subcutis, leave less foreign material within the wound. Skin sutured in a continuous pattern is more likely to dehisce if the site is traumatized after surgery or the sutures cut through the tissues. A cruciate suture pattern provides the benefits of an interrupted closure while decreasing surgical time. Cruciate sutures can be tied with a gap between the first and second throw to permit postoperative relaxation if tissues swell.

Skin apposition with a buried intradermal pattern may provide a more cosmetic appearance compared with a simple interrupted pattern. Intradermal patterns are difficult to perform on thin skin or long or irregular incisions. Short incisions, such as ovariohysterectomy and castration sites, can be rapidly closed with a running subcutaneous-to-intradermal pattern. With this technique, the subcutaneous closure is continued directly into an intradermal pattern, which is tied off to the original subcutaneous suture end.

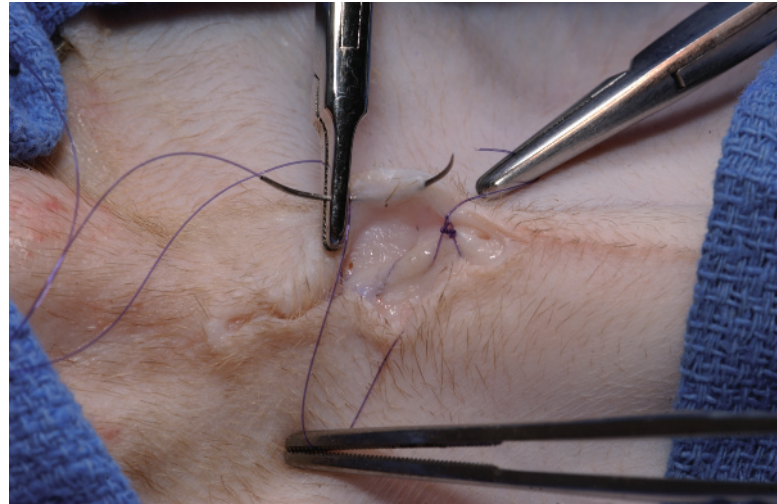
In most animals, subcutaneous tissues are closed with 3-0 absorbable monofilament suture material on a taper needle. Intradermal patterns are performed with 3-0 or 4-0 absorbable suture material on a cutting or taper needle. In large dogs, the intradermal layer can also be closed with 2-0 monofilament absorbable suture on a taper needle. Suture materials that absorb in  $\leq 120$  days are preferred. Skin is usually closed with 3-0 nylon or another nonabsorbable material. The size of the suture bites and the distance between sutures depend on the thickness of the skin.

During knot tying, sutures may inadvertently form half hitches when uneven tension is placed on the suture ends. Frequently, a right-handed person pulls too hard on the right end of the suture (usually the short or looped end) because of a tendency to overuse the dominant hand. Also, many surgeons throw the needle holder into the suture when tying a knot. This lifts up on the suture, hitching a previously square throw. A half-hitched throw is easy to identify: one end of the suture will stand straight up while the other end lies flat. With a square throw, both suture ends will lie flat. Surgeon's knots, in which the first throw is doubled, are harder to hitch than knots made of single throws, since the double throw provides more friction and resists tension. Surgeon's knots provide the same security as simple square knots. Hitching can be prevented by placing the needle holder directly over the incision line, wrapping the suture around the needle holder with the nondominant hand, and pulling the suture ends evenly while watching the throw settle directly over the incision line. The throw should remain in a horizontal orientation as it is being tightened. With some monofilament sutures, it may be necessary to pull harder with the nondominant hand to square a throw.

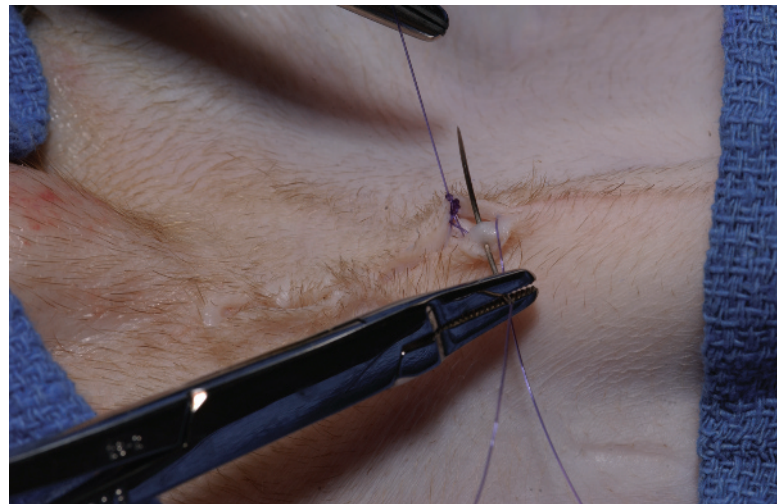
1. Start the subcutaneous suture at the far end of the incision, opposite from where you would normally start your intradermal pattern. For example, closure of the subcutis of an abdominal incision would start at the left end of the incision for a right-handed surgeon standing on the dog's right.
2. In the subcutaneous tissues, take a bite perpendicular to the incision line at one end of the surgical wound.
3. Tie two knots, leaving the free end at least 2.5 cm long. Place a hemostat on the free end of the suture to keep it out of the way (fig. 1-1).
4. Perform a simple continuous subcutaneous closure.
  - a. For incisions with minimal subcutaneous tissue, take full-thickness bites that include the cut edge of the subcutaneous tissue on each side.
  - b. For incisions with wide areas of exposed subcutaneous fat, use a pattern similar to a Lembert. On one side of the incision, insert the needle in and out of the subcutaneous fat near, and perpendicular to, the skin edge. Take a similar bite on the opposite side of the incision. This will invert the cut edge of the subcutis, leaving a smooth closure.
5. Continue the subcutaneous closure to the end of the incision.
6. Once the near end of the incision is reached, begin the intradermal pattern from that end (fig. 1-1), taking long, overlapping bites oriented parallel to the skin margin (fig. 1-2).
  - a. No knot is needed. The first bite starts at the crotch of the incision.
7. At the end of the incision line, take a final dermal bite from superficial to deep (fig. 1-3). The bite should enter the dermis and exit out the subcutaneous tissue next to the free end of the original knot.
8. Using four single throws, tie two knots, pulling parallel to the incision line (fig. 1-4). Cut the free end of the suture short.
9. If the knots do not bury, pass the needle end of the suture through the gap in the incision near the knot (fig. 1-5), under the subcutis, and out the skin lateral to the incision line (fig. 1-6) before cutting the needle end.



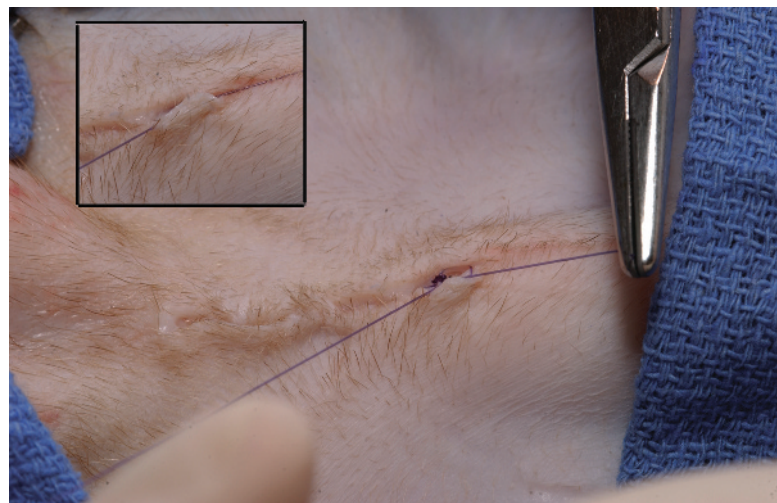
**Figure 1-1** Subcutaneous-to-intradermal pattern. Start the subcutaneous pattern at the far end, leaving the knot end long (hemostat attached in photo). Once you reach the near end of the incision, start immediately into an intradermal pattern.



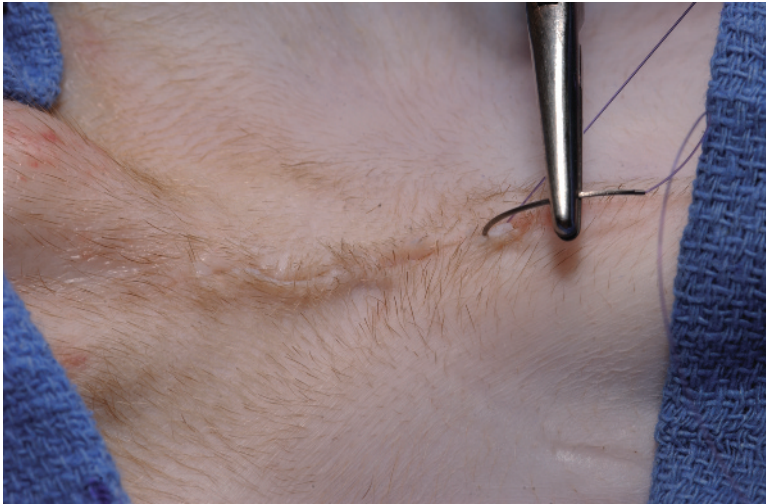
**Figure 1-2** Take long bites in the intradermal layer, slightly overlapping with the bites on the contralateral side.



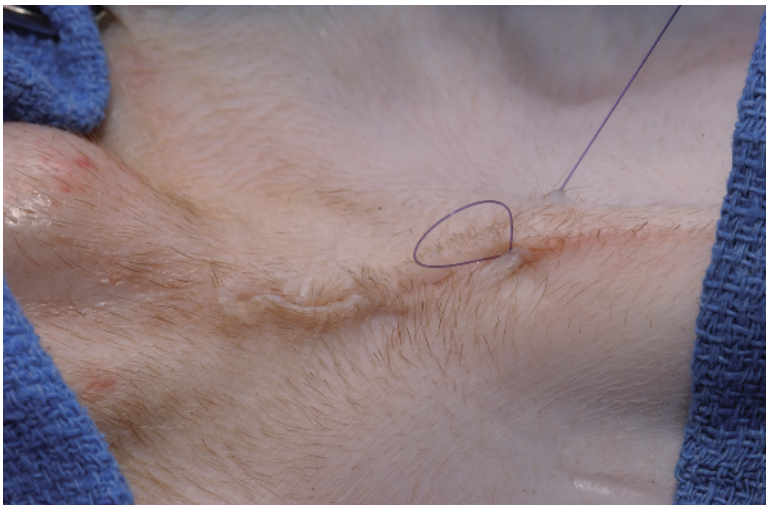**Figure 1-3** Take a final bite at the far end of the incision line from superficial to deep, entering at the intradermal layer and exiting below the subcutis. Make sure that the needle end and knot end of the sutures are adjacent to each other.



**Figure 1-4** Tie four simple throws, pulling lengthwise along the incision line to appose skin edges (inset) and bury the knots.



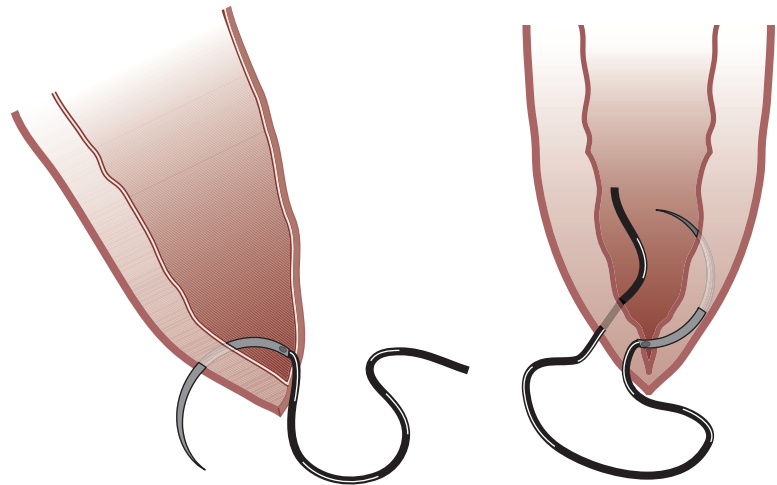
**Figure 1-5** To further bury the knot, pass the needle through the gap in the incision near the knot and under the subcutis.



**Figure 1-6** Exit the needle from the skin laterally and place tension on the suture to pull the knot down and under the subcutis.

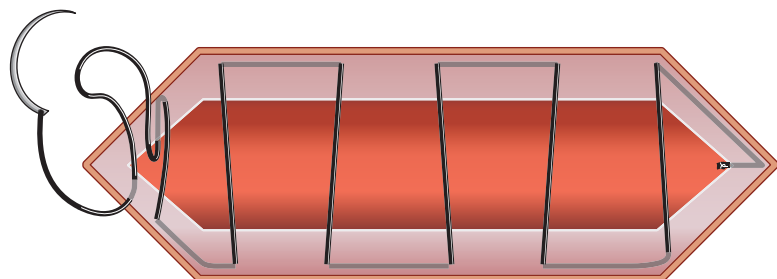
### ***Surgical technique: intradermal pattern***

1. For an incision that is parallel to the long axis of the dog (e.g., an ovariohysterectomy incision), begin the closure at the end of the incision closest to the hand driving the needle holder. In other words, if you are a right-handed surgeon, start at the right end of the incision.
2. In the incision edge closest to you, take a bite from deep to superficial, passing the needle from below the subcutis and up and out of the dermis (fig. 1-7). Position the needle perpendicular to the skin edge during the bite.
3. Cross over to the opposite side and take a bite from superficial to deep, starting at the dermis and passing through and under the subcutis (fig. 1-7).
4. Verify that the two suture ends are adjacent to each other and exiting in front of the portion of the suture that crosses the incision line (on the side of the crossover suture that is away from the end of the incision). The knot will not bury if the crossover suture is between the two suture ends.

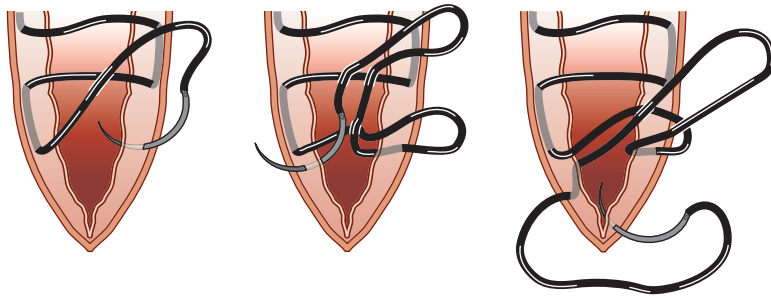


**Figure 1-7** To start the intradermal pattern, take a bite from superficial to deep (left), starting at the dermis and exiting below the subcutis. Take a second bite from deep to superficial (right), starting below the subcutis and exiting at the dermis.

5. Tie four single square throws, pulling horizontally and parallel to (along) the incision line to bury the knots under the subcutis (see fig. 1-4).
6. Take intradermal bites along the incision.
  - a. Gently evert the skin to expose the dermis and facilitate proper suture placement (see fig. 1-2). If possible, grasp the subcutis with thumb forceps instead of the skin when everting.
  - b. Take a bite at least 5 mm long and keep the needle within the dermal layer for the entire bite (fig. 1-2).
  - c. Take a bite on the opposite side of the incision. Start the bite at a level just behind the exit point of the previous bite on the opposite side (fig. 1-8). This will cause the sutures to angle backwards slightly as they cross the incision line, improving apposition.
7. End the last dermal bite 0.5 cm from the end of the incision in animals with thin skin and 1cm from the end of the incision in animals with thick skin.
8. Take a bite on one skin margin from superficial to deep, passing the needle through the dermis and exiting under the subcutis (fig. 1-9). Position the needle perpendicular to the skin edge during the bite.
9. Leave a 2- to 4-cm loop of suture and take a bite on the opposite skin margin from deep to superficial, starting below the subcutis and exiting



**Figure 1-8** Take bites parallel to the skin margins, slightly overlapping with bites on the contralateral side. To begin tying the final knot, take a bite from superficial to deep and then deep to superficial, leaving a loop between the bites.



**Figure 1-9** To bury the final knot, take a bite from superficial to deep (left); leave a loop and take a second bite from deep to superficial (center). Take another bite from superficial to deep (right), and tie this end to the loop.

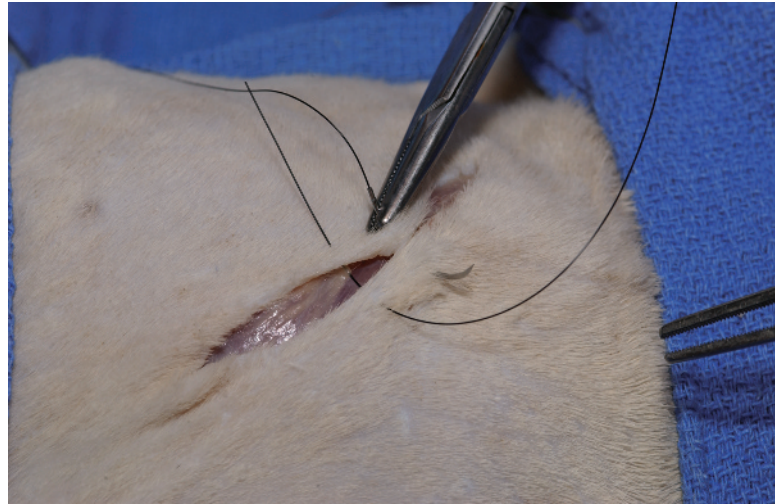
out the dermis (figs. 1-8 and 1-9). Both ends of the loop will now be deep to the subcutis.

10. Cross over to the other side, and take another bite from superficial to deep. Make sure that the needle exits below the subcutis next to the suture loop and the crossover stitch does not come between the loop and needle end (fig. 1-9).
11. Using four single throws, tie two knots, pulling parallel to (along) the incision line (fig. 1-4).
12. If the knots are not buried, tuck the knot under the subcutis before cutting the needle end.
  - a. Cut off the free end of the knot.
  - b. Reload the needle.
  - c. Palm the needle holder and insert the needle, pointed straight down, adjacent to the knot so that the needle passes into the incisional gap (fig. 1-5).
  - d. Pass the needle under the subcutaneous tissues.
  - e. Bring the needle up and out of the skin to one side of the incision (fig. 1-6).

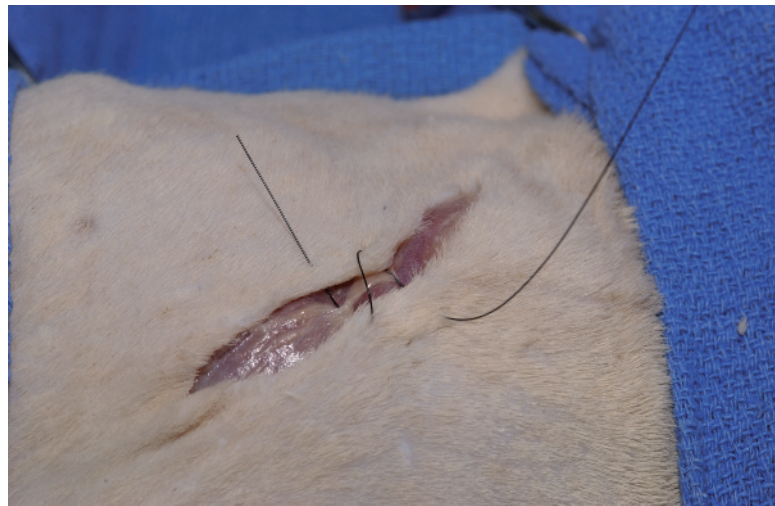Lift firmly up on the suture to pull the knot down through the incisional gap. Cut off the remaining suture end.

### ***Surgical technique: cruciate pattern***

1. Take a bite through the far skin margin 0.5 to 1 cm from the edge. Exit out the near skin margin the same distance from the edge, and pull most of the suture through the skin.
2. Take a second, similar bite, 0.5 to 1 cm parallel to the first (figs. 1-10 and 1-11).
3. Tie a surgeon's throw, tightening the suture so that it is in contact with the skin without compressing it (fig. 1-12).
4. Tie a second throw, leaving a small loop between it and the surgeon's throw as you tighten.
5. Tie the third and fourth throws to the second throw to form a secure knot above the loop (figs. 1-12 and 1-13).



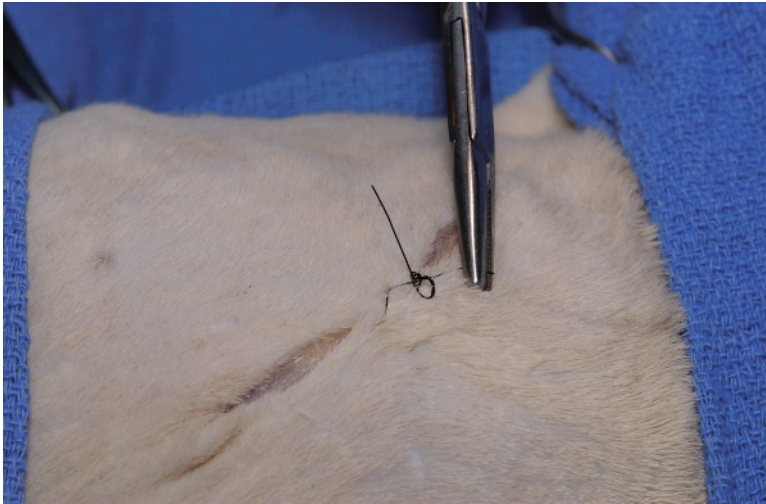
**Figure 1-10** Cruciate suture. Take bites perpendicular to the skin edges.



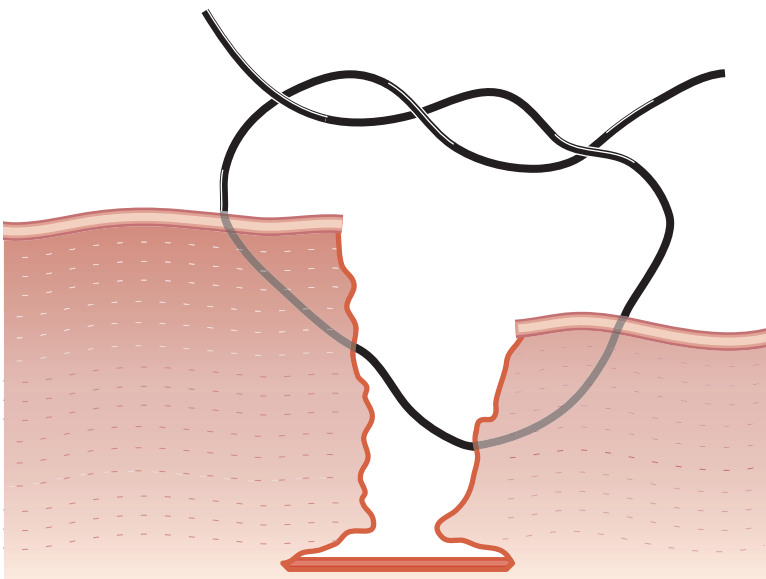
**Figure 1-11** The second bite is parallel to the first.



**Figure 1-12** If there is tension on the skin line, tie a surgeon's throw to appose skin margins and leave a small loop between the surgeon's throws and the remaining throws.



**Figure 1-13** Final appearance. The skin should lie flat.

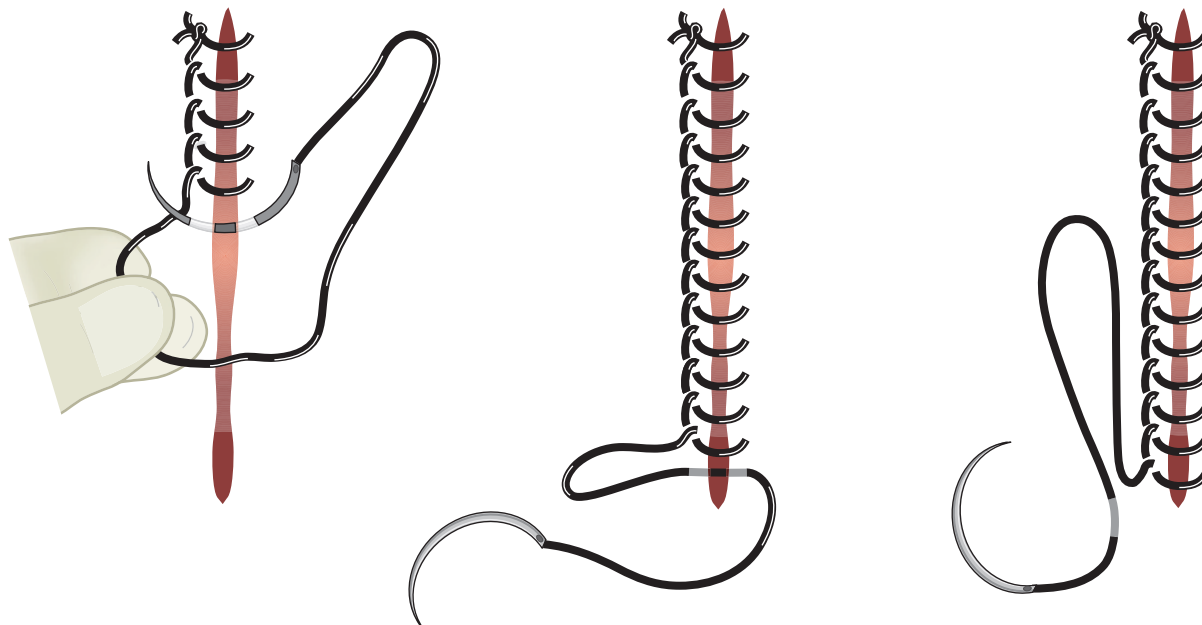


**Figure 1-14** To level out uneven skin edges, take a deeper bite of the depressed side and shallower bite of the elevated side.

6. To close skin with uneven edges because of variable skin thickness or uneven subcutaneous closure, take a shallower bite of the elevated side and a deeper bite of the depressed side (fig. 1-14). This will actually provide bites of the same thickness that will level the skin when the first throw is tightened.

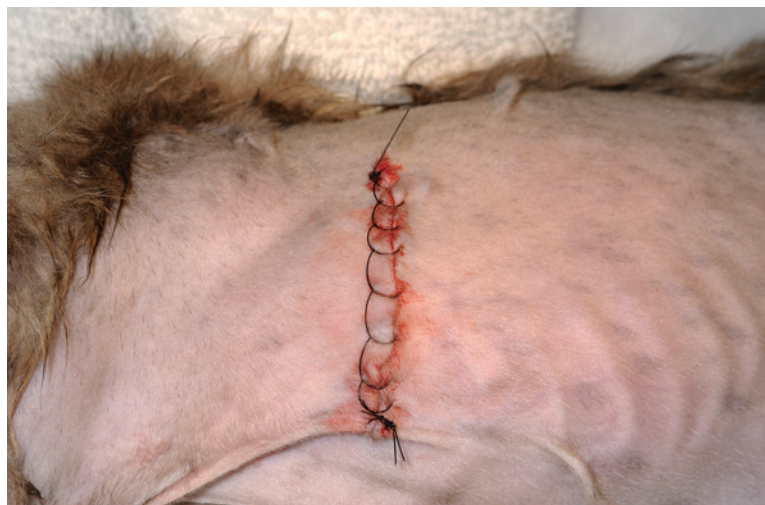***Surgical technique: Ford interlocking pattern for a right-handed surgeon***

1. Starting at one end of the incision, take a bite across the incision line. For a right handed surgeon, the needle should pass from right to left and perpendicular to the incision line. Tie 2 knots.
2. Lay the suture on the left side of the incision so that it is lateral to the incision line and to where the needle will exit with each suture bite (fig. 1-15).



**Figure 1-15** Retract the suture laterally as you take skin bites, so the needle comes up within the loop of the suture. Take the last suture bite from the opposite direction (middle figure) or a skin bite lateral to the final suture (right figure) to make a narrow loop for tying off the pattern.

3. Take a suture bite from right to left across the incision line so that the needle exits the tissue within the loop of suture.
4. Tighten the suture so that it lies against the skin without compressing it (fig. 1-16).
5. Continue the pattern to the end of the incision line. Take bites 0.5 to 1 cm from the edge and 0.5 to 1 cm apart, depending on skin thickness.
6. At the end of the incision, tie the suture end to a loop.
  - a. Pass the needle from left to right on the last bite to make a narrow loop for tying (fig. 1-15).



**Figure 1-16** A Ford interlocking pattern should lie gently against the skin.

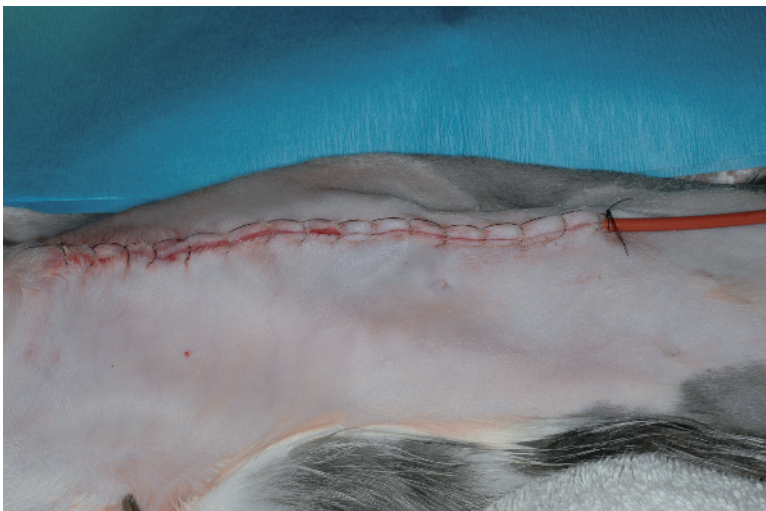
- b. Alternatively, take a bite of the skin lateral to the incision, starting near the suture exit site and ending 0.5 to 1 cm away to make a narrower loop for tying (fig. 1-15).

## Postoperative considerations

Nonabsorbable skin sutures are usually removed 10 to 14 days after placement. Sutures may be left in longer in patients that have conditions that could delay wound healing (e.g., mast cell tumor excision). An Elizabethan collar or protective bandage should be placed as needed to protect the site until it is healed.

Complications of incisional closure are often related to technique. During closure, subcutaneous tissues may appear ruffled or buckled if sutured with large appositional bites instead of a Lembert type of pattern. Skin sutures that are too tight (fig. 1-17) or too loose can result in ischemia or wound contamination, respectively. Skin edges may fail to appose with intradermal patterns for several reasons. If bites on opposite sides of the incision do not overlap slightly, gaps may occur. In this case, sutures crossing the incision line can be seen advancing at a forward angle, instead of perpendicular or slightly backward, before the suture is tightened. Gaps may also be present if the suture enters or exits through subcutis instead of remaining in the dermis for its entire path. Buckling of the skin during intradermal closure may be caused by too much overlapping of contralateral bites. Buckling can also occur if bites are not parallel to the skin surface (e.g., bites that enter and exit the dermis but, midway, pass through the subcutis). Skin can purse string if the intradermal suture is pulled too tightly when the ending knot is tied.

Failure to bury intradermal knots can occur for several reasons. Knots that are too close to the end of the incision can be trapped above a web of subcutis, since the subcutaneous incision is often shorter than the skin incision. To prevent knot prolapse out of the incision, the subcutaneous incision should be extended to the end of the dermal incision or the knot should be started farther from the incision end. Knots can accidentally be pulled out of the incision line if the suture is tightened perpendicular to the incision line or is lifted up when the knot is being tied. Crossover sutures can accidentally be included in or under



**Figure 1-17** This cat underwent diaphragmatic hernia repair; the red rubber chest tube was exited out through the diaphragmatic and abdominal closures. In this cat the Ford interlocking pattern is pulled too tightly, resulting in ridges in the skin.

the knot when the final sutures are being placed or the tucking maneuver is performed. During the tucking maneuver, passage of the needle through the superficial subcutis instead of through the incisional gap will prevent the knot from burying.

Corticosteroids, cytotoxic agents, and radiation will delay wound healing. The greatest effect is seen during the early stages of wound repair; however, later stages may also be affected. Specific recommendations cannot be made regarding postoperative use of these agents. Cytotoxic or radiation therapy is usually delayed for 7 to 14 days until the wound strength has increased and the incision appears to be healed.

## Bibliography

- Amalsadvala T and Swaim SF: Management of hard-to-heal wounds. *Vet Clin Small Anim Pract* 2006;36:693–711.
- Mison M.B. et al: Comparison of the effects of the CO<sub>2</sub> surgical laser and conventional surgical techniques on healing and wound tensile strength of skin flaps in the dog. *Vet Surg* 2003;32:153–160.
- Pavletic MM: Basic principles of wound healing. In *Atlas of Small Animal Wound Management & Reconstructive Surgery*. Ames Ia., Wiley-Blackwell, 2010: pp. 18–29.
- Rajbabu K. et al: To knot or not to knot? Sutureless haemostasis compared to the surgeon's knot. *Am R Coll Surg Engl* 2007;89:359–362.
- Rosine and Robinson GM: Knot security of suture materials. *Vet Surg* 1989; 18:269–273.
- Smeak DD: Buried continuous intradermal suture closure. *Compend Contin Educ Pract Vet* 1992;14:907–918.
- Sylvester A. et al: A comparison of 2 different suture patterns for skin closure of canine ovariohysterectomy. *Can Vet J* 2002;43:699–702.