

Qing Kay Li and Walid E. Khalbuss

## Contents

2.1 Image-Based Questions 1–50 (50 Images).....	124
2.2 Text-Based Questions 51–100.....	174
2.3 Answers and Discussion of Image-Based Questions 1–50.....	179
2.4 Answers and Discussion of Text-Based Questions 51–100.....	188
Reading List.....	197

---

Q.K. Li, MD, Ph.D. (✉)  
Department of Pathology, The Johns Hopkins University School  
of Medicine, The Johns Hopkins Bayview Medical Center,  
4940 Eastern Avenue, AA Building, Room 154B, Baltimore,  
MD 21224-2780, USA  
e-mail: [qli23@jhmi.edu](mailto:qli23@jhmi.edu)

W.E. Khalbuss, MD, PhD, FIAC.  
Department of Pathology, GE Clariant Diagnostic Services,  
31 Columbia, Aliso Viejo, California, 92656, USA  
e-mail: [walid.khalbuss@ge.com](mailto:walid.khalbuss@ge.com)

**Table 2.1** Benign components in serous fluid

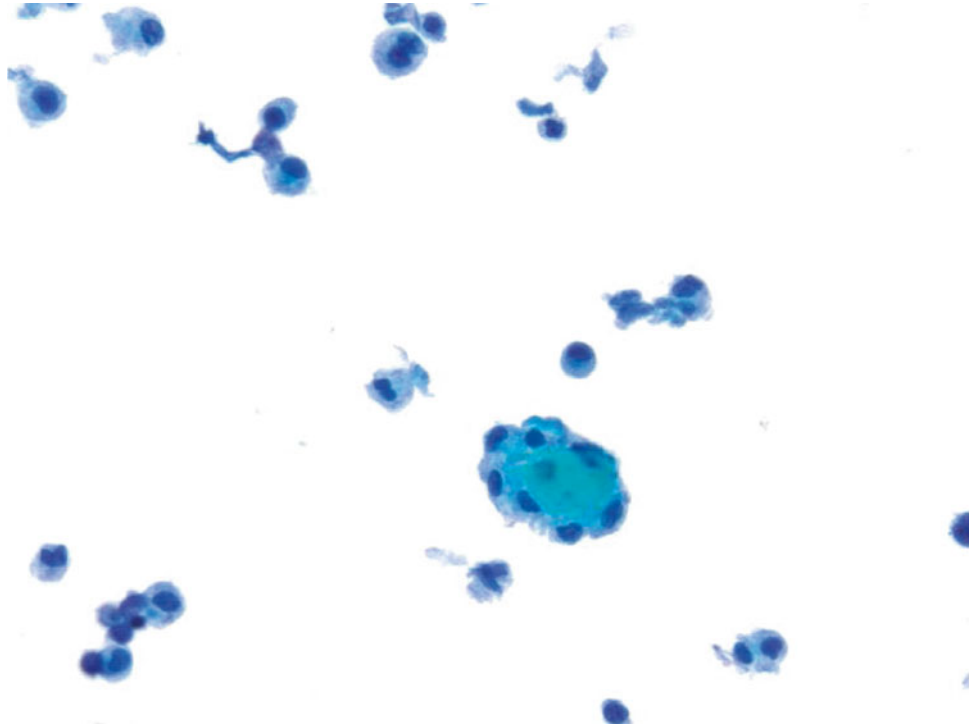
	Descriptions	Differentials
Mesothelial cells	Sheets and/or dispersed individual cells with round nuclei, small nucleoli, granular chromatin, dense cytoplasm and clear outer rim, and “windows” between cells	Organized cellular arrangements and/or dispersed individual cells. Nuclei may show mild atypia, but with smooth nuclear membrane; no hyperchromasia DD: well-differentiated adenocarcinoma
Reactive mesothelial cells	Small clusters of cells (less than 10–20 cells) or dispersed individual cells with enlarged nuclei, coarse chromatin, prominent nucleoli, dense cytoplasm and clear outer rim, and “windows” between cells	A spectrum of changes ranges from normal to markedly atypical cells. Binucleation and multinucleation are common DD: well-differentiated adenocarcinoma
Histiocytes	Loosely formed two-dimensional clusters or dispersed individual cells, with coffee bean-shaped nuclei, fine chromatin, inconspicuous nucleoli, and foamy cytoplasm	Cells have coffee bean-shaped nuclei, cytoplasmic vacuoles and normal N/C ratios DD: well-differentiated adenocarcinoma
Eosinophils	Granulocytes with brick-red cytoplasmic granules after staining with eosin (a red dye) using the Papanicolaou stain method	Cells with eosinophilic intracytoplasmic granules DD: neutrophils
Lupus erythematosus (LE) cells	Neutrophils or macrophages with intracytoplasmic hematoxylin bodies	Cells with eccentric nuclei and large homogeneous intracytoplasmic bodies (hematoxylin bodies) DD: signet ring cells
Hematoxylin body	Homogeneous and glassy intracytoplasmic body (denatured nuclear material), green or blue or purple in color with the Papanicolaou stain, and magenta in color with the Diff-Quik stain	Presence in the cytoplasm of neutrophil or macrophage (LE cells), commonly seen in lupus pleuritis
Psammoma body	Round collections of calcium which is covered with a thin layer of benign mesothelial cells. It stains purple in color with the Papanicolaou method	Calcium in the center of the spheres. It may be found in both benign and malignant conditions DD: collagen ball
Magenta body	Variably sized red-to-purple perinuclear inclusions seen by the Diff-Quik stains	Seen in metastatic breast carcinomas
Collagen ball	Spheres of collagen which is covered with a thin layer of benign mesothelial cells	Nonspecific finding DD: psammoma body. Metastatic mucinous adenocarcinomas, papillary serous carcinomas of the ovary, and mesotheliomas
Charcot–Leyden crystal	Needle-shaped orangeophilic color crystal, a by-product of eosinophil degranulation	Associated with allergy DD: calcium oxalate crystals

**Table 2.2** Malignant conditions in serous fluid

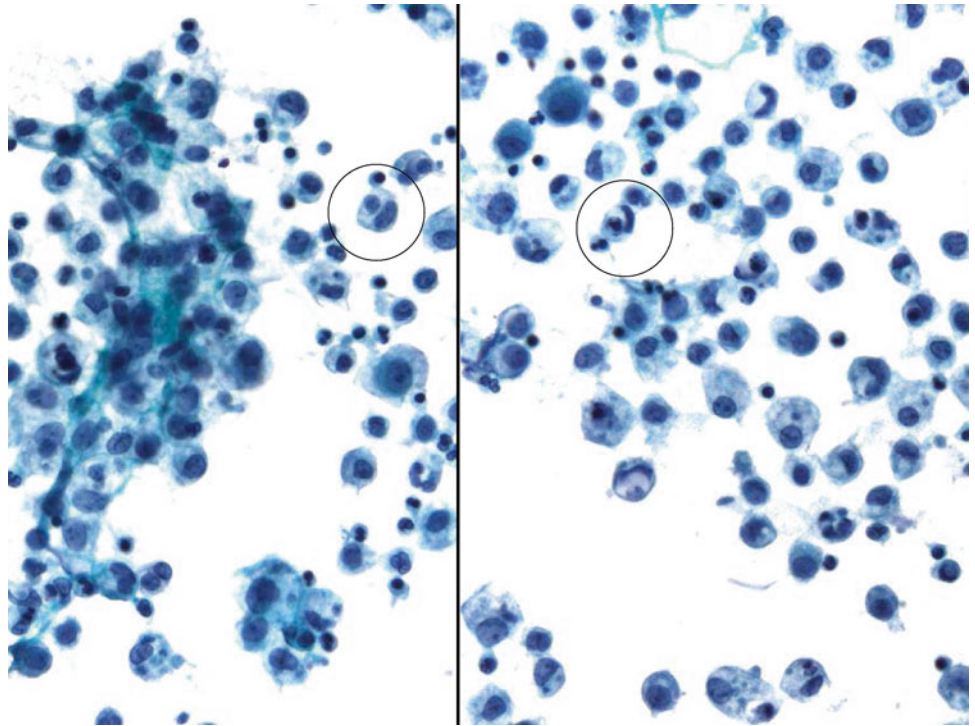
Conditions	Descriptions	Differentials
Mesothelioma	Numerous three-dimensional clusters (with more than 20–30 tumor cells). Tumor cells have large nuclei, coarse chromatin, and irregular nuclear membrane	Cellular clusters with scallop border and cytoplasmic vacuoles. Tumor cells may maintain low N/C ratios and “windows” between cells. Cytoplasm is dense with “hyaluronic acid mucin” DD: adenocarcinoma
Adenocarcinoma	Three-dimensional cell clusters with smooth border and/or acinar/papillae arrangements of columnar cells. Tumor cells have high N/C ratios, prominent nucleoli, and “lacy” cytoplasm with vacuolization	Columnar cells have high N/C ratios with irregular nuclear membrane, coarse chromatin, prominent nucleoli, and cytoplasmic vacuole (mucin production). No “window” between cells DD: mesothelioma, poorly differentiated nonkeratinizing squamous cell carcinoma
Squamous cell carcinoma	Discohesive and scattered individual polymorphic cells or loosely formed two-dimensional cell clusters with or without keratinization	Polygonal, rounded, elongated, or tadpole-shaped cells with large pyknotic nuclei, smudgy chromatin and dense cytoplasm. No “window” between cells DD: poorly differentiated adenocarcinoma
Small cell carcinoma	Tight clusters of small hyperchromatic cells (two to three times the size of mature lymphocytes) with nuclear molding and crowding, nuclear stripes (breakdown of nuclear material), inconspicuous nuclei, scant cytoplasm	Fine chromatin (salt-and-pepper appearance), mitoses, necrosis, and apoptotic bodies DD: lymphoma, basaloid squamous cell carcinoma, and poorly differentiated adenocarcinoma
Undifferentiated large cell carcinoma	Loosely cohesive clusters, syncytial sheets or scattered polymorphic large cells with high N/C ratios, single or multiple prominent nucleoli and feathery cytoplasm	Malignant cells are huge with large nucleoli. Numerous mitoses DD: poorly differentiated adenocarcinoma and sarcomas
Melanoma	Scattered individual large cells with prominent nucleoli and cytoplasmic melanin pigments. Binucleation with “mirror” arrangement. Pseudointranuclear inclusions	Discohesive malignant cells with prominent nucleoli DD: poorly differentiated carcinoma, Hodgkin lymphoma
Lymphoma (non-Hodgkin lymphoma)	Dispersed individual atypical lymphoid cells with clumped chromatin and irregular nuclear membrane. Increased mitotic activity. Lymphoglandular bodies in the background of the slide	The size of tumor cells ranges from small to large depending on the type of lymphoma. Monomorphous population of lymphocytes is a characteristic of SLL/CLL DD: reactive lymphocytes, small cell carcinoma, poorly differentiated carcinoma
Non-epithelial cell neoplasma	Individual or clusters of spindle cells, small round cells or pleomorphic tumor cells	DD: muscle, nerve tumors, small round cell tumor, and sarcomas

## 2.1 Image-Based Questions 1–50 (50 Images)

Fig. 2.1

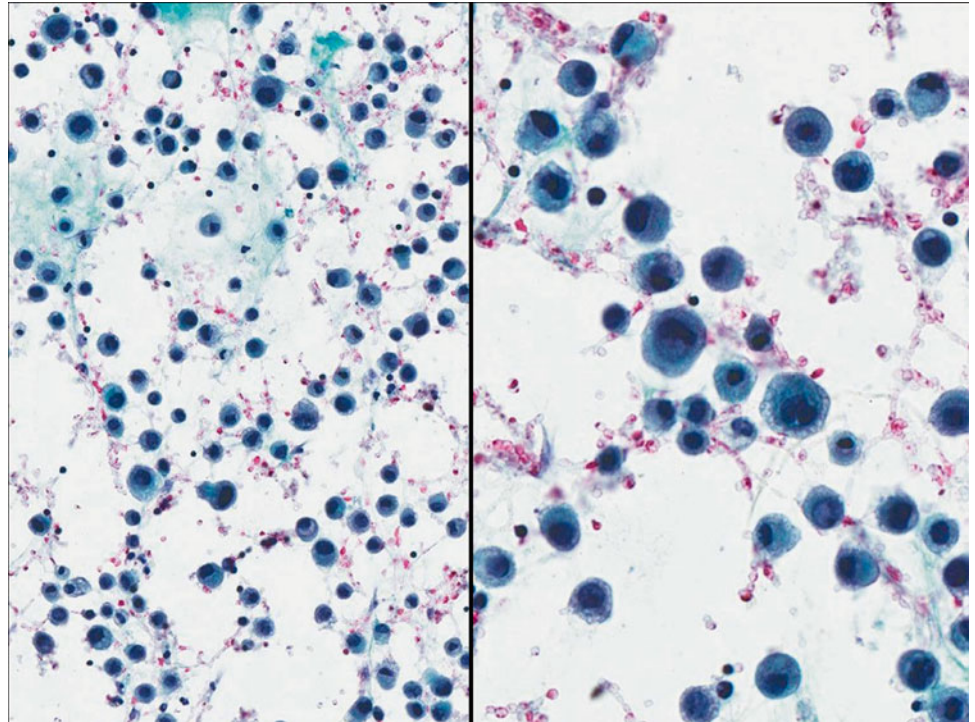


- Q-1. What is the diagnosis of this peritoneal washing specimen?
- (a) Metastatic adenocarcinoma
  - (b) Serous carcinoma of ovary
  - (c) Collagen ball
  - (d) Mesothelioma

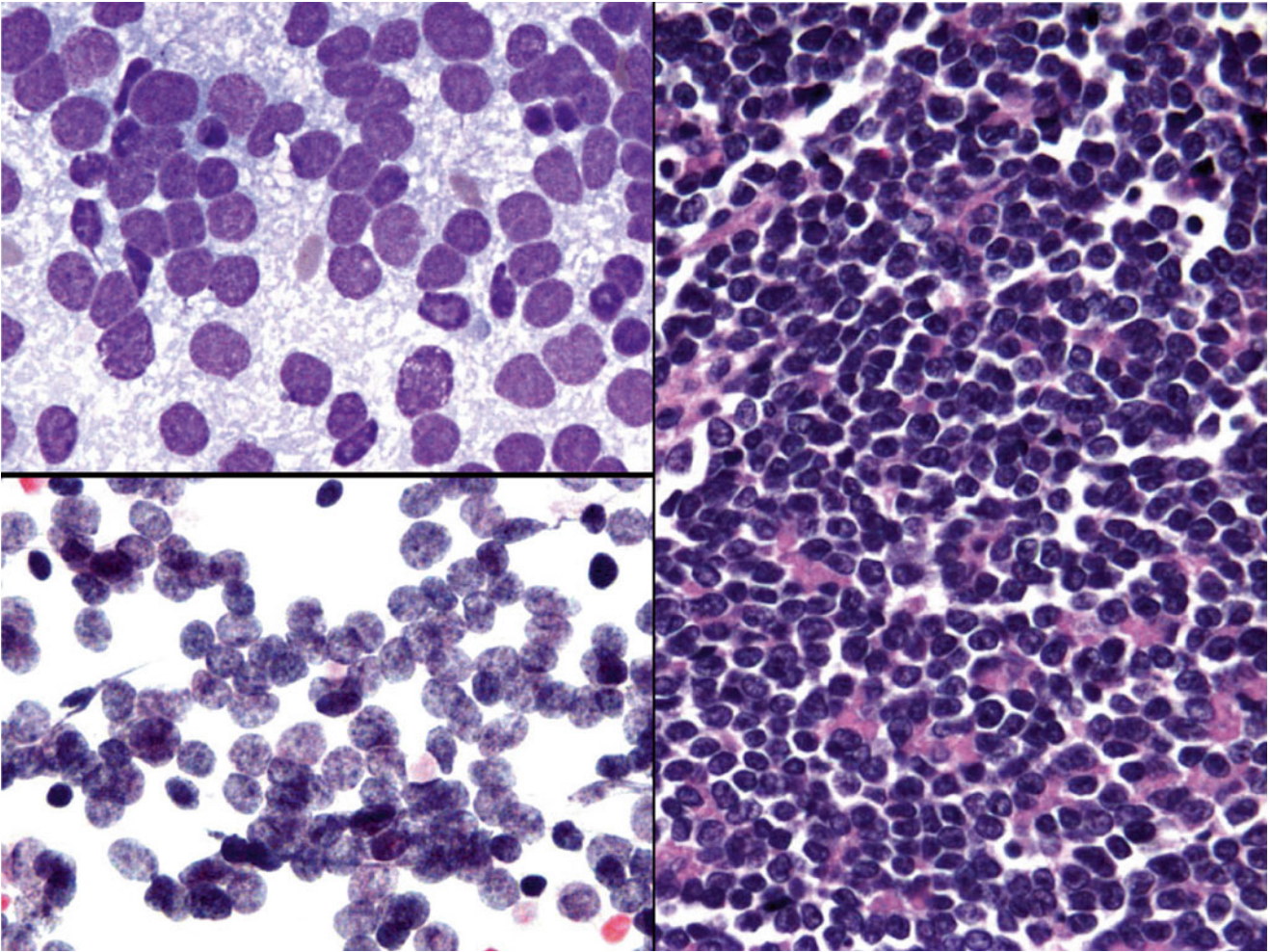
**Fig. 2.2**

Q-2. What is the diagnosis of cells seen in the pleural effusion from a patient with systemic lupus erythematosus?

- (a) Lupus erythematosus (LE) cells
- (b) Tart cells
- (c) Reactive mesothelial cells
- (d) Mucin-producing cells

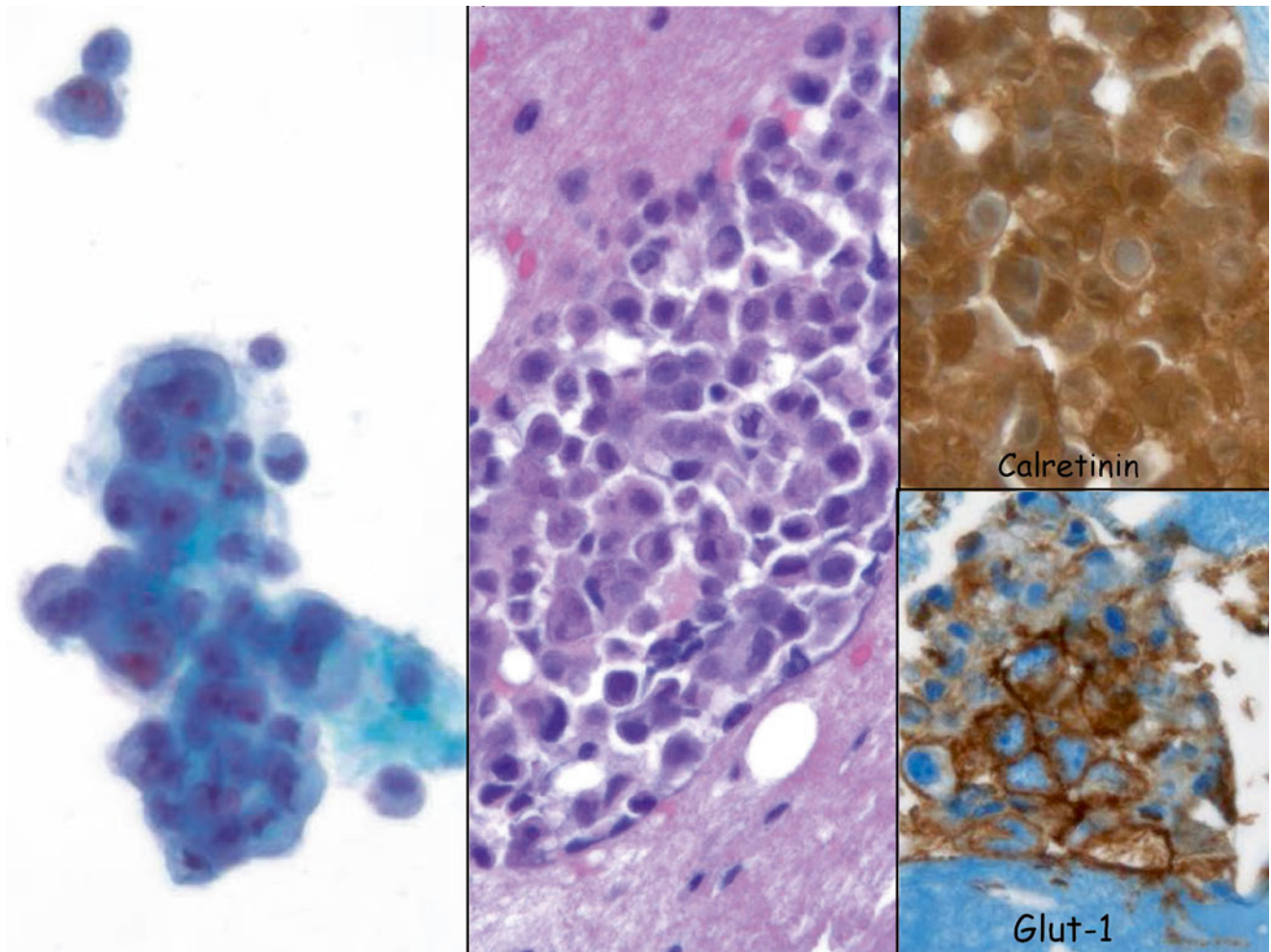
**Fig. 2.3**

- Q-3. What is the diagnosis of cells seen in this pericardial effusion from a 52-year-old female patient with a history of breast carcinoma and melanoma?
- (a) Metastatic lung adenocarcinoma
  - (b) Reactive mesothelial cells
  - (c) Metastatic melanoma
  - (d) Metastatic breast lobular carcinoma



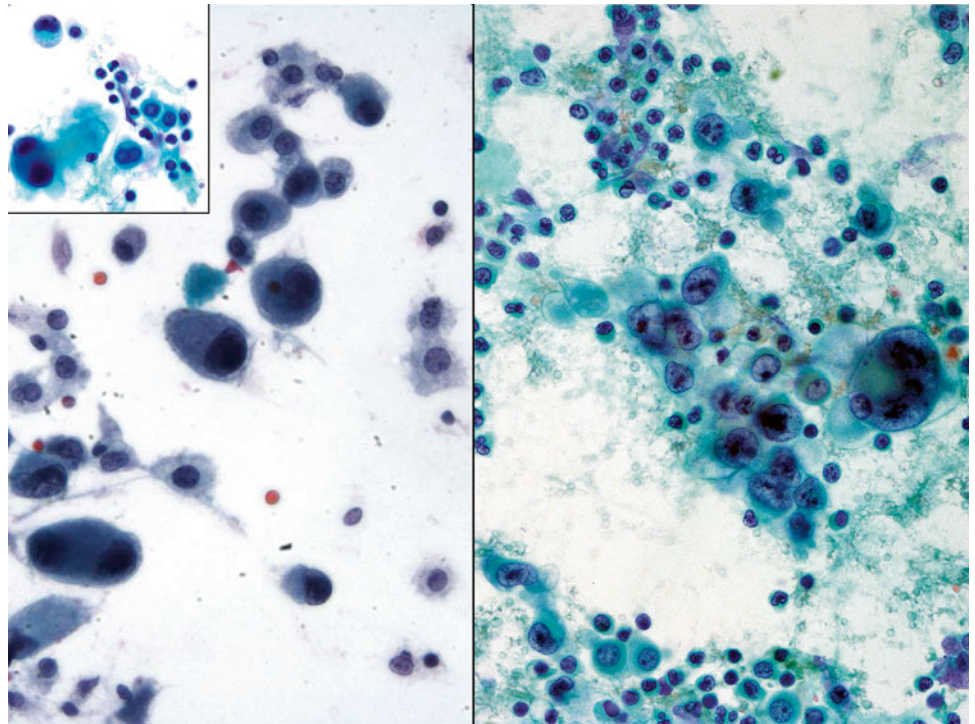
**Fig. 2.4**

- Q-4. What is the diagnosis of cells seen in this ascites from a 24-year-old male with a retroperitoneal mass?
- (a) Small cell carcinoma
  - (b) Lymphoma
  - (c) Ewing's sarcoma
  - (d) Metastatic adenocarcinoma

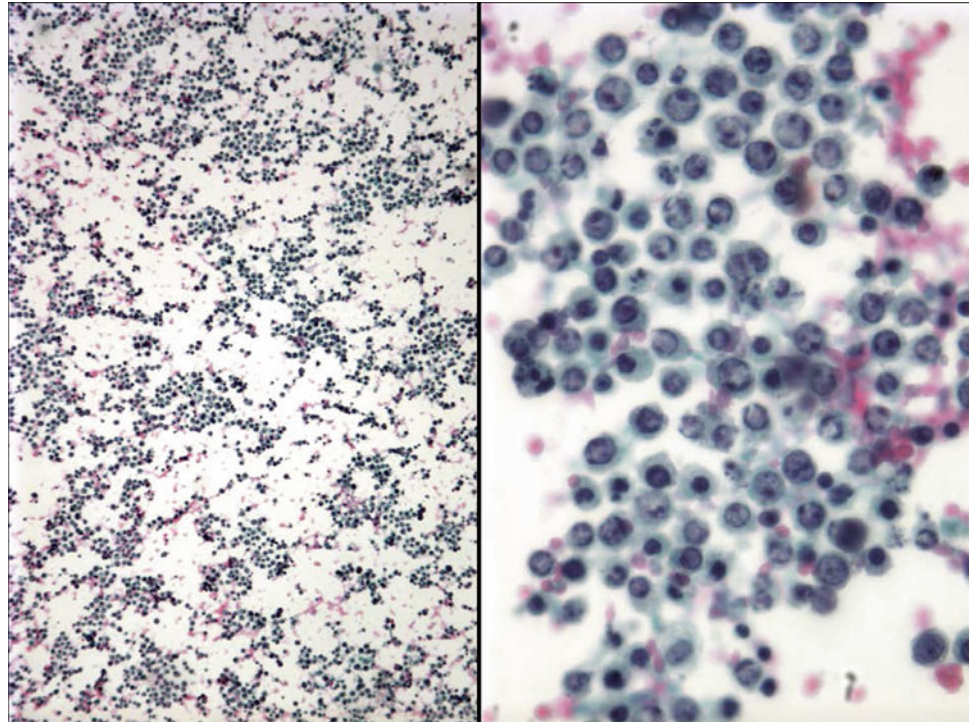


**Fig. 2.5**

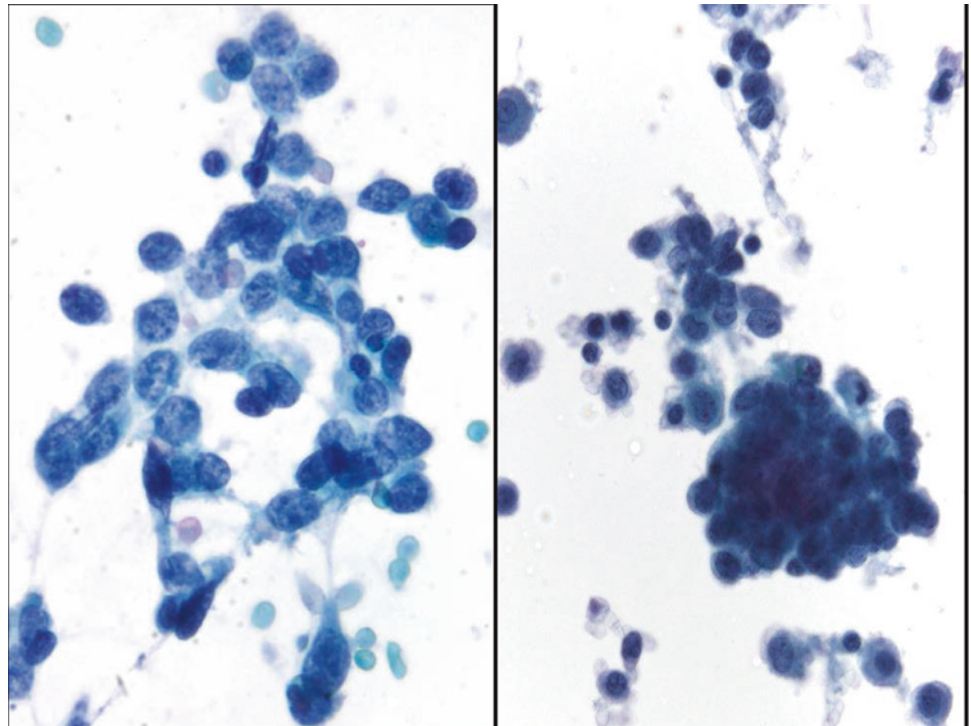
- Q-5. What is the diagnosis of cells seen in this pleural effusion from a 78-year-old female patient with pleural thickening?
- (a) Metastatic lung adenocarcinoma
  - (b) Reactive mesothelial cells
  - (c) Metastatic melanoma
  - (d) Mesothelioma

**Fig. 2.6**

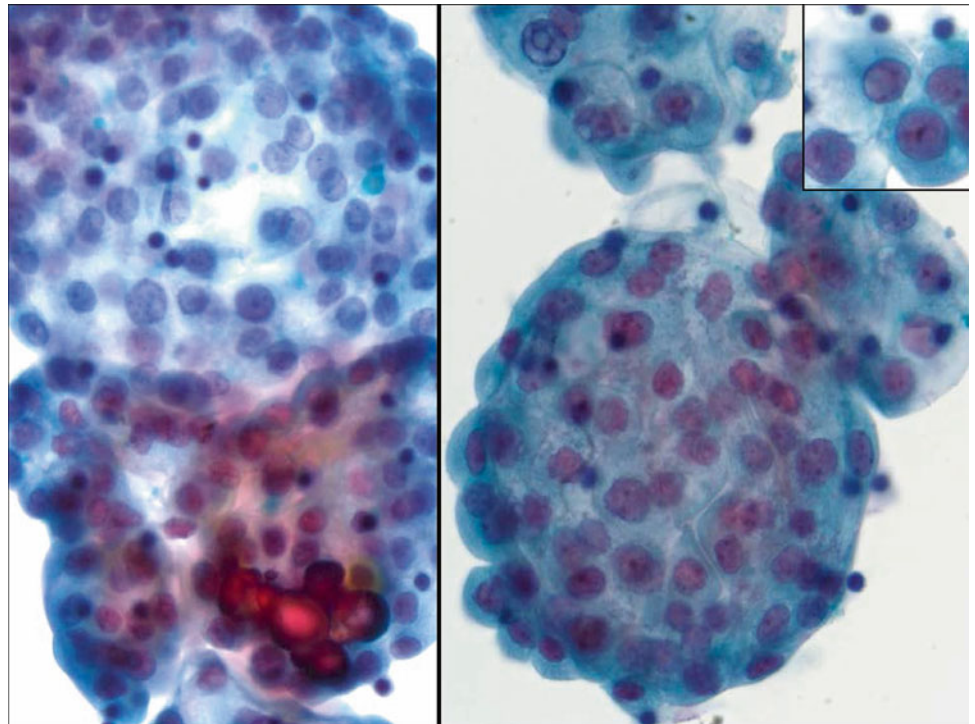
- Q-6. What is the diagnosis of cells seen in this ascites from an 8-year-old boy with a retroperitoneal mass?
- (a) Metastatic adenocarcinoma
  - (b) Reactive mesothelial cells
  - (c) Metastatic melanoma
  - (d) Metastatic rhabdomyosarcoma

**Fig. 2.7**

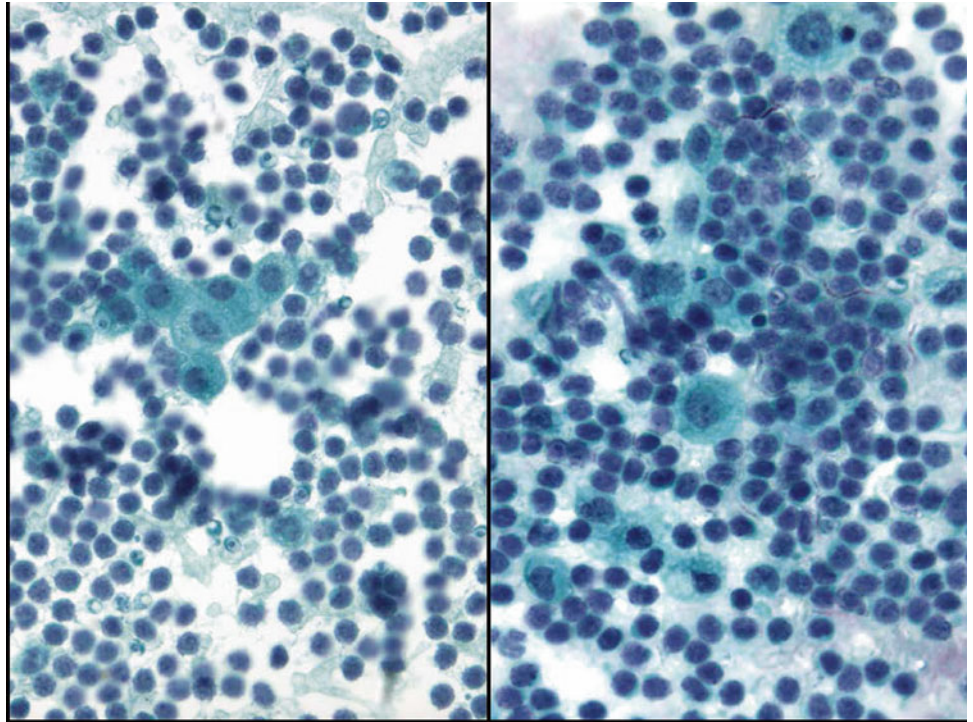
- Q-7. An 83-year-old male patient with lymphadenopathy developed pleural effusions. The specimen consists predominately of a monomorphous population of lymphocytes with apoptosis. Which one the following diagnoses is correct?
- (a) Metastatic poorly differentiated adenocarcinoma
  - (b) Small cell carcinoma
  - (c) Metastatic melanoma
  - (d) Lymphomatous effusion most consistent with malignant lymphoma

**Fig. 2.8**

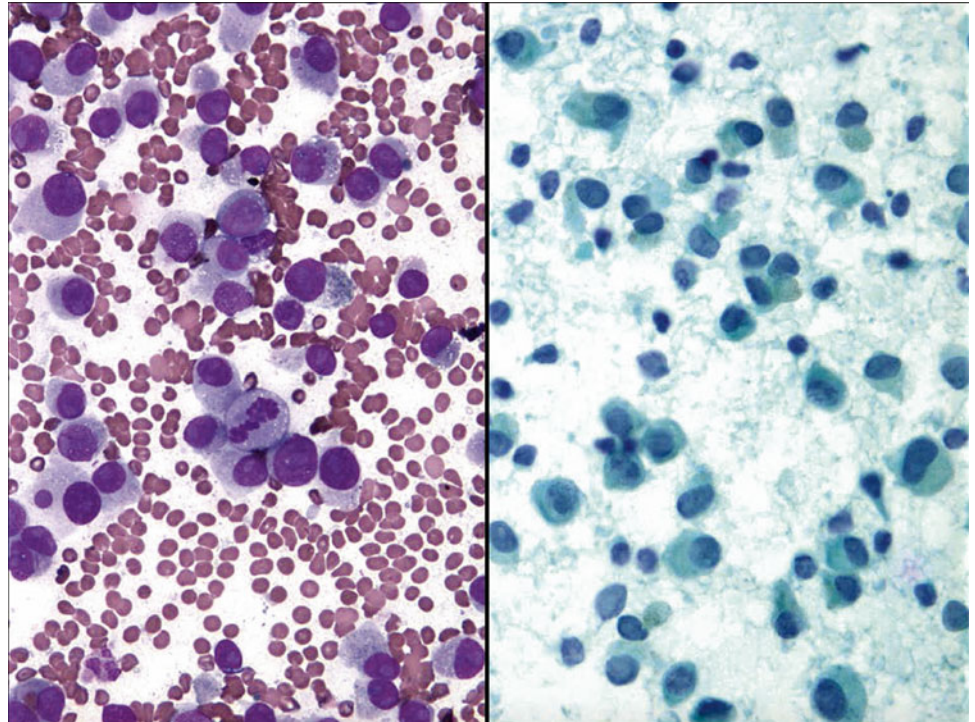
- Q-8. A 77-year-old male smoker with a right upper lung mass developed a pleural effusion. Which one of the following diagnoses is correct?
- (a) Metastatic poorly differentiated adenocarcinoma
  - (b) Metastatic small cell lung carcinoma
  - (c) Metastatic melanoma
  - (d) Lymphoma

**Fig. 2.9**

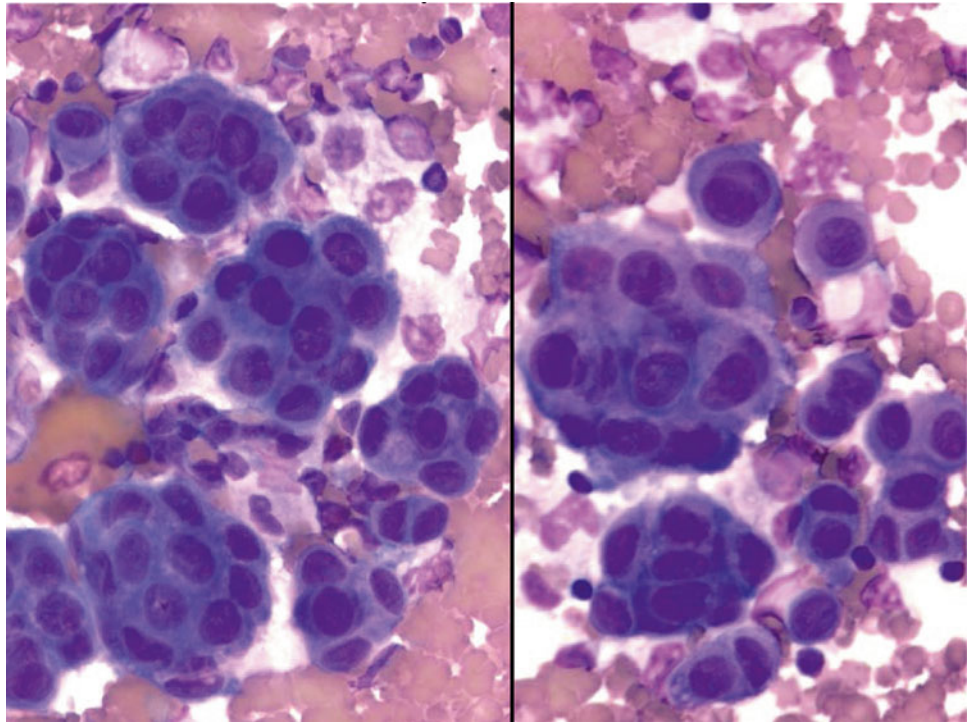
- Q-9. In this ascites from a 58-year-old female, the cytological findings are shown in this photo. What is the correct diagnosis?
- (a) Metastatic ovarian serous carcinoma
  - (b) Mesothelial cell hyperplasia
  - (c) Endosalpingiosis
  - (d) Metastatic adenocarcinoma

**Fig. 2.10**

- Q-10. A 64-year-old female smoker with a lung mass developed a pleural effusion. On cytospin preparation, the smear consists of predominantly small- to intermediate-sized lymphocytic cells with evenly distributed chromatin. Which one of the following diagnoses is correct?
- (a) Metastatic poorly differentiated adenocarcinoma
  - (b) Metastatic small cell lung carcinoma
  - (c) Lymphoma
  - (d) Lymphocytosis (lymphocytic effusion)

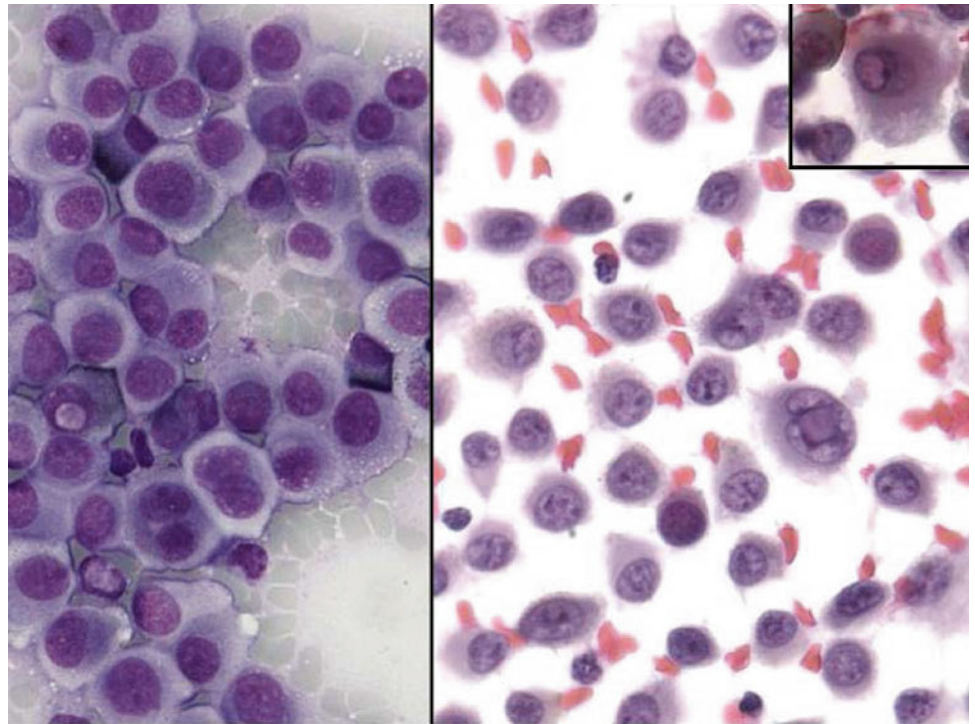
**Fig. 2.11**

- Q-11. A 34-year-old female with a history of melanoma now develops a lung mass and pleural effusion. Which one the following diagnoses is correct?
- (a) Metastatic poorly differentiated adenocarcinoma of the lung
  - (b) Metastatic small cell lung carcinoma
  - (c) Metastatic melanoma
  - (d) Lymphoma

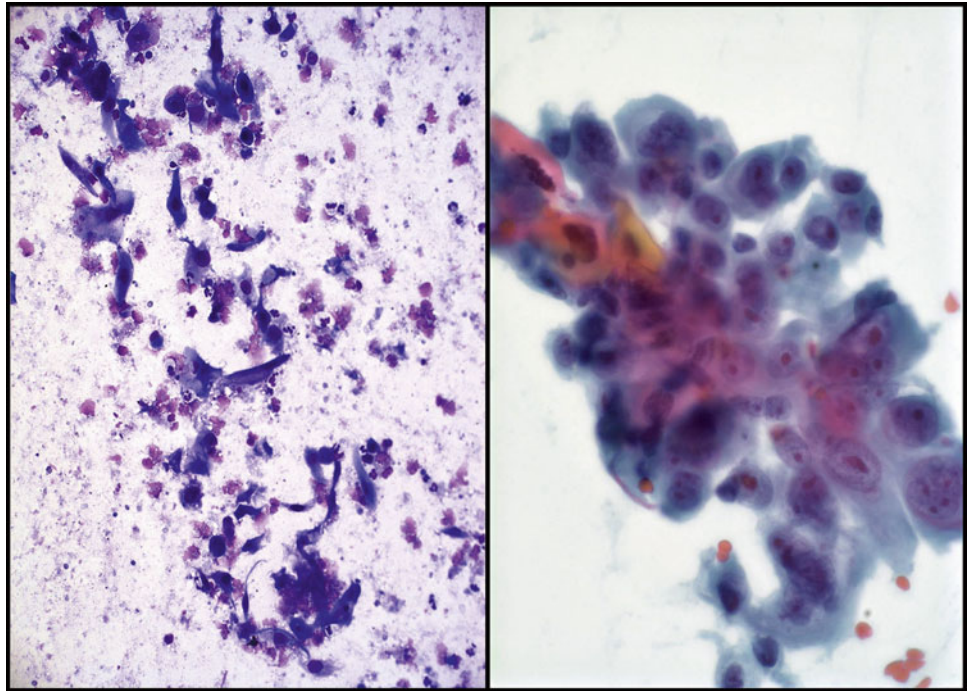
**Fig. 2.12**

Q-12. What is the diagnosis of cells seen in this pleural effusion?

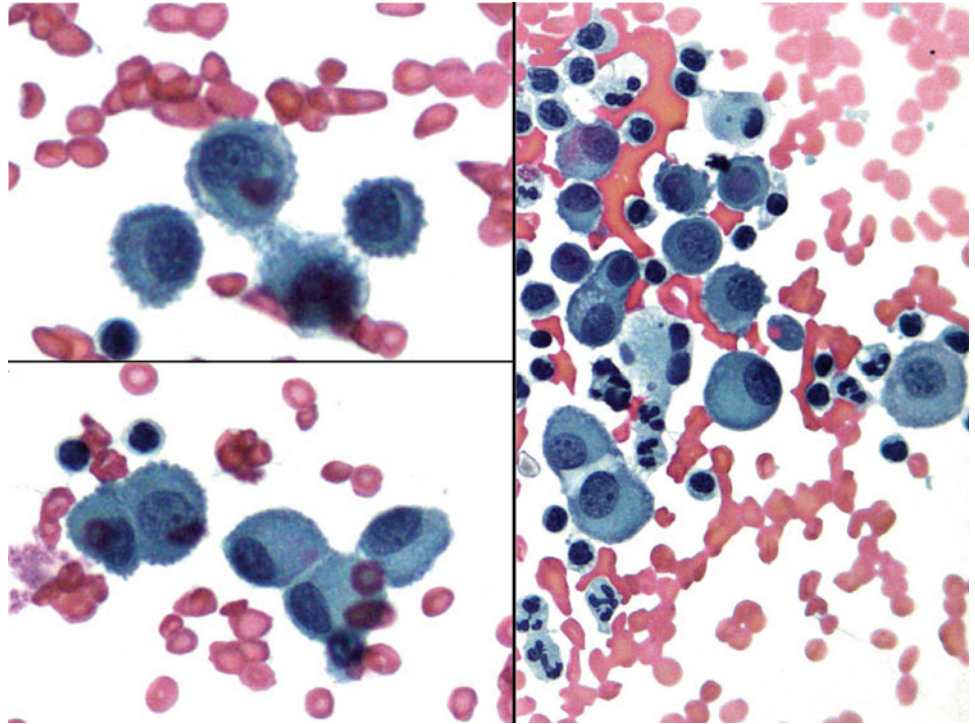
- (a) Metastatic lung adenocarcinoma
- (b) Reactive mesothelial cells
- (c) Metastatic melanoma
- (d) Mesothelioma

**Fig. 2.13**

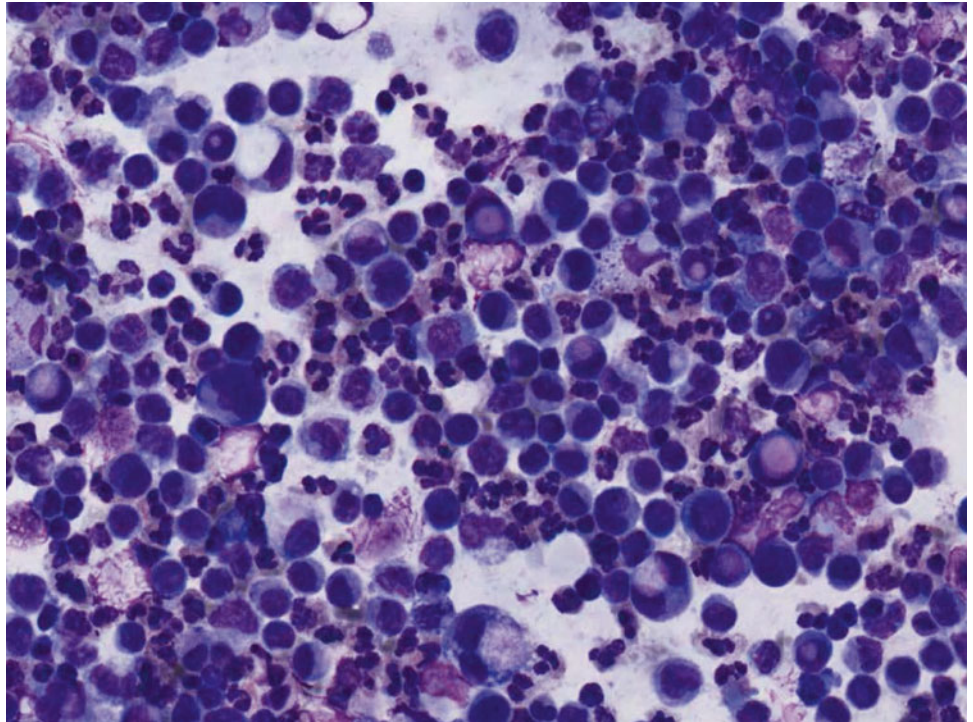
- Q-13. A 48-year-old female with a history of melanoma now develops a pleural effusion. Which one of the following diagnoses is correct?
- (a) Metastatic renal cell carcinoma
  - (b) Metastatic small cell lung carcinoma
  - (c) Metastatic melanoma
  - (d) Lymphoma

**Fig. 2.14**

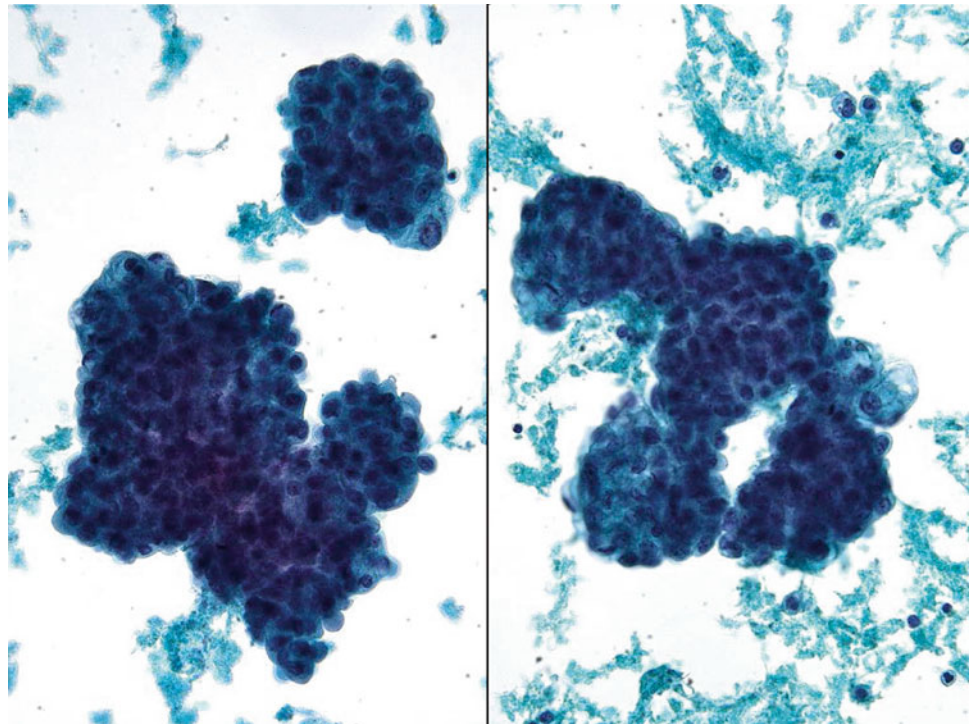
- Q-14. A 68-year-old male with a head and neck mass now develops a pleural effusion. Which one of the following diagnoses is correct?
- (a) Metastatic squamous cell carcinoma
  - (b) Metastatic poorly differentiated adenocarcinoma
  - (c) Metastatic melanoma
  - (d) Lymphoma

**Fig. 2.15**

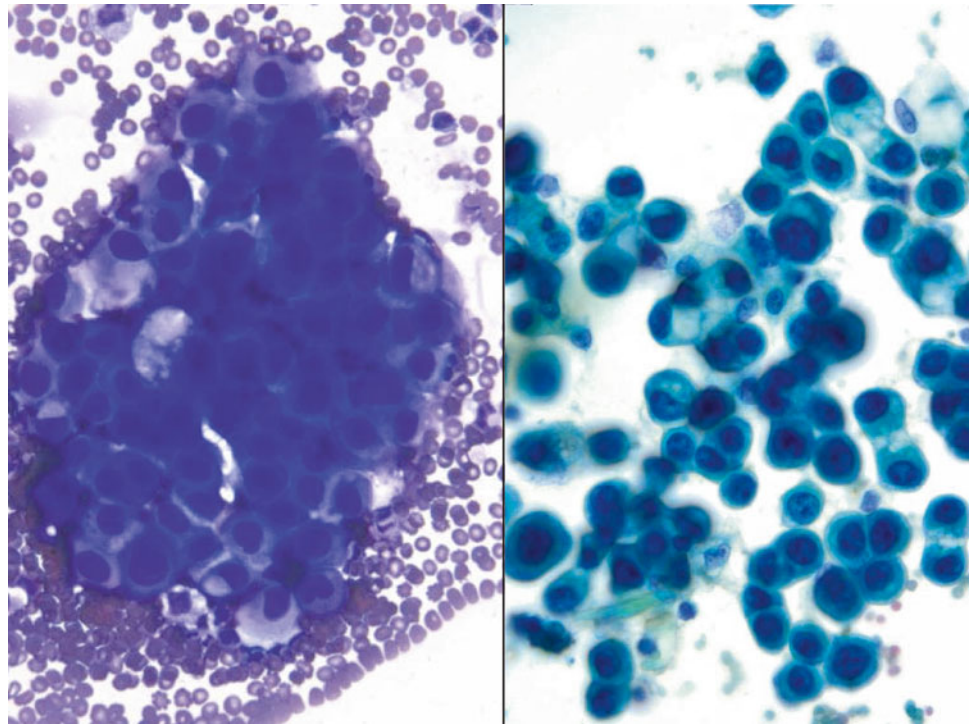
- Q-15. A 48-year-old female with a history of melanoma now develops a lung mass and pleural effusion. What is the diagnosis of cells seen in this pleural effusion?
- (a) Metastatic lung adenocarcinoma
  - (b) Reactive mesothelial cells
  - (c) Metastatic melanoma
  - (d) Mesothelioma

**Fig. 2.16**

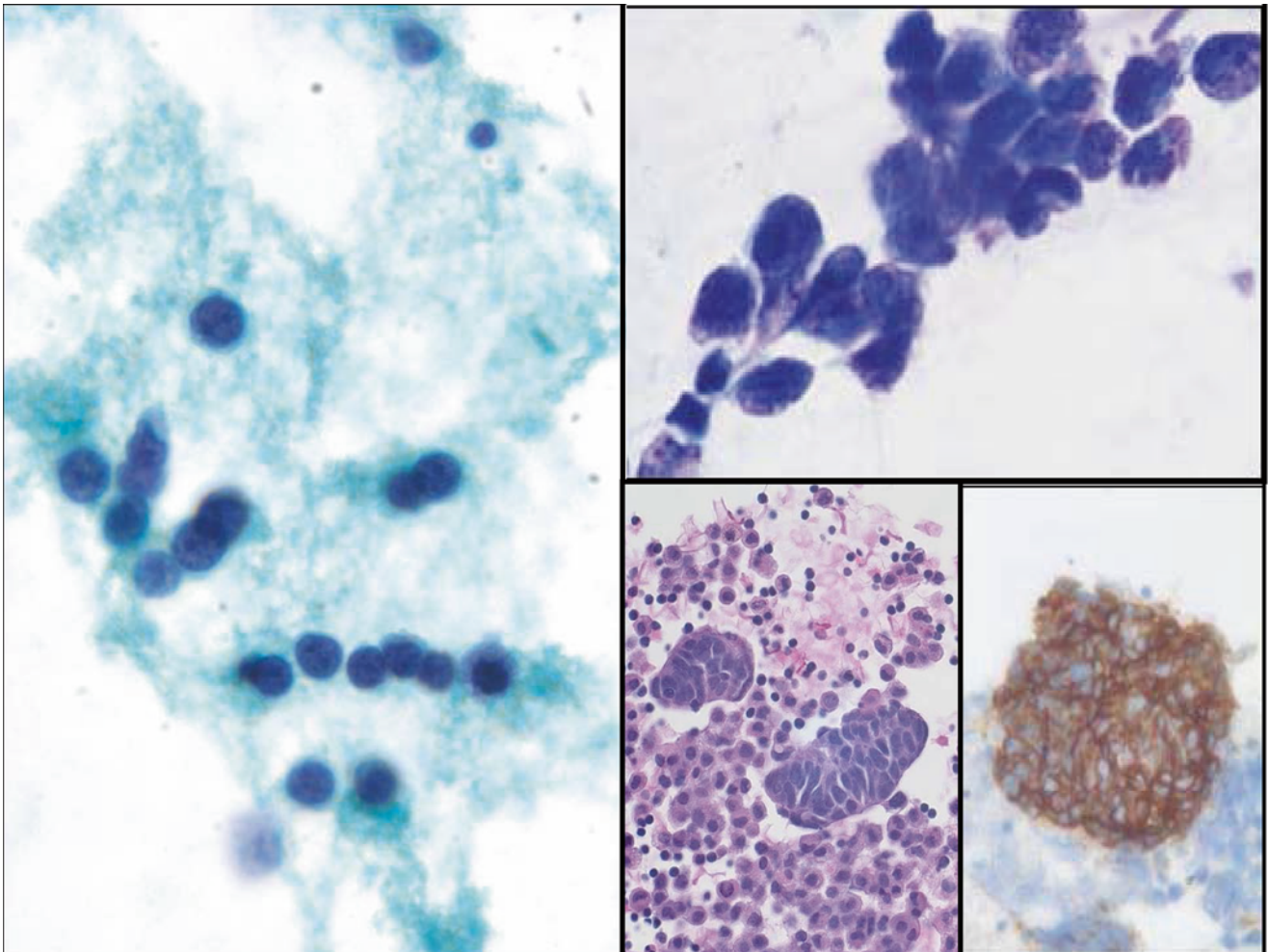
- Q-16. A 62-year-old female with a history of “carcinoma” now develops a pleural effusion. What is the diagnosis of cells seen in this pleural effusion?
- (a) Metastatic renal cell carcinoma
  - (b) Reactive mesothelial cells
  - (c) Metastatic melanoma
  - (d) Metastatic signet ring cell carcinoma

**Fig. 2.17**

- Q-17. A 70-year-old female with a history of right “kidney tumor” develops a right-side pleural effusion. What is the diagnosis of cells seen in this pleural effusion?
- (a) Metastatic papillary renal cell carcinoma
  - (b) Reactive mesothelial cells
  - (c) Mesothelioma
  - (d) Metastatic poorly differentiated adenocarcinoma of the lung

**Fig. 2.18**

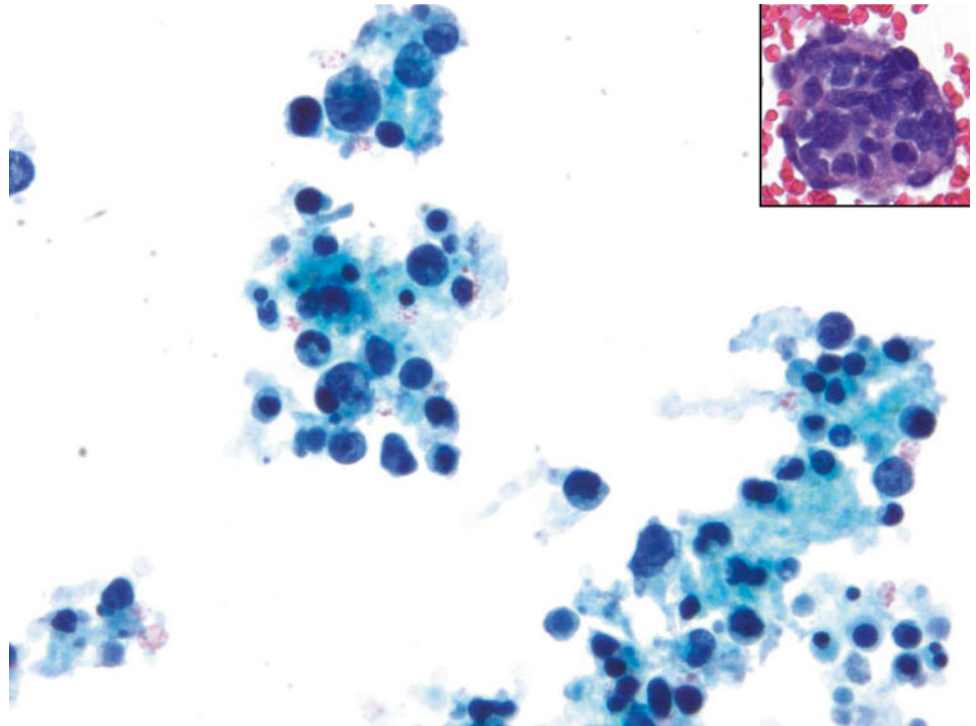
- Q-18. A 61-year-old male with a clinical presentation of a lung mass develops a left pleural effusion. What is the diagnosis of cells seen in this pleural effusion?
- (a) Metastatic adenocarcinoma of the lung
  - (b) Reactive mesothelial cells
  - (c) Mesothelioma
  - (d) Metastatic poorly differentiated small cell carcinoma



**Fig. 2.19**

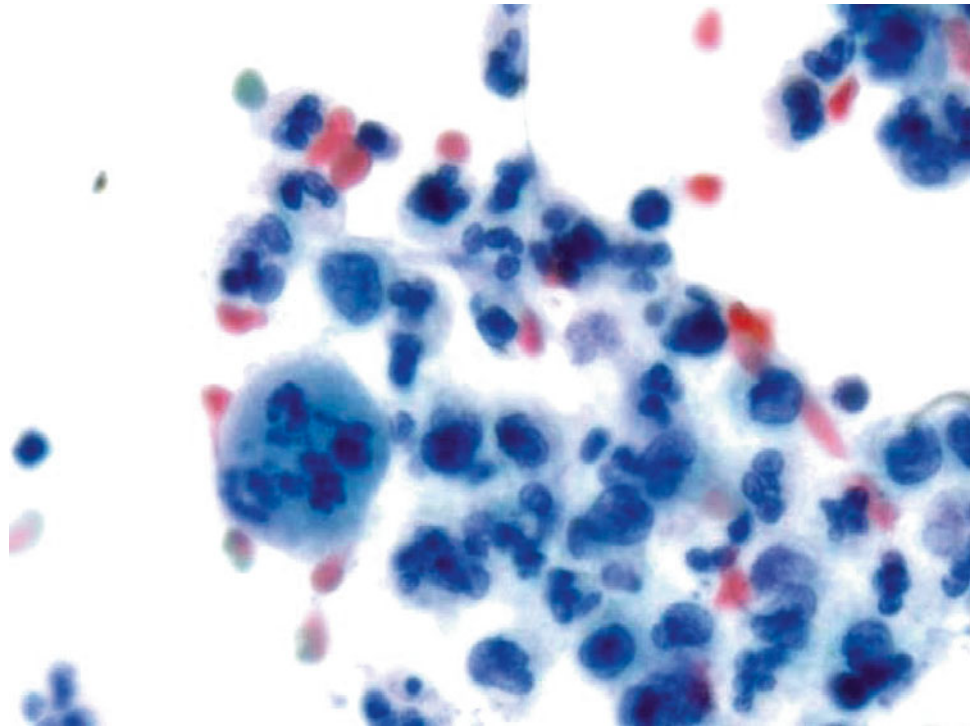
Q-19. Which one of the following immunomarkers has a better sensitivity for this metastatic carcinoma of the lung?

- (a) TTF1 (thyroid transcription factor 1)
- (b) Synaptophysin
- (c) Chromogranin A
- (d) CD56

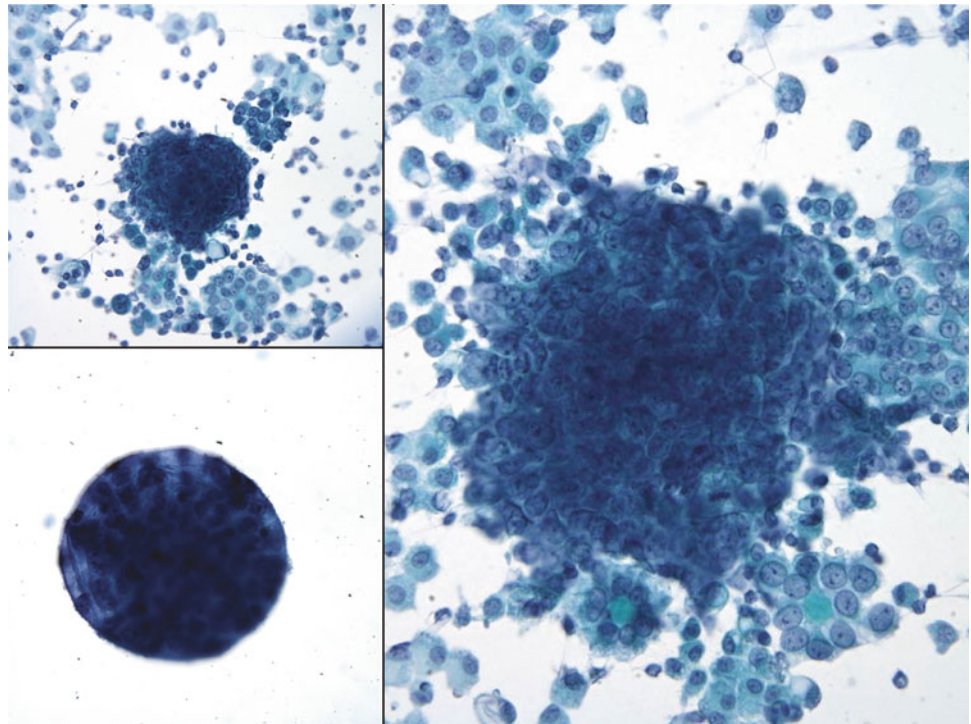
**Fig. 2.20**

Q-20. A 2-year-old female with an abdominal mass developed ascites. On surgical resection specimen, Homer-Wright rosettes are identified. The ascites cytospin was shown here. Which panel of following immunomarkers can help you confirm the diagnosis?

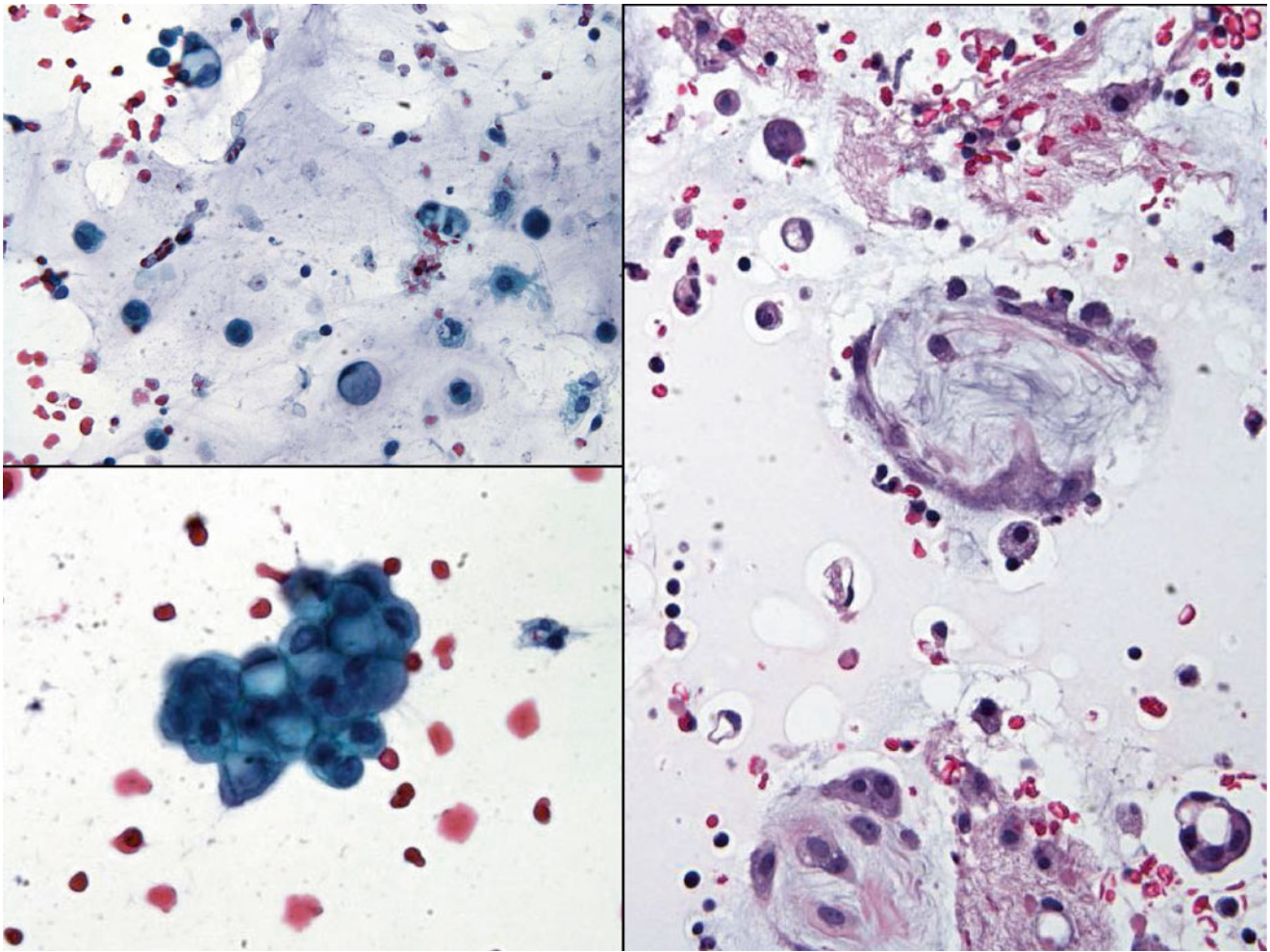
- (a) Cytokeratin and TTF1
- (b) Neuron-specific enolase (NSE), synaptophysin, S100, and glial fibrillary acidic protein (GFAP)
- (c) Chromogranin A, synaptophysin, and CD56
- (d) CD20, CD3, and CD56

**Fig. 2.21**

- Q-21. A 70-year-old male with a liver mass and lung masses develops a left pleural effusion. What is the diagnosis of cells seen in this pleural effusion?
- (a) Metastatic poorly differentiated adenocarcinoma of the lung
  - (b) Reactive mesothelial cells
  - (c) Metastatic hepatocellular carcinoma
  - (d) Metastatic poorly differentiated squamous cell carcinoma

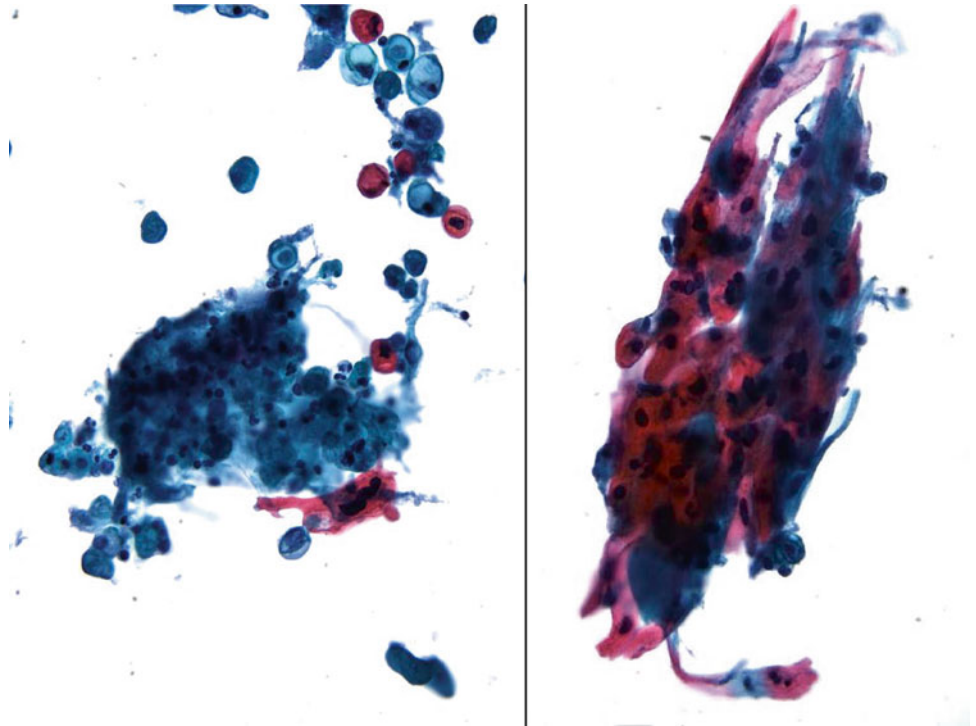
**Fig. 2.22**

- Q-22. A 72-year-old female with a history of colon cancer now develops a lung mass and pleural effusion. What is the diagnosis of cells seen in this pleural effusion?
- (a) Metastatic carcinoma of the breast
  - (b) Reactive mesothelial cells
  - (c) Metastatic colonic adenocarcinoma
  - (d) Mesothelioma



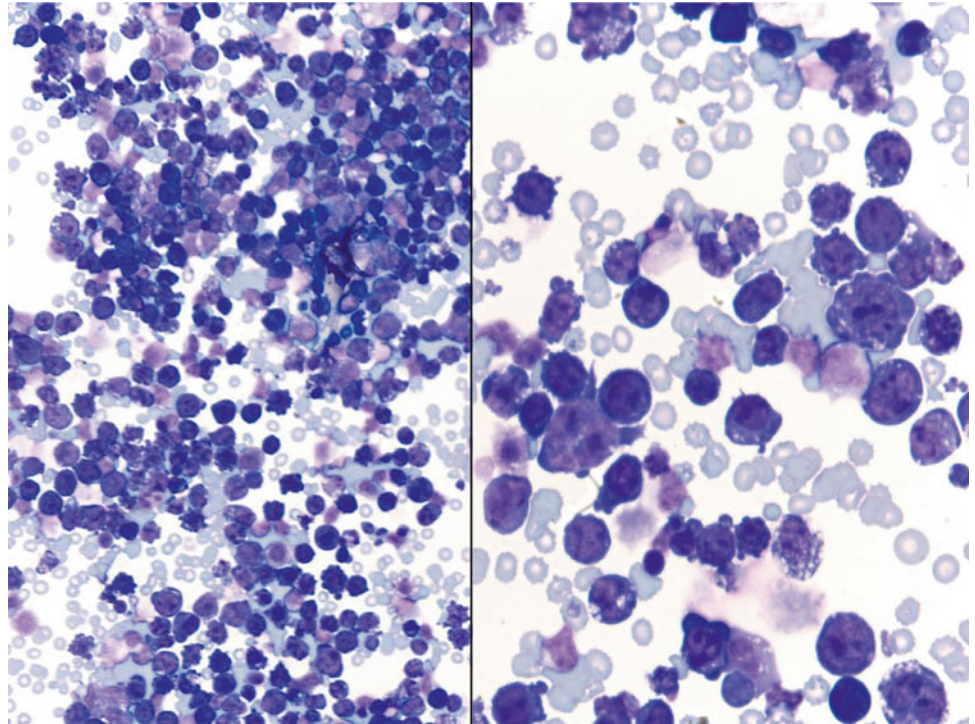
**Fig. 2.23**

- Q-23. A 69-year-old male smoker presents with a right lung mass and pleural effusion. What is the diagnosis of cells seen in this pleural effusion?
- (a) Metastatic papillary adenocarcinoma of the lung
  - (b) Reactive mesothelial cells
  - (c) Metastatic colonic adenocarcinoma
  - (d) Metastatic mucinous adenocarcinoma of the lung

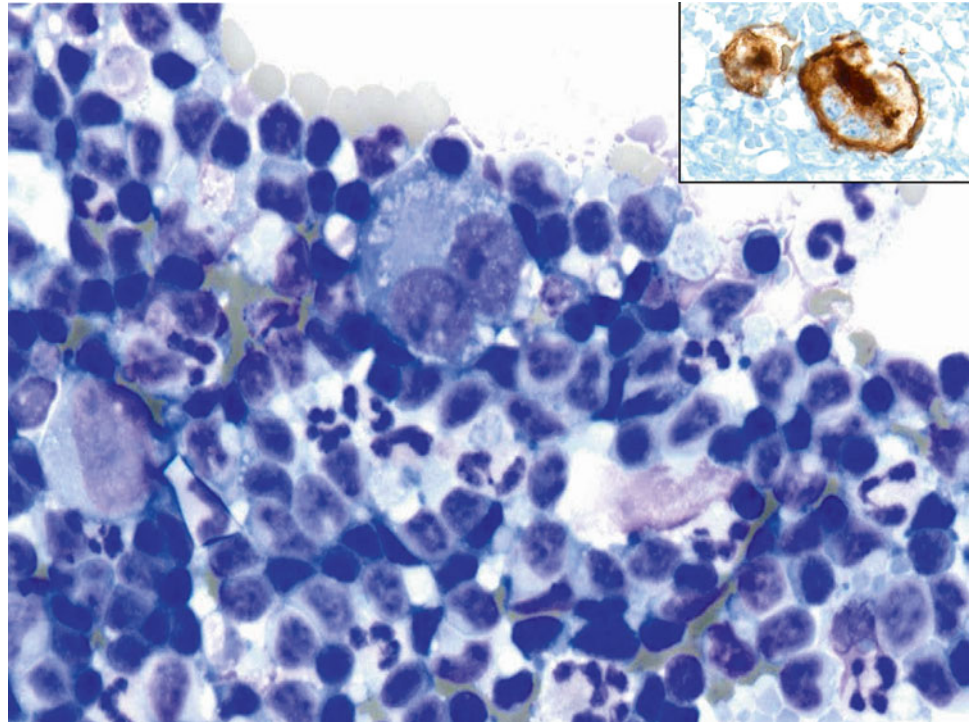
**Fig. 2.24**

Q-24. What is the diagnosis of cells seen in this pleural effusion?

- (a) Metastatic adenocarcinoma
- (b) Reactive mesothelial cells
- (c) Mesothelioma
- (d) Metastatic squamous cell carcinoma

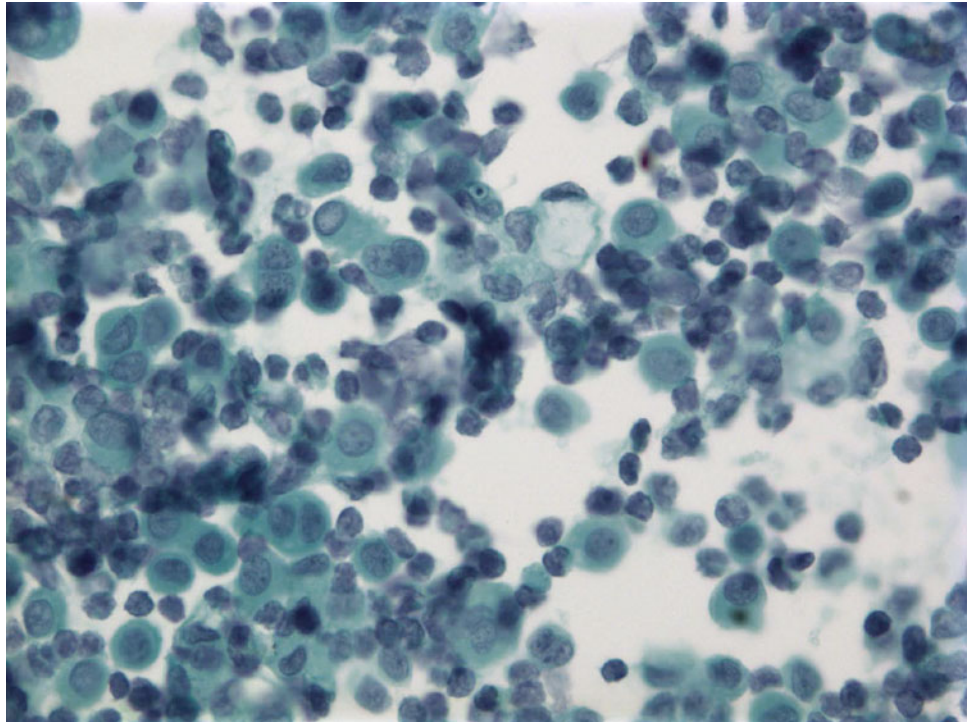
**Fig. 2.25**

- Q-25. An HIV-positive patient develops bilateral pleural effusions. What is the diagnosis of cells seen in this pleural effusion?
- (a) Metastatic adenocarcinoma
  - (b) Primary effusion lymphoma
  - (c) Reactive mesothelial cells
  - (d) Metastatic squamous cell carcinoma

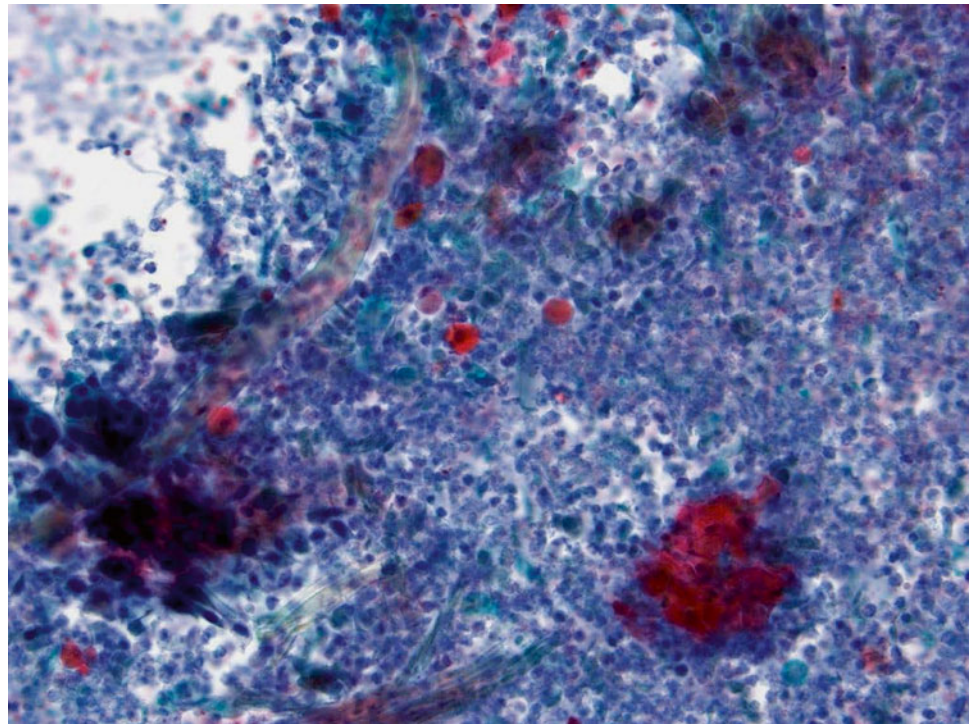
**Fig. 2.26**

Q-26. A 79-year-old patient with neck lymphadenopathy and mediastinal mass develops bilateral pleural effusions. What is the diagnosis of cells seen in this pleural effusion?

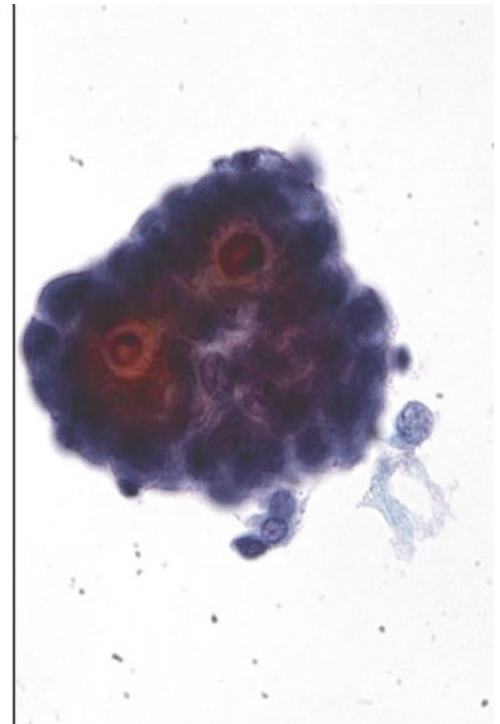
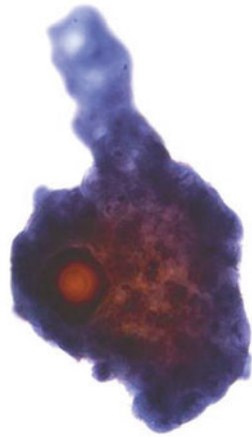
- (a) Metastatic adenocarcinoma
- (b) SLL/CLL
- (c) Reactive mesothelial cells
- (d) Hodgkin lymphoma

**Fig. 2.27**

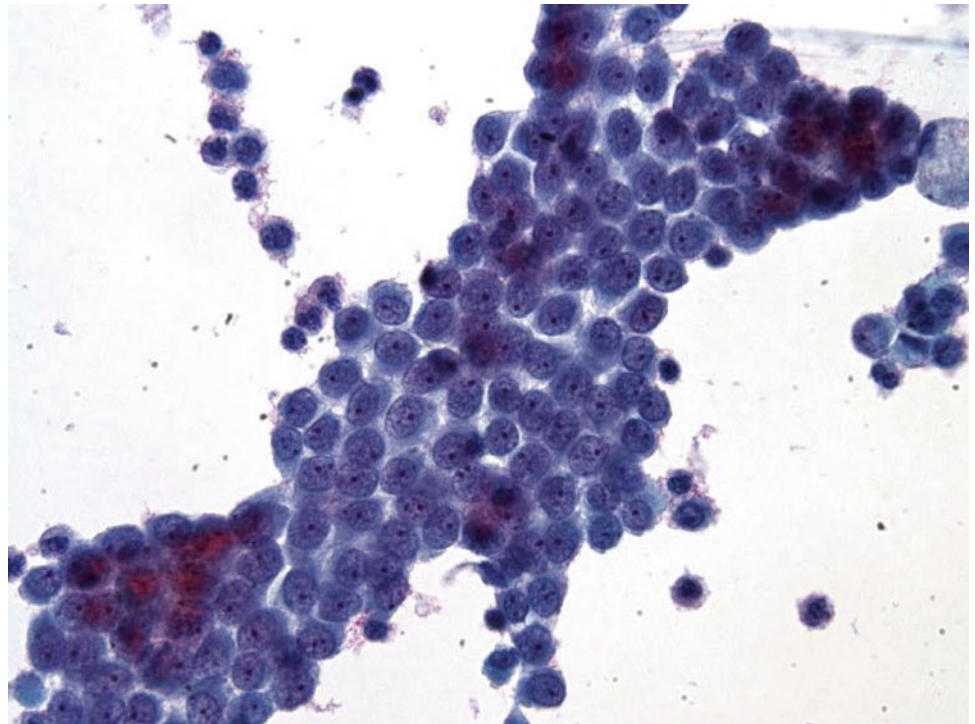
- Q-27. A 47-year-old male with history of hepatitis C and numerous liver nodules develops pleural effusion and ascites. What is the diagnosis of cells seen in this pleural effusion?
- (a) Metastatic signet ring cell carcinoma
  - (b) SLL/CLL
  - (c) Reactive mesothelial cells
  - (d) Hodgkin lymphoma

**Fig. 2.28**

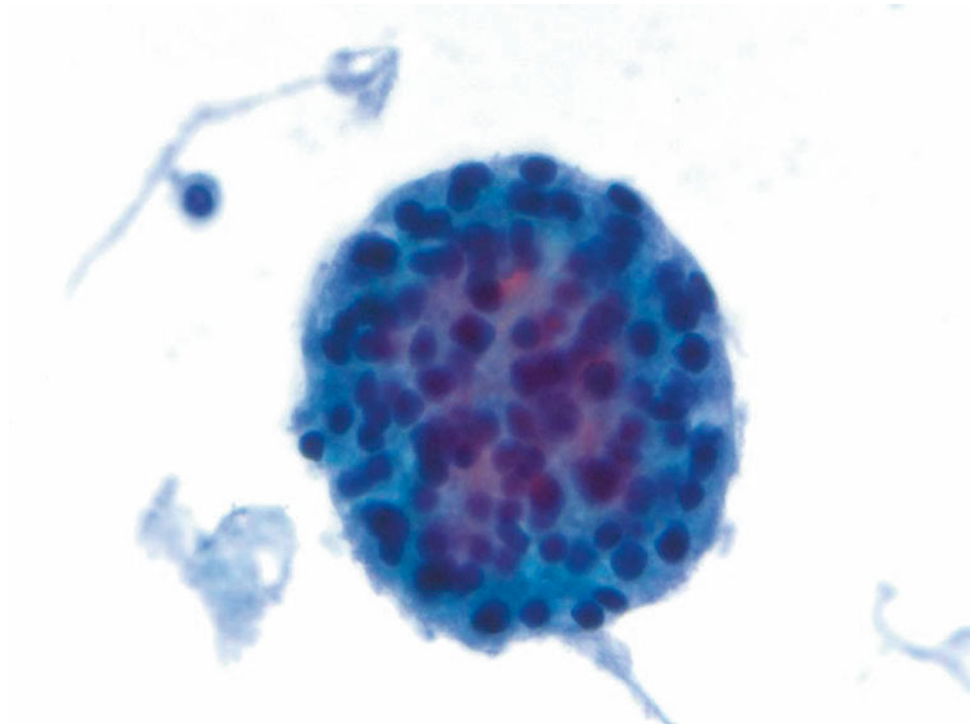
- Q-28. A 58-year-old male smoker with history of “lung cancer” develops a pleural effusion. What is the diagnosis of cells seen in this pleural effusion?
- (a) Metastatic adenocarcinoma
  - (b) Metastatic squamous cell carcinoma
  - (c) Reactive mesothelial cells
  - (d) Metastatic melanoma

**Fig. 2.29**

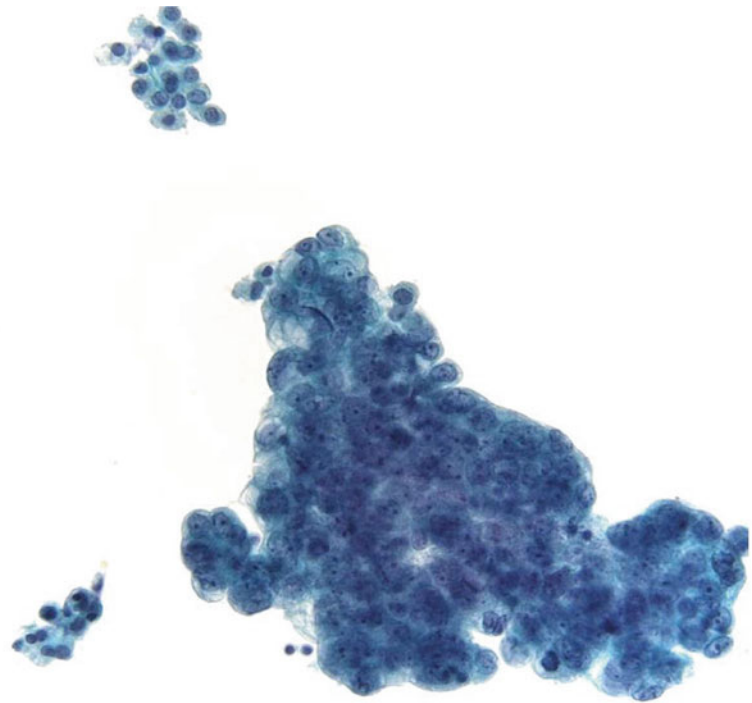
- Q-29. Surgical peritoneal washing was performed for staging purpose. What is the diagnosis of this cytological specimen?
- (a) Metastatic adenocarcinoma of the colon
  - (b) Metastatic squamous cell carcinoma
  - (c) Reactive mesothelial cells
  - (d) Metastatic serous carcinoma

**Fig. 2.30**

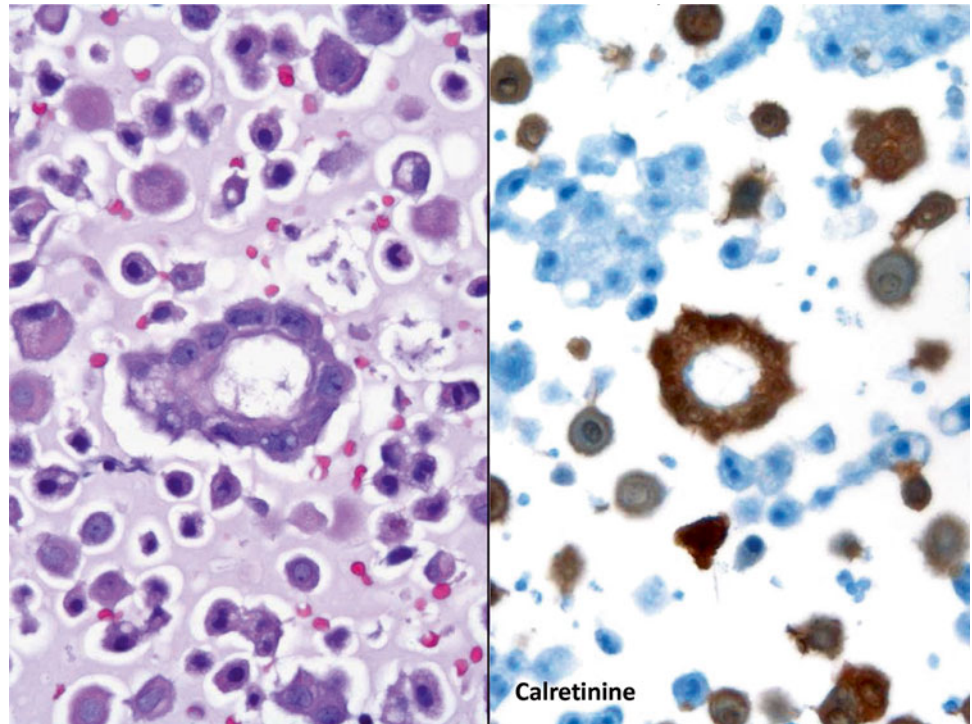
- Q-30. A 58-year-old female with history of breast cancer and radiation and chemotherapy develops a pleural effusion. What is the diagnosis of cells seen in this pleural effusion?
- (a) Metastatic adenocarcinoma
  - (b) Metastatic squamous cell carcinoma
  - (c) Reactive mesothelial cells
  - (d) Metastatic melanoma

**Fig. 2.31**

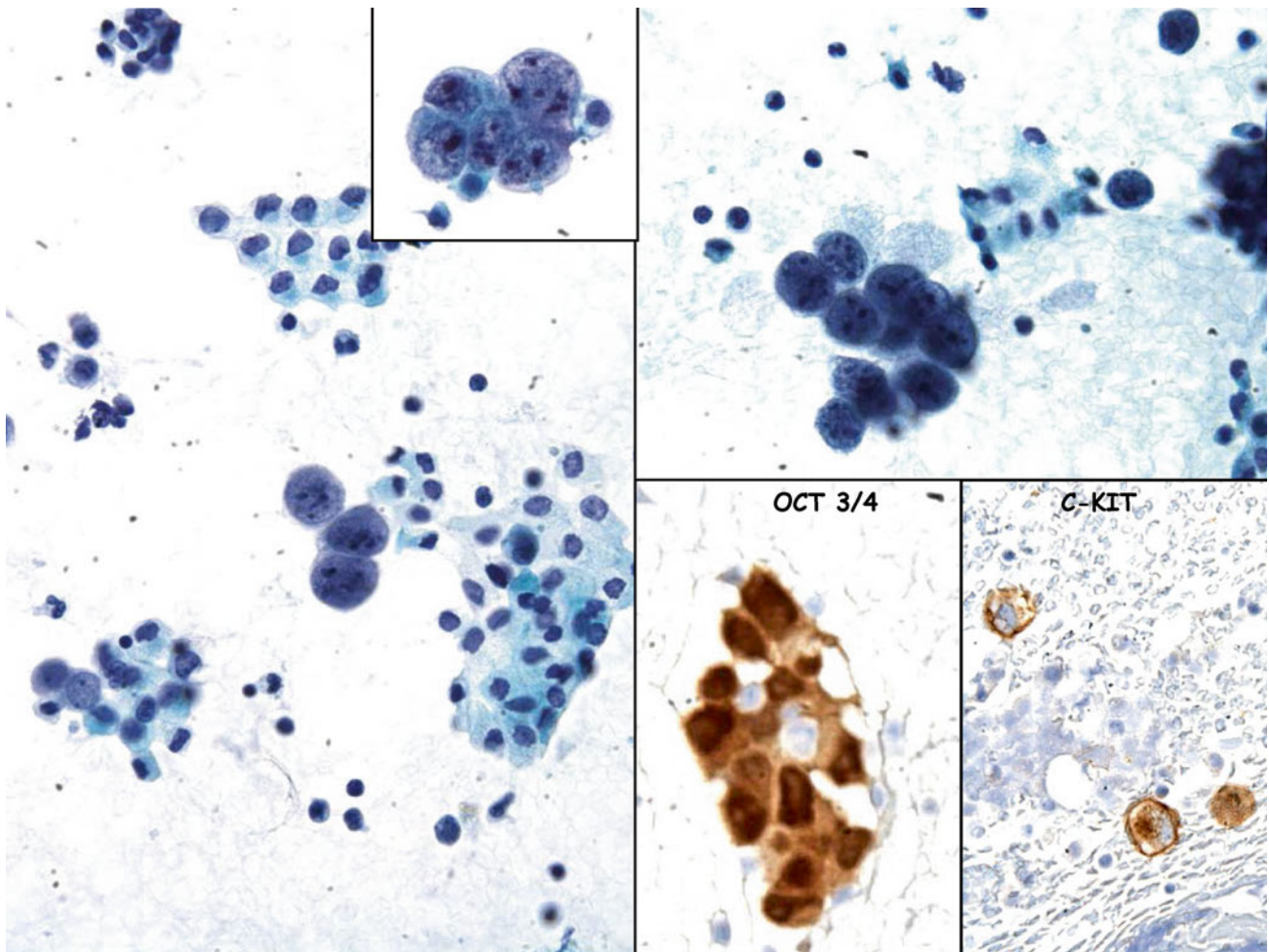
- Q-31. The diagnosis of a malignant pleural effusion was made in this specimen. Which panel of immunomarkers can help you confirm the diagnosis?
- (a) Cytokeratin and CK7
  - (b) Calretinin, TTF, and BerEP4
  - (c) Chromogranin A, synaptophysin, and CD56
  - (d) CD20, CD3, and CD56

**Fig. 2.32**

- Q-32. The diagnosis of a malignant pleural effusion was made on this specimen. What is the diagnosis of cells seen in this pleural effusion?
- (a) Metastatic mucinous adenocarcinoma
  - (b) Metastatic squamous cell carcinoma
  - (c) Reactive mesothelial cells
  - (d) Metastatic small cell carcinoma

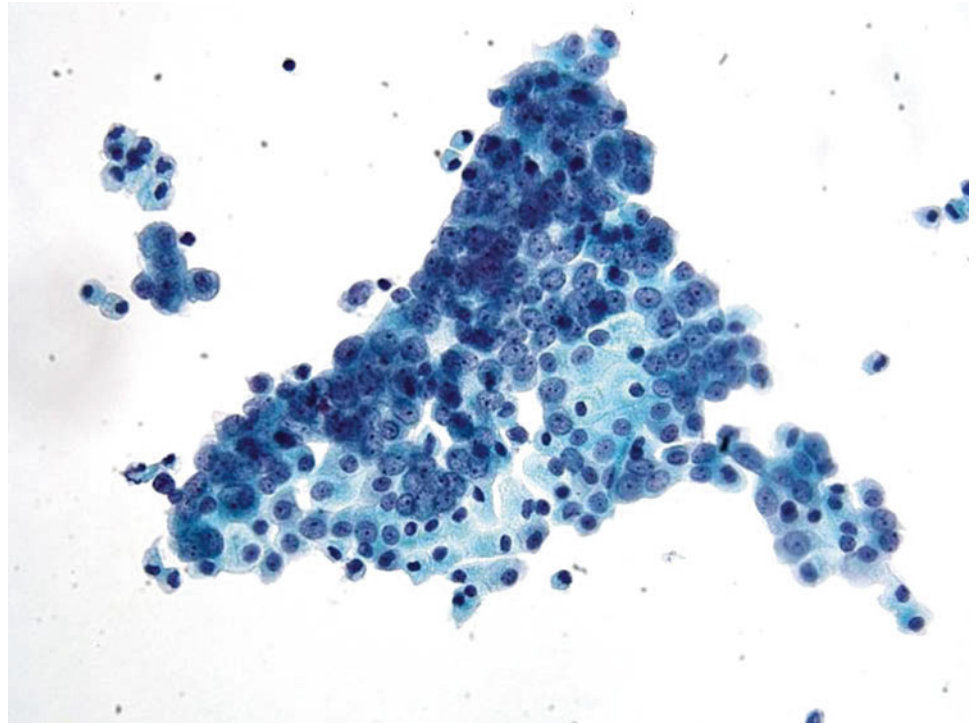
**Fig. 2.33**

- Q-33. Surgical peritoneal washing was performed. What is the diagnosis of this cytological specimen (cell block preparation)?
- (a) Metastatic adenocarcinoma of the colon
  - (b) Mesothelioma
  - (c) Reactive mesothelial cells
  - (d) Metastatic serous carcinoma of the ovary

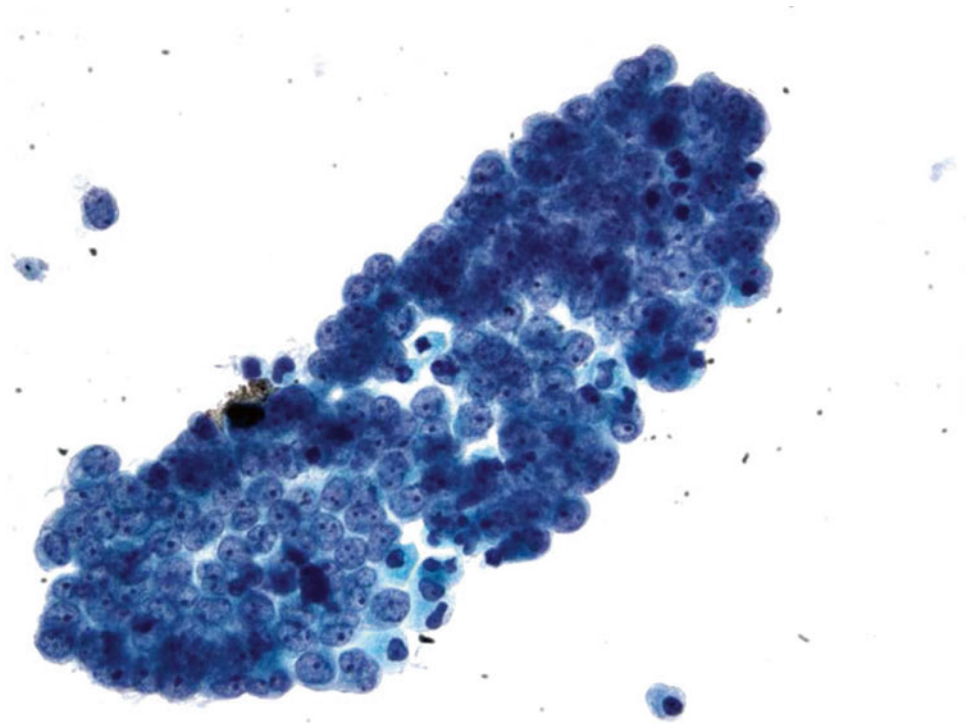


**Fig. 2.34**

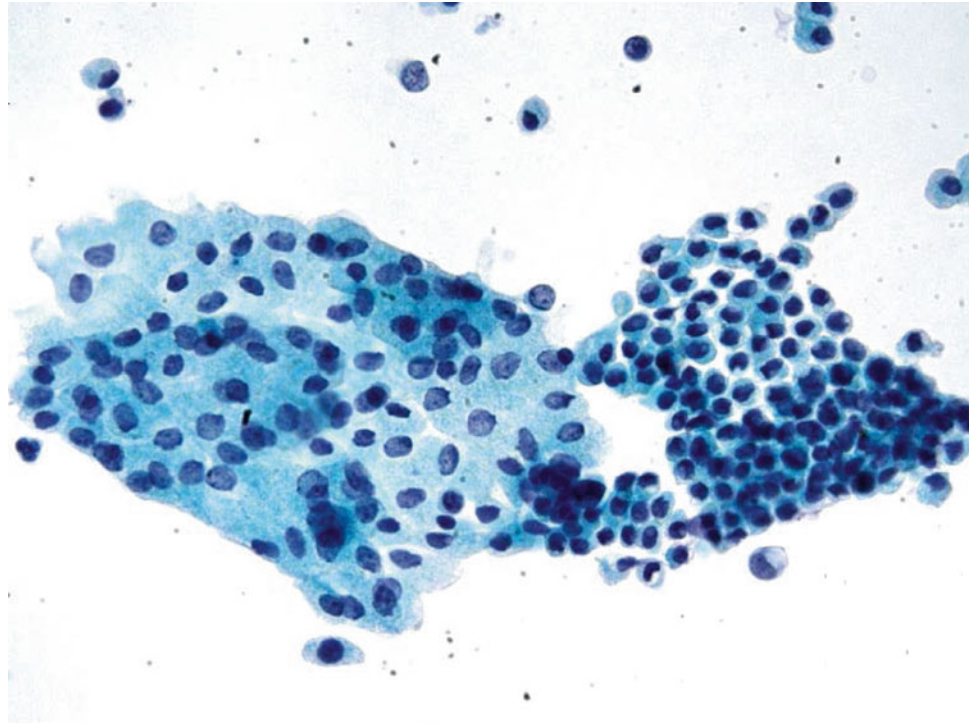
- Q-34. A 22-year-old female with an ovarian mass. During her surgery, pelvic washing was performed. What is the diagnosis of this cytological specimen?
- (a) Metastatic adenocarcinoma of the colon
  - (b) Metastatic dysgerminoma
  - (c) Reactive mesothelial cells
  - (d) Metastatic serous carcinoma of the ovary

**Fig. 2.35**

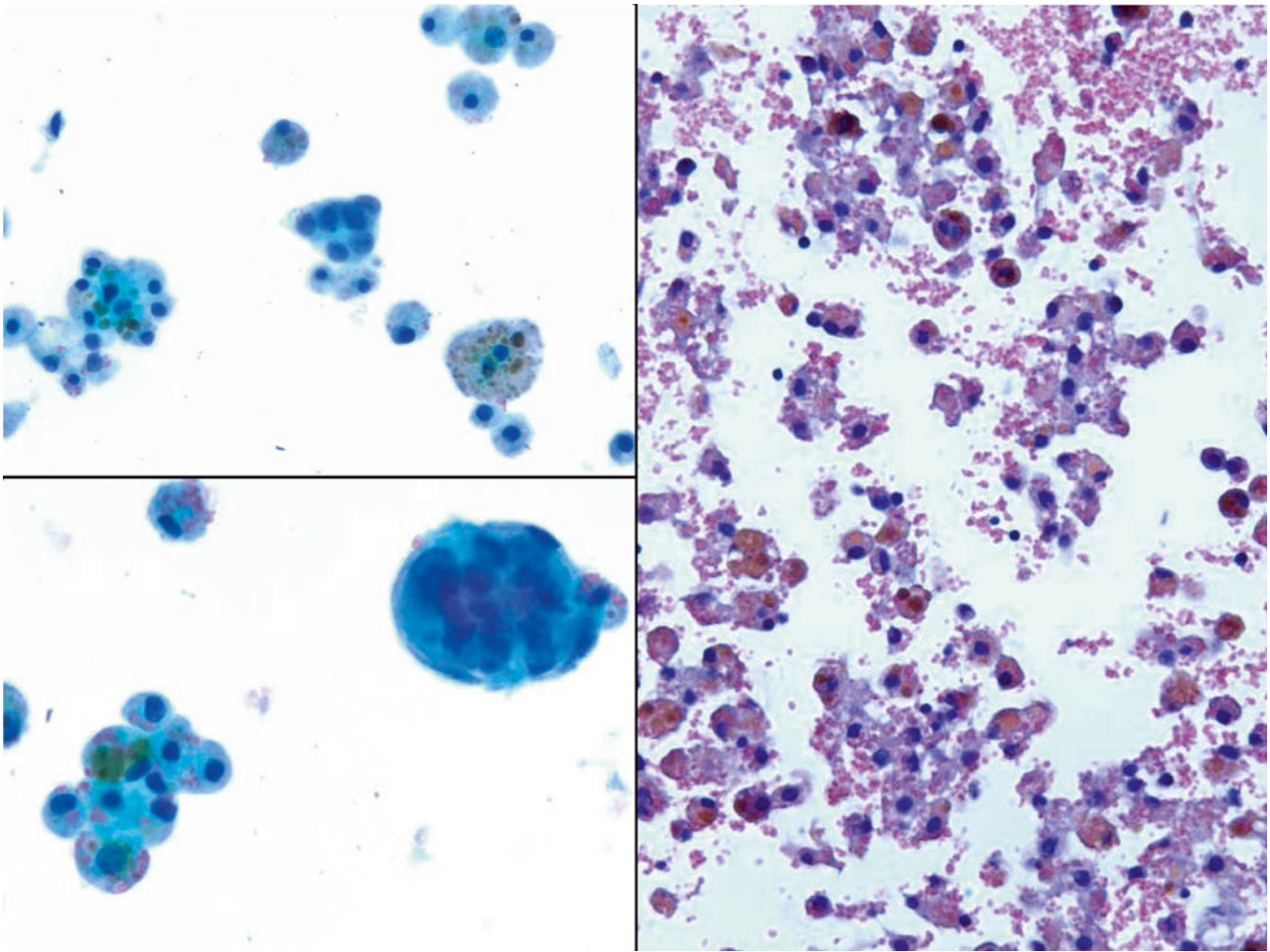
- Q-35. Surgical peritoneal washing was performed. What is the diagnosis of this cytological specimen?
- (a) Metastatic adenocarcinoma of the colon
  - (b) Mesothelioma
  - (c) Reactive mesothelial cells
  - (d) Metastatic serous carcinoma of the ovary

**Fig. 2.36**

- Q-36. Surgical peritoneal washing was performed. What is the diagnosis of this cytological specimen?
- (a) Metastatic adenocarcinoma of the colon
  - (b) Mesothelioma
  - (c) Reactive mesothelial cells
  - (d) Metastatic serous carcinoma of the ovary

**Fig. 2.37**

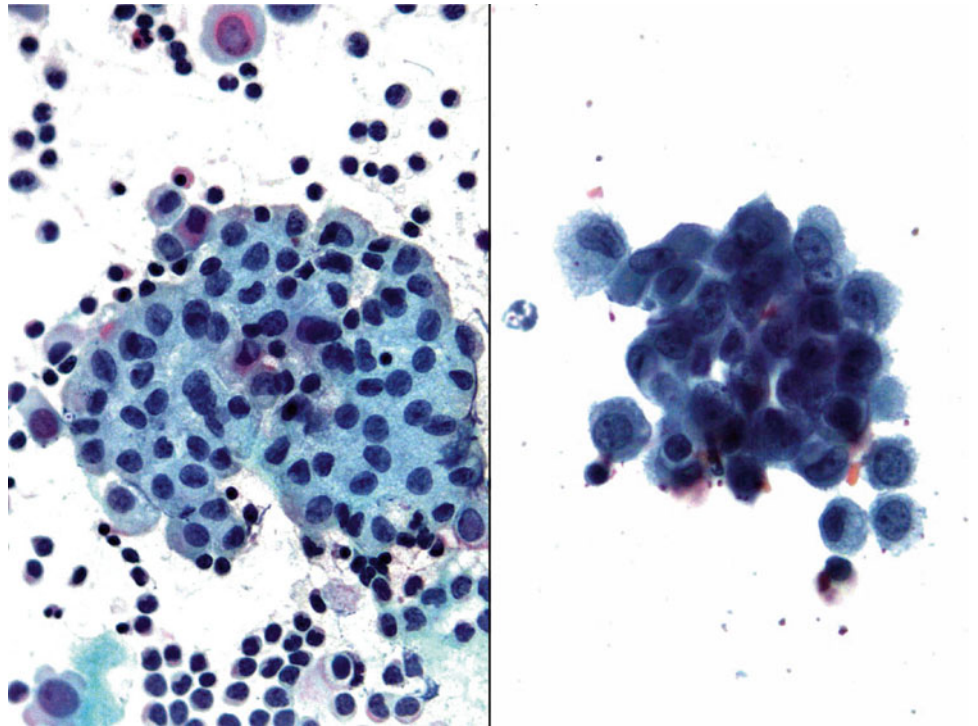
- Q-37. Surgical peritoneal washing was performed. What is the diagnosis of this cytological specimen?
- (a) Metastatic adenocarcinoma of the colon
  - (b) Reactive mesothelial cells
  - (c) Mesothelioma
  - (d) Metastatic serous carcinoma of the ovary



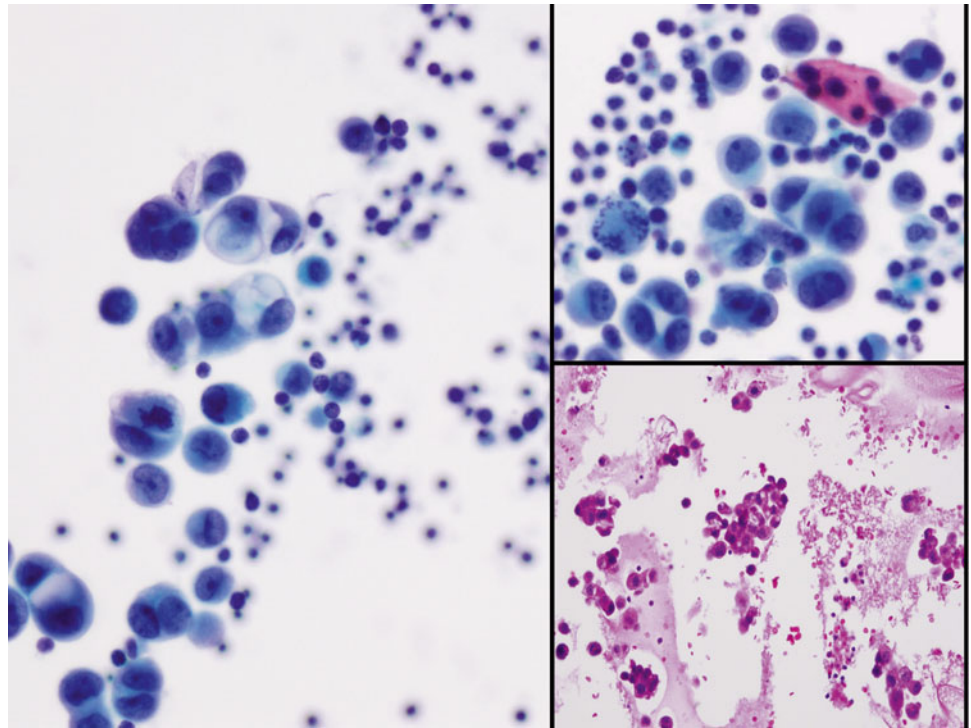
**Fig. 2.38**

Q-38. A 35-year-old with an ovarian mass had a surgical resection of the lesion. Pelvic washing was performed during the procedure. The resected lesion reveals a hemorrhagic cyst. What is the diagnosis of this pelvic washing specimen?

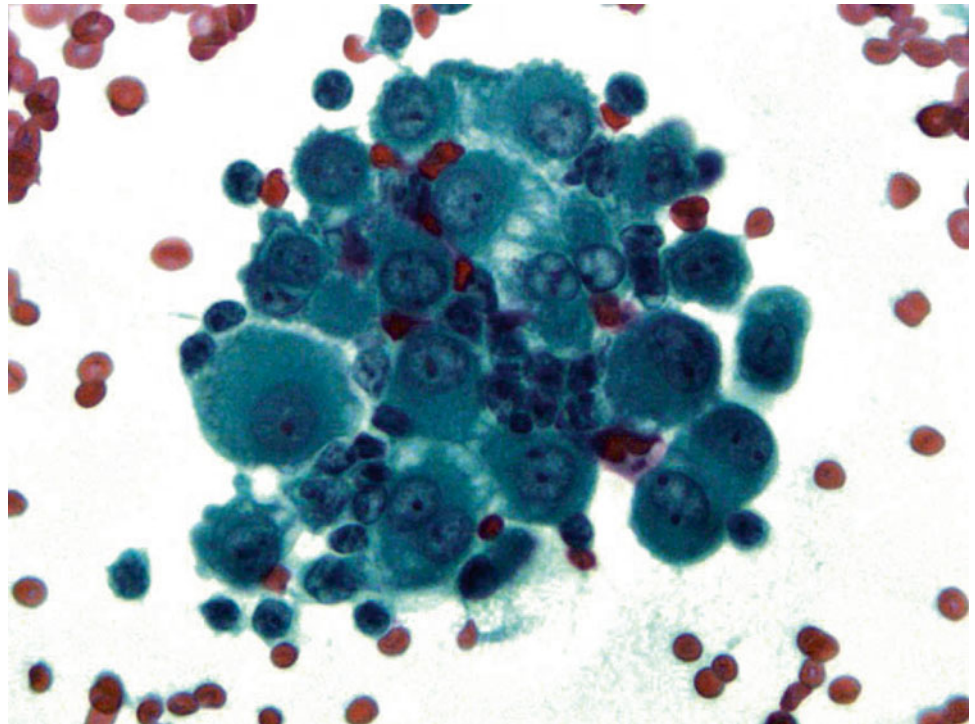
- (a) Metastatic adenocarcinoma of the colon
- (b) Reactive mesothelial cells
- (c) Endometriosis
- (d) Metastatic serous carcinoma of the ovary

**Fig. 2.39**

- Q-39. Surgical peritoneal washing was performed. What is the diagnosis of this cytological specimen?
- (a) Metastatic adenocarcinoma
  - (b) Reactive mesothelial cells
  - (c) Mesothelioma
  - (d) Metastatic serous carcinoma of the ovary

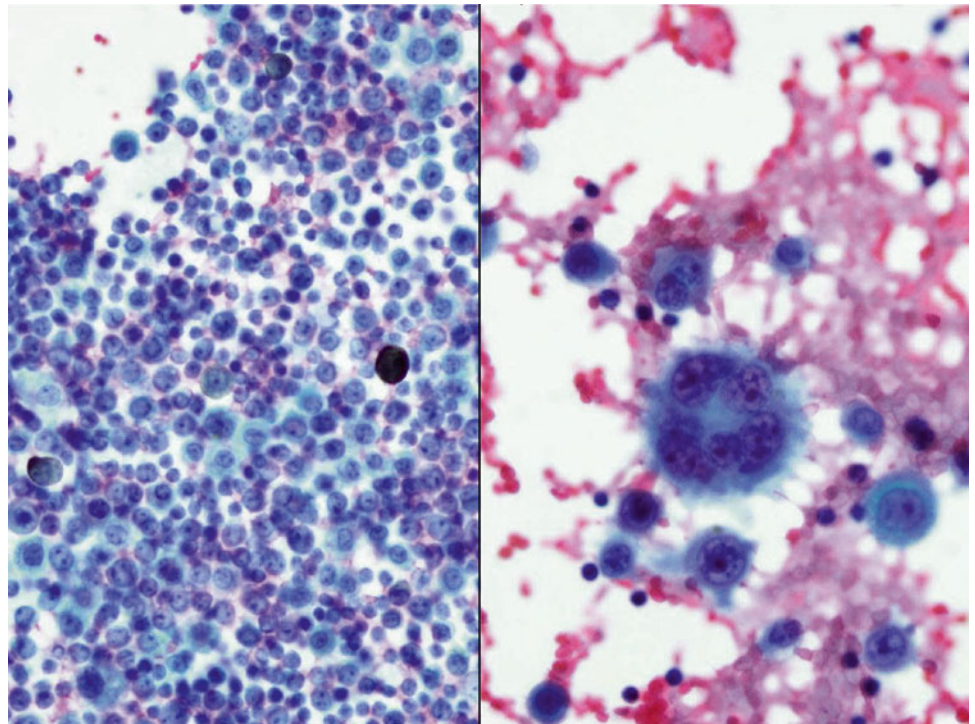
**Fig. 2.40**

- Q-40. An 87-year-old female nonsmoker with a lung mass develops a pleural effusion. What is the diagnosis of this cytological specimen?
- (a) Metastatic adenocarcinoma of the lung
  - (b) Reactive mesothelial cells
  - (c) Metastatic melanoma
  - (d) Metastatic squamous cell carcinoma

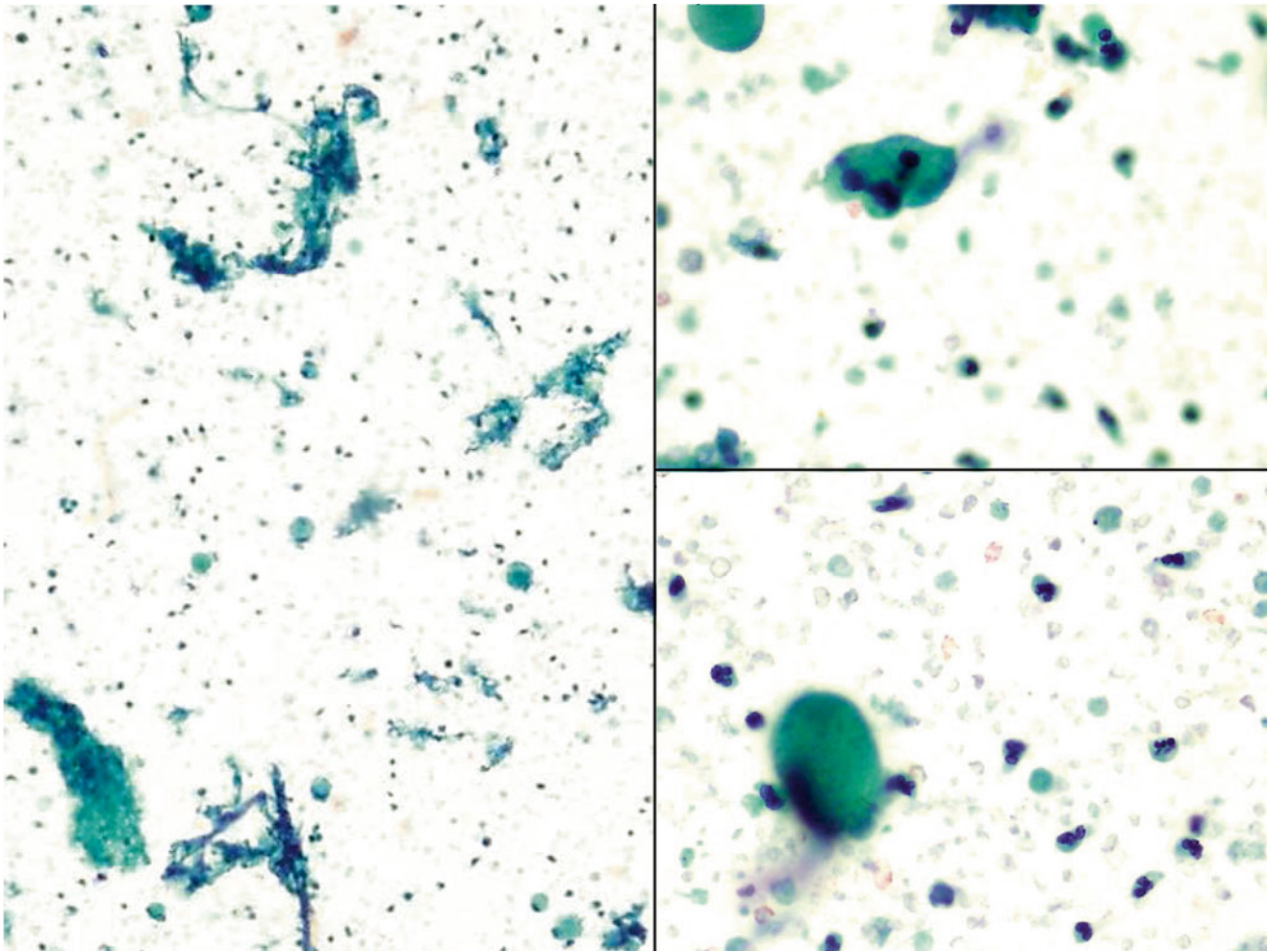
**Fig. 2.41**

Q-41. What is the diagnosis of this pleural effusion specimen?

- (a) Metastatic adenocarcinoma
- (b) Reactive mesothelial cells
- (c) Mesothelioma
- (d) Metastatic serous carcinoma of the ovary

**Fig. 2.42**

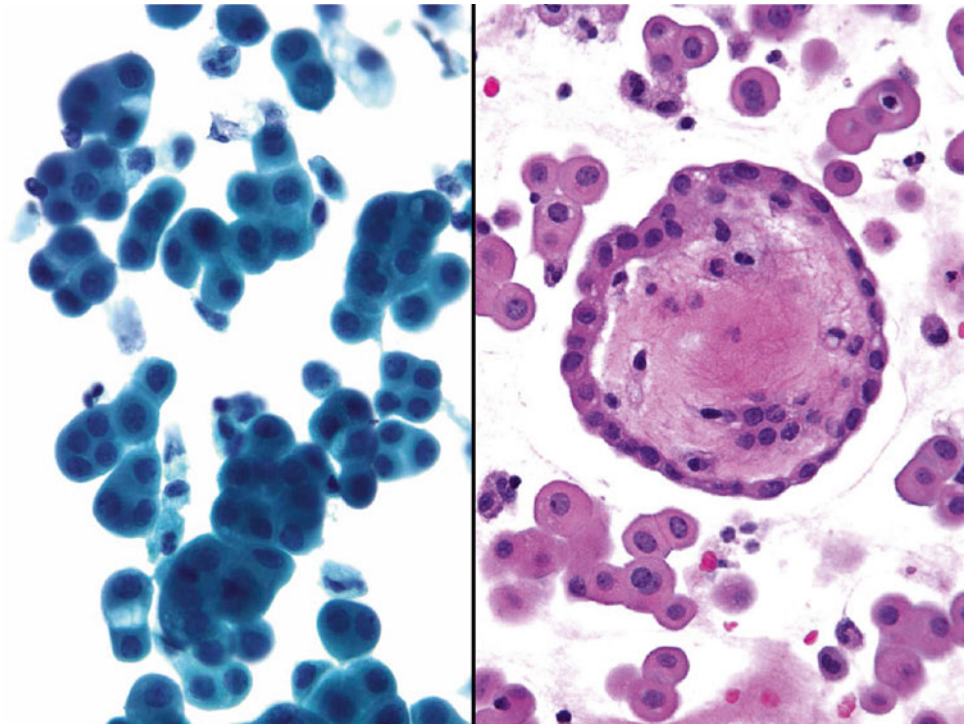
- Q-42. Which one of the following diagnoses is correct?
- (a) Metastatic poorly differentiated adenocarcinoma of the lung
  - (b) Metastatic small cell lung carcinoma
  - (c) Metastatic melanoma
  - (d) Lymphoma



**Fig. 2.43**

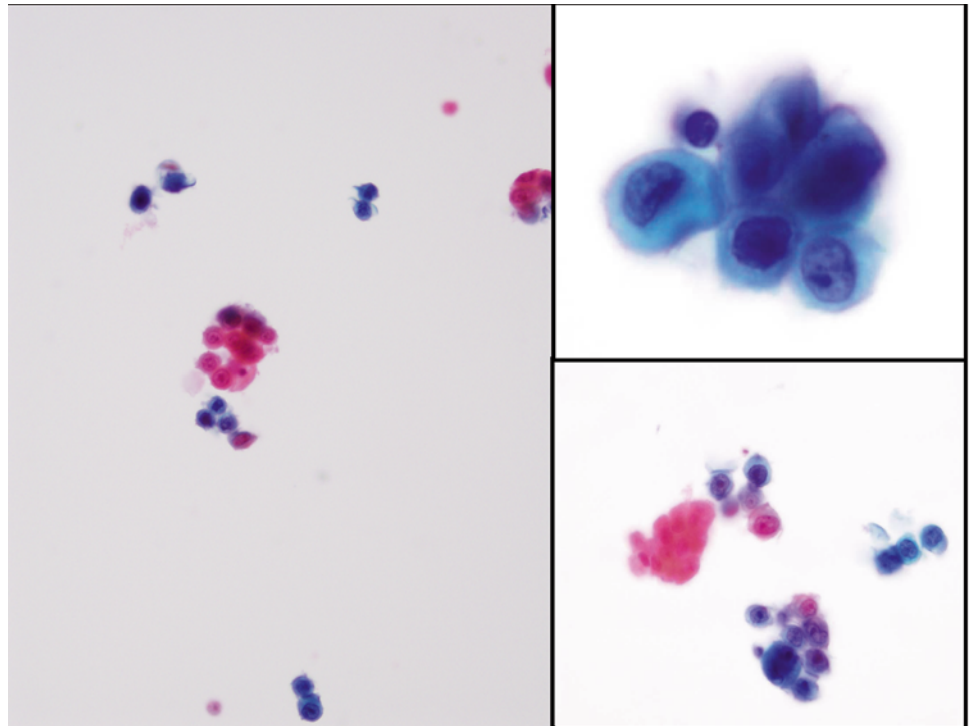
Q-43. Pleural effusion was found in a patient with rheumatoid arthritis. What is the diagnosis of this pleural effusion?

- (a) Rheumatoid pleuritis
- (b) Reactive mesothelial cells
- (c) Lymphocytosis
- (d) Lymphoma

**Fig. 2.44**

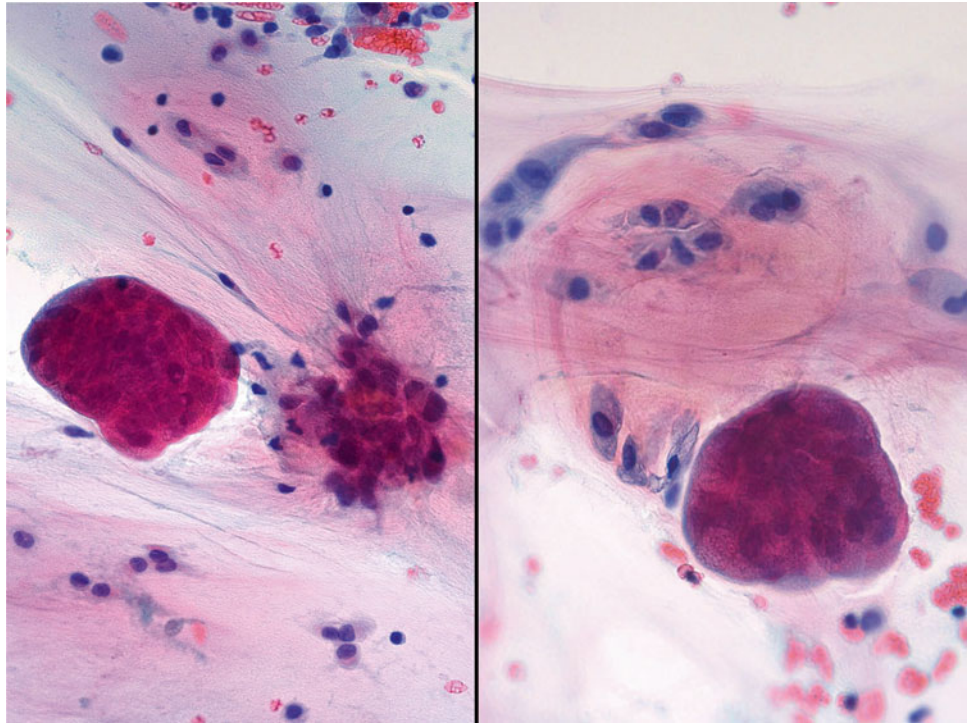
Q-44. What is the diagnosis of this cytological specimen?

- (a) Metastatic adenocarcinoma
- (b) Mesothelioma
- (c) Reactive mesothelial cells
- (d) Metastatic serous carcinoma of the ovary

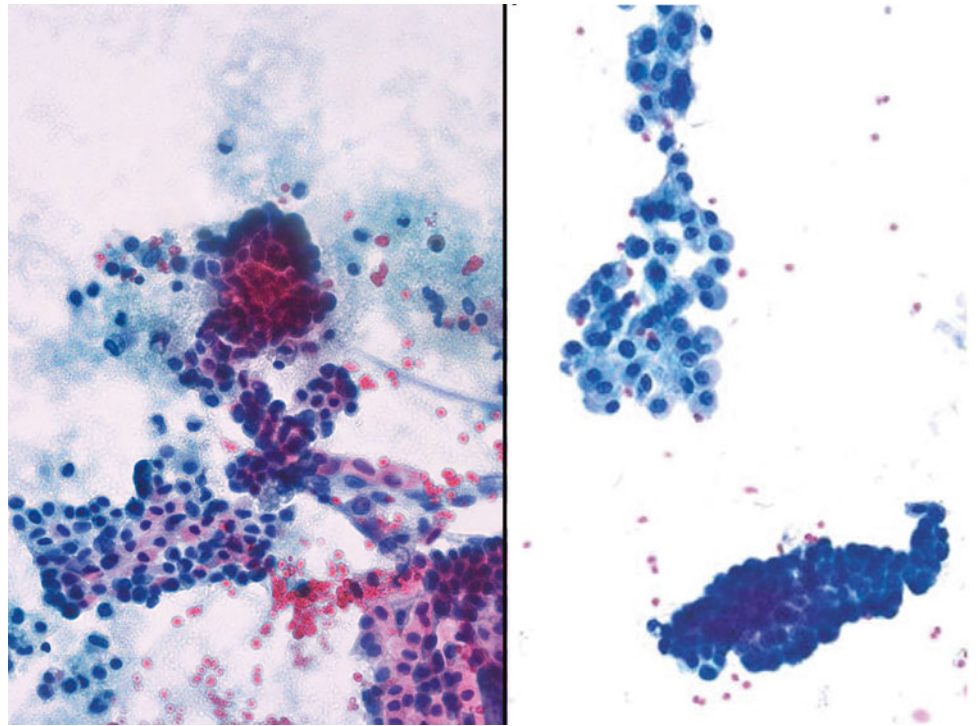
**Fig. 2.45**

Q-45. What is the diagnosis of this pleural effusion specimen?

- (a) Metastatic adenocarcinoma
- (b) Mesothelioma
- (c) Reactive mesothelial cells
- (d) Metastatic squamous cell carcinoma

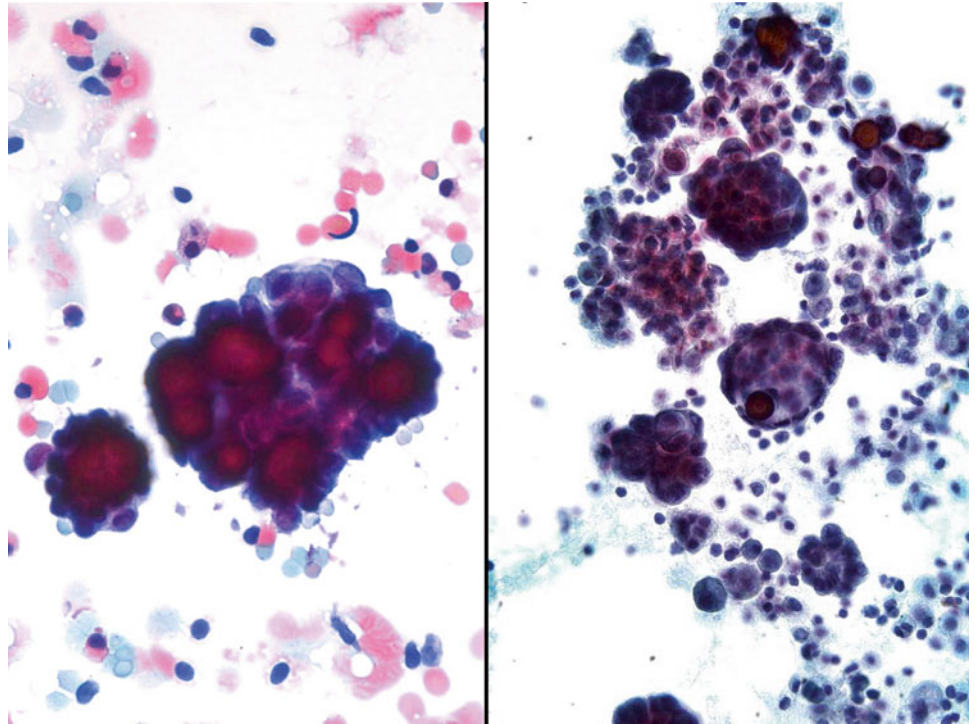
**Fig. 2.46**

- Q-46. A paracentesis was performed in a 46-year-old female patient with abdominal pain and distension. What is the diagnosis of cytological findings?
- (a) Metastatic adenocarcinoma
  - (b) Mesothelioma
  - (c) Reactive mesothelial cells
  - (d) Pseudomyxoma peritonei

**Fig. 2.47**

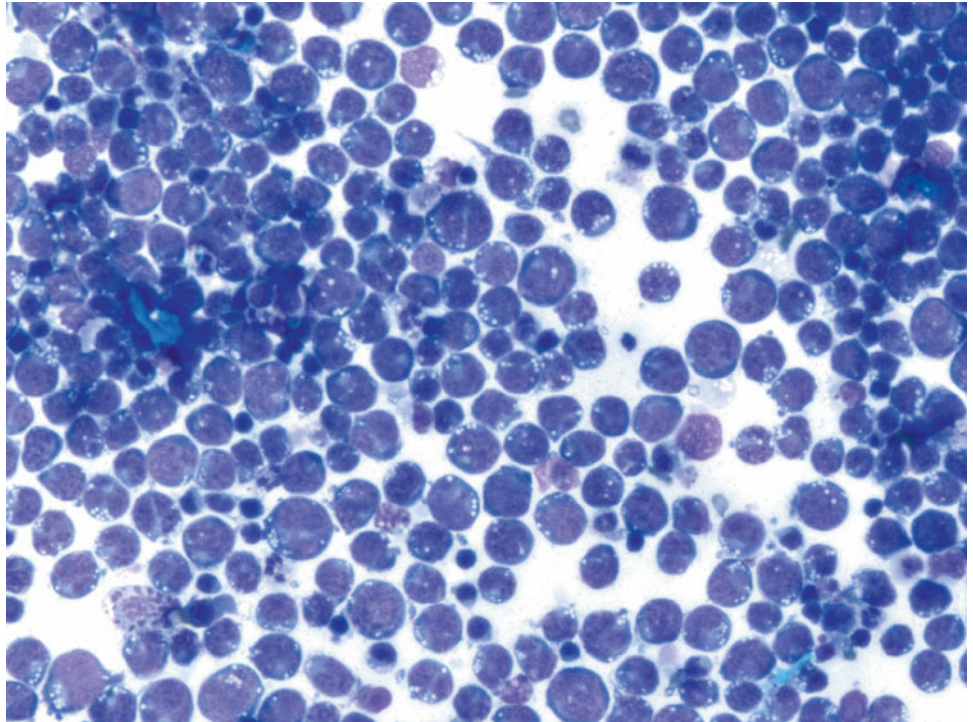
Q-47. What is the diagnosis of this pleural effusion specimen?

- (a) Metastatic adenocarcinoma
- (b) Reactive mesothelial cells
- (c) Mesothelioma
- (d) Metastatic serous carcinoma of the ovary

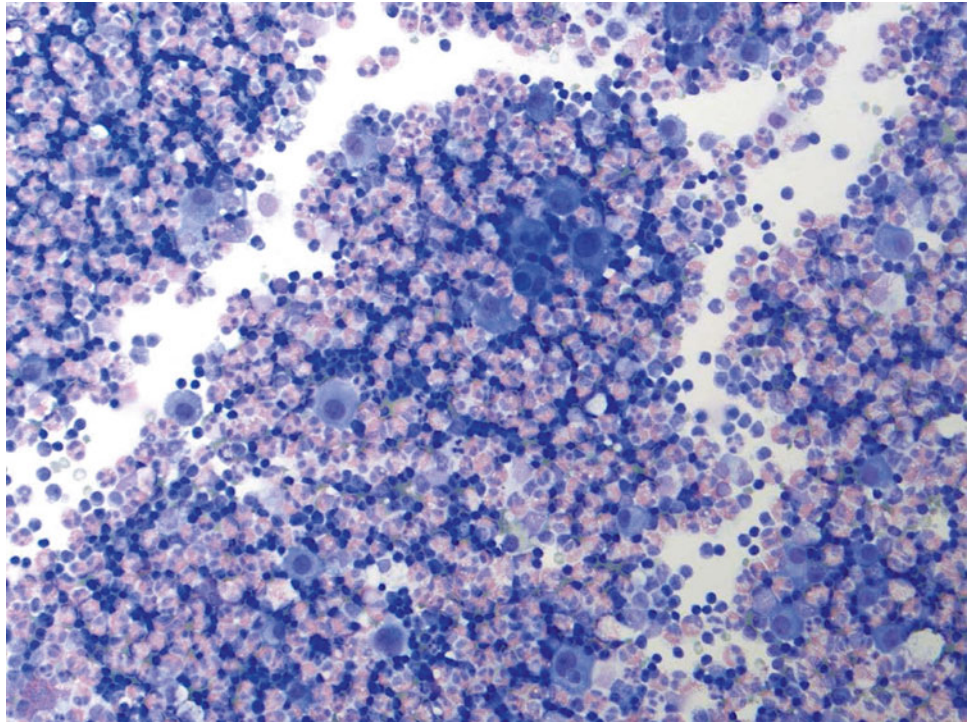
**Fig. 2.48**

Q-48. In this ascites specimen, what is the correct diagnosis?

- (a) Metastatic serous carcinoma
- (b) Mesothelial cell hyperplasia
- (c) Endosalpingiosis
- (d) Metastatic squamous cell carcinoma

**Fig. 2.49**

- Q-49. What is the diagnosis of this pleural effusion from a 66-year-old male with HIV infection?
- (a) Diffuse large B cell lymphoma
  - (b) Hodgkin lymphoma
  - (c) Burkitt lymphoma
  - (d) Lymphocytic pleural effusion

**Fig. 2.50**

Q-50. What is the correct diagnosis of this pleural effusion?

- (a) Diffuse large B cell lymphoma
- (b) Hodgkin lymphoma
- (c) Eosinophilic pleural effusion
- (d) Lymphocytic pleural effusion

## 2.2 Text-Based Questions 51–100

- Q-51. In a pleural effusion, all of the following features are seen in reactive mesothelial cells, except:
- Scattered individual “atypical” mesothelial cells
  - A spectrum of cellular changes, ranging from “normal” to “atypical” mesothelial cells
  - Variation in nuclear size, binucleation, and multinucleation
  - Numerous large three-dimensional cellular clusters
- Q-52. Which panel of immunohistochemical markers is the most useful in the differential diagnosis of mesothelioma from a metastatic adenocarcinoma of the lung?
- AE1/AE3, CK7, TTF1, calretinin, Ki67, WT1, and P53
  - BerEP4, Napsin A, TTF1, calretinin, WT1, and P53
  - AE1/AE3, CK7, CK20, TTF1, calretinin, and Ki67
  - BerEP4, Napsin A, TTF1, calretinin, and Ki67
- Q-53. Which one of the following is the most useful feature for separating reactive mesothelial cells (reactive atypia) from a well-differentiated lung adenocarcinoma?
- Two- or three-dimensional clusters of cells with nuclear variations
  - “Window” between atypical cells
  - Normal to low N/C ratio
  - Binucleation and/or multinucleation
- Q-54. An ultrasound-guided thoracentesis was performed on a 65-year-old male smoker who has a right pleural effusion and a right lower pleura-based mass. The cytospin smear reveals numerous large clusters of epithelioid cells with well-defined cell borders, large nuclei and prominent nucleoli, and intercellular “windows.” What is the most likely diagnosis?
- Reactive mesothelial cells
  - Well-differentiated adenocarcinoma of the lung
  - Poorly differentiated carcinoma
  - Mesothelioma
- Q-55. All of the following features can be seen in a squamous cell carcinoma, except:
- Smudgy chromatin
  - Dense cytoplasm
  - Prominent nucleoli
  - Shared cell borders
- Q-56. Radiation- and chemotherapy-induced mesothelial changes include all of the following, except:
- Cytomegaly with proportionate nuclear enlargement
  - Multinucleation and a vesicular chromatin pattern
  - Prominent nucleoli
  - Hyperchromatic nucleoli and clumped chromatin
- Q-57. A 60-year-old male patient presents with left pleural effusion. An ultrasound-guided thoracentesis was performed. On cytology smear and cell block section, lymphoid population and rare mesothelial cells were identified. Which of the following features is considered an “abnormal” lymphoid population?
- Polymorphous population of lymphocytes
  - “Lacunar” space on cell block section
  - Monomorphous population of lymphocytes
  - Lymphoglandular bodies
- Q-58. On a scant effusion specimen, which of the following tumors is most likely to be mistaken for “reactive mesothelial cells”?
- Adenocarcinoma with lepidic growth pattern (bronchoalveolar carcinoma)
  - Poorly differentiated squamous cell carcinoma
  - Basaloid carcinoma
  - Small cell carcinoma
- Q-59. The differential diagnosis of eosinophils in pleural effusion (eosinophilic pleural effusion) includes all of the following, except:
- Repeat tap (thoracentesis)
  - Renal transplantation
  - Mesothelioma
  - Tuberculosis
- Q-60. Fluid cytology is more sensitive than a “blind” serosal biopsy for the detection of serosal malignancy.
- True
  - False
- Q-11. The most common cause of eosinophilic pleural effusion is:
- Blood in the pleural space (hemothorax)
  - Lung cancers
  - Air in the pleural space (pneumothorax)
  - Tuberculosis

- Q-62. Which of the following irritation/trauma induces a rapid development of eosinophilic pleural effusion in hours?
- Blood in the pleural space (hemothorax)
  - Air in the pleural space (pneumothorax)
  - Pleural biopsy
  - Repeat thoracentesis
- Q-63. The most common cause of eosinophilic ascites is:
- Metastatic colon cancers
  - Metastatic lung cancers
  - Blood in the peritoneal space
  - Cirrhosis
- Q-64. Metastatic squamous cell carcinomas in the fluid cytology can be distinguished from metastatic adenocarcinomas based on the presence of the following features, except:
- Keratinization
  - Mucin production (cytoplasmic mucin)
  - Pseudoacinar arrangement of tumor cells
  - Prominent nucleoli
- Q-65. A thoracentesis was performed on a 65-year-old male smoker who presented with a right upper lobe infiltration and pleural effusion. On the cytological preparation, large sheets and tight clusters of atypical epithelioid cells are identified; some of them have “signet ring” cell features. The differential diagnoses include:
- Metastatic adenocarcinoma of the lung
  - Reactive mesothelial cell hyperplasia
  - A metastatic adenocarcinoma from the stomach
  - All of the above
- Q-66. Cytological features of so-called neuroendocrine tumors may include all of the following, except:
- Fine chromatin pattern (so-called “salt-and-pepper” pattern)
  - Inconspicuous or small nucleoli
  - Scant cytoplasm
  - Nuclear grooves
- Q-67. Which type of mucin is commonly seen in mesothelioma?
- Neutral
  - Acid (simple or non-sulfated)
  - Acid (simple, mesenchymal)
  - Acid (complex or sulfated, epithelial)
- Q-68. Which type of mucin stain is more specific to demonstrate mucopolysaccharide substances in tissues (i.e., mucin in adenocarcinoma)?
- Colloidal iron
  - Alcian blue
  - PAS (Periodic acid–Schiff)
  - Mucicarmine
- Q-69. A cytological smear of ascites reveals numerous two-dimensional clusters and/or sheets of spindle cells; the differential diagnosis of the lesion includes all of the following, except:
- Spindle cell carcinoma
  - Sarcomatoid mesothelioma
  - Metastatic melanoma
  - Poorly differentiated adenocarcinoma
- Q-70. Which feature is not seen in a small cell carcinoma?
- Paranuclear blue bodies in the cytoplasm
  - The size of tumor cells are two- to threefold of mature lymphocytes
  - Abundant cytoplasm
  - Nuclear crowding and molding
- Q-71. Which of the following cytological features is helpful in the differential diagnosis of large cell neuroendocrine tumor from a poorly differentiated adenocarcinoma in a pleural effusion specimen?
- Fine (salt-and-pepper) chromatin pattern
  - Three-dimensional and/or pseudoacinar arrangements of tumor cells
  - Lacy cytoplasm with vacuolization
  - Dispersed tumor cells with markedly atypia and enlargement
- Q-72. A 50-year-old female developed chronic cough and shortness of breath. The chest x-ray showed bilateral small opaque infiltrates and left pleural effusion. The ultrasound-guided thoracentesis was performed. A large amount of fluid is obtained. The initial evaluation of the specimen revealed scattered clusters of atypical epithelioid cells, and a metastatic adenocarcinoma was suspected. What is the next step of action?
- Repeat thoracentesis in few weeks
  - Make cell block as usual
  - Core biopsy the lung lesions
  - Do nothing
- Q-73. An HIV-positive patient developed pleural and pericardial effusion. The cytological preparation of the effusion reveals numerous atypical lymphoid cells. A primary effusion lymphoma is suspected. Which of the following cytological features can be seen in primary effusion lymphoma?

- (a) Individual large lymphocyte with enlarged round nuclei  
 (b) Coarse chromatin and prominent nucleoli  
 (c) Abundant basophilic cytoplasm on the Diff-Quik stain  
 (d) All of the above
- Q-74. In a malignant ascites specimen, tumor cells were found to have “intranuclear inclusions.” Which one of the following tumors is the more likely to have an “intranuclear inclusion” in a fluid cytology?  
 (a) Renal cell carcinoma  
 (b) Urothelial cell carcinoma  
 (c) Colonic adenocarcinoma  
 (d) Hepatocellular carcinoma
- Q-75. A stage 3 lung cancer patient developed a pleural effusion. A thoracentesis was performed, and the cytological examination confirmed the diagnosis of metastatic adenocarcinoma of the lung. The oncologist asked you to send specimen for molecular studies of *EGFR* and *KRAS* mutations. What is the next step of action?  
 (a) Tell the clinician to obtain tumor tissue from primary tumor.  
 (b) Biopsy specimen is needed for molecular studies.  
 (c) Prepare cell blocks and make sure that they have adequate tumor cells.  
 (d) It is not necessary to do molecular study on metastatic lung adenocarcinoma.
- Q-76. In cytological preparation from ascites, the finding of psammoma bodies is suggestive of which of the following diagnoses?  
 (a) Ovarian carcinoma  
 (b) Mesothelial cell hyperplasia  
 (c) Endosalpingiosis  
 (d) All of the above
- Q-77. Which of the features is not seen in a metastatic squamous cell carcinoma in fluid specimens?  
 (a) Large nuclei with smudgy chromatin  
 (b) Nuclei with variation in size and shape  
 (c) Pyknotic nuclei  
 (d) Cytokeratin formation
- Q-78. An HIV-positive patient developed a lymphomatous effusion. The differential diagnosis should include all of the following, except:  
 (a) Burkitt’s or Burkitt’s-like lymphoma (BL)  
 (b) Diffuse large B-cell lymphoma (DLBCL)  
 (c) Peripheral T-cell non-Hodgkin lymphoma (NHL)  
 (d) Primary effusion lymphoma (PEL)
- Q-79. A paracentesis was performed on a patient with ascites. On the cell block preparation, it revealed three-dimensional clusters of tall columnar cells with hyperchromatic nuclei, coarse chromatin, prominent nucleoli, irregular nuclear membrane, and feathering cytoplasm. Which one is the most likely primary site of the tumor?  
 (a) Breast  
 (b) Lung  
 (c) Colon  
 (d) Renal
- Q-80. Which of the following cytological features is most useful in the separation of a poorly differentiated adenocarcinoma from a small cell carcinoma in fluid cytology specimen?  
 (a) Prominent nucleoli  
 (b) Fine or coarse chromatin pattern  
 (c) Tumor necrosis  
 (d) Organoid and/or rosette arrangement of tumor cells
- Q-81. A patient who had malignant history of desmoplastic/spindle cell melanoma developed ascites. In cytological preparations, scattered “atypical spindle cells” were identified. Which of the following options is the best one in the differential diagnosis of a metastatic desmoplastic/spindle cell melanoma?  
 (a) Using unstained slides to perform IHC markers S100, HMB45, and melanin A  
 (b) Making cell block to perform IHC markers S100, HMB45, and melanin A  
 (c) Making cell block to perform IHC marker of melanin A only  
 (d) Making cell block to perform IHC marker of S100 only
- Q-82. A female patient with a breast mass developed a pleural effusion. All of the following features can be seen in a metastatic breast carcinoma, except:  
 (a) Prominent nucleoli  
 (b) Intracytoplasmic lumina (magenta body)  
 (c) Three-dimensional cell clusters  
 (d) Naked nuclei
- Q-83. On a cell block preparation, which one of the following positive stains indicates a mesothelioma, but not a metastatic adenocarcinoma of the lung?  
 (a) Mucicarmine  
 (b) Periodic acid–Schiff (PAS)  
 (c) Hyaluronic acid–alcian blue  
 (d) Cytokeratin

- Q-84. In a cytological preparation of a pleural effusion from a patient who has breast cancer, the diagnosis of metastatic breast carcinoma is made. The characteristic cytological features include all of the following, except:
- (a) Hyperchromatic nuclei and prominent nucleoli
  - (b) Intranuclear inclusion
  - (c) Three-dimensional cell clusters with smooth border
  - (d) Bipolar nuclei
- Q-85. A fluid cytological preparation characteristic of a metastatic small cell carcinoma includes all of the following, except:
- (a) Hyperchromatic nuclei and prominent nucleoli
  - (b) Scant cytoplasm
  - (c) Three-dimensional cell clusters with nuclear molding
  - (d) Individual tumor cells with fine chromatin
- Q-86. In a fluid cytological preparation, the differential diagnosis of lymphocytic effusion includes which of the following?
- (a) Tuberculosis
  - (b) Metastatic carcinoma
  - (c) Small lymphocytic lymphoma/chronic lymphocytic leukemia
  - (d) All of the above
- Q-87. In a fluid cytological preparation, characteristics of a metastatic small cell carcinoma were found. Which of the following IHC markers has better sensitivity for detection of small cell carcinomas?
- (a) TTF1
  - (b) Synaptophysin
  - (c) Chromogranin A
  - (d) CD56
- Q-88. TTF1 is always positive in small cell lung carcinomas (SCLCs). It can be used to distinguish the origin of the tumor, i.e., pulmonary versus extrapulmonary origin. True or false?
- (a) True
  - (b) False
- Q-89. Which of the following tumors has a weak punctate (“dotlike”) labeling for cytokeratins, including AE1/AE3 and CAM 5.2?
- (a) Lung adenocarcinoma
  - (b) Small cell lung carcinoma
  - (c) Metastatic colonic adenocarcinoma to the lung
  - (d) Prostate adenocarcinoma
- Q-90. The patient with a mediastinal mass has presented with a left pleural effusion. On the cytospin, the specimen reveals “atypical small blue cells.” The main differentiation diagnosis of the pleural effusion is small cell lung carcinoma versus lymphoma. Of the following tests/markers, which one is the most useful for the differential diagnosis?
- (a) Immunostains of TTF1 and BerEP4
  - (b) Immunostains of AE1/AE3 and TTF1
  - (c) Immunostains of CD20 and CD5
  - (d) Immunostains of synaptophysin, chromogranin, CD56, and CD45
- Q-91. A fluid cytological preparation characteristic of “benign” nuclear enlargements and/or reactive nuclear changes in mesothelial cells includes all of the following, except:
- (a) Large nuclei in a cell with normal N/C ratio
  - (b) Irregular nuclear membrane and hyperchromasia
  - (c) Two-dimensional cell clusters with intercellular “window”
  - (d) Prominent nucleoli
- Q-92. Which one of the following procedures has the highest sensitivity in the diagnosis of malignant pleural lesions as well as malignant effusion?
- (a) Thoracentesis
  - (b) CT-guided transthoracic needle biopsy
  - (c) “Blind” transthoracic needle biopsy
  - (d) Ultrasound-guided transthoracic needle biopsy
- Q-93. In a patient with pleural effusion, a cytological specimen is routinely obtained by thoracentesis or ultrasound- and/or CT-guided thoracentesis. Which one of the procedures has the highest specificity in the diagnosis of malignant pleural effusion?
- (a) Thoracentesis
  - (b) CT-guided transthoracic thoracentesis
  - (c) “Blind” transthoracic needle biopsy
  - (d) Ultrasound-guided thoracentesis
- Q-94. In a malignant fluid specimen, the appearance of two- and three-dimensional tumor cell clusters is only seen in adenocarcinomas but not in squamous cell carcinomas. True or false?
- (a) True
  - (b) False
- Q-95. Pleural effusion was found in a patient with rheumatoid arthritis. The diagnostic features of rheumatoid pleuritis include:
- (a) Multinucleated giant cells
  - (b) Characteristic “granular” debris

- (c) Scattered lymphocytes  
(d) All of the above
- Q-96. Which type of cells is usually not present in a rheumatoid pleuritis?  
(a) Multinucleated giant cells  
(b) Lymphocytes  
(c) Mesothelial cells  
(d) Clusters of histiocytes
- Q-97. Charcot–Leyden crystals can be found in:  
(a) Asthma  
(b) Eosinophilic effusion  
(c) Allergic sinusitis  
(d) All of the above
- Q-98. All of these statements/descriptions of the lupus erythematosus (LE) cell are correct in lupus pleuritis, except:  
(a) The characteristic cell is the lupus erythematosus (LE) cells.  
(b) LE cells contain denatured nuclear material with a glassy and homogeneous appearance.  
(c) LE cells can be identified in the majority of lupus pleuritis patients.  
(d) LE cells contain nuclear material with visible chromatin structures, such as coarse chromatin granules.
- Q-99. In a fluid specimen, which one of the following features is indicative of a malignant effusion?  
(a) Numerous large clusters of cells  
(b) Lacunae spaces on cell block preparation  
(c) Presence of “second population” cells  
(d) All of the above
- Q-100. The finding of clear spaces (lacunae) either around individual cells or around clusters of cells is characteristic of malignant effusion. True or false?  
(a) True  
(b) False

## 2.3 Answers and Discussion of Image-Based Questions 1–50

### A-1. (c) Collagen ball

The finding of a collagen ball in peritoneal washing specimens is not uncommon. Collagen balls are composed of collagen which is covered with a thin layer of benign mesothelial cells. One study has shown that collagen balls were found in 1.6 % of peritoneal washings and 5.8 % of pelvic washings, respectively. Collagen balls are a nonspecific finding and most probably originate on the surface of the ovary. It can be found in benign conditions and/or from detached fragments of a papillary ovarian neoplasm. Common differential diagnoses of collagen balls include metastatic mucinous adenocarcinomas, papillary serous carcinomas of the ovary, and mesotheliomas. In all these malignant lesions, tumor cells reveal high N/C ratio, hyperchromatic nuclei, irregular nuclear membrane, and prominent nucleoli.

### A-2. (a) Lupus erythematosus (LE) cells

The lupus erythematosus (LE) cell is a neutrophil or macrophage that has phagocytized (engulfed) the denatured nuclear material (hematoxylin body) of another cell. Denatured nuclear material in the neutrophil/macrophage has a glassy and homogeneous appearance; it may push the nuclei to the peripheral location. In contrast, tart cells contain ingested nuclei with a visible chromatin rather than homogeneous appearance. Reactive mesothelial cells have “windows” between cells, and mucin-producing cells, such as a mucin-producing adenocarcinoma, have cytoplasmic vacuole and lacy cytoplasm.

### A-3. (d) Metastatic breast lobular carcinoma

The diagnosis of this pericardial effusion is metastatic breast carcinoma. In fluid preparation, metastatic breast carcinoma may reveal several patterns. Tumor cells of metastatic ductal carcinoma may form three-dimensional “cannon ball” clusters. In cases of poorly differentiated (high-grade) ductal carcinomas, specimens consist of predominantly dispersed individual cells, whereas in metastatic lobular carcinomas, tumor cells are predominantly presented as dispersed individual cells. The size of tumor cells is relatively smaller than metastatic adenocarcinomas from the lung and/or GI tract. The presence of intracytoplasmic lumina, so-called magenta bodies, is also one of the characteristics of a metastatic breast carcinoma. In metastatic adenocarcinomas of the lung, columnar tumor cells are arranged in

three-dimensional or acinar/papillae clusters, with high N/C ratio, prominent nucleoli, lacy cytoplasm, and cytoplasmic vacuolization. The size of tumor cells is larger than those in breast carcinomas. Reactive mesothelial cells have “windows” between cells. Metastatic melanomas reveal dispersed large tumor cells with prominent nucleoli, binucleation, and cytoplasmic melanin pigments.

### A-4. (c) Ewing’s sarcoma

Ewing’s sarcoma is a malignant small, round, blue cell tumor. It predominantly involves males and usually presents in childhood or early adulthood, with a peak between 10 and 20 years of age. The tumor can occur anywhere in the body but most commonly in the pelvis and proximal long tubular bones. The cytological preparations reveal dispersed individual small blue cells with two types of tumor cells (tigroid appearance), i.e., tumor cells with pale nuclei and fine chromatin, and degenerated tumor cells with hyperchromatic nuclei and smudged chromatin. Nuclear molding is common. The cytoplasm is scant and with vacuolization. Ewing’s sarcoma cells are positive for CD99 and MIC2 and negative for CD45. The most common translocation, present in approximately 90 % of Ewing’s sarcoma cases, is t(11;22)(q24;q12). Other translocations are at t(21;22) and t(7;22). The differential diagnosis includes lymphoma, alveolar rhabdomyosarcoma, desmoplastic small round cell tumor, small cell carcinoma, and others.

### A-5. (d) Mesothelioma

The cytological finding of mesotheliomas reveals numerous three-dimensional clusters with scalloped (knobby) edges, characteristic of mesotheliomas. Tumor cells have round centrally placed nuclei, coarse chromatin, prominent nucleoli, dense cytoplasm with peripheral “halo,” and intercellular “windows.” Reactive mesothelial cells show a spectrum of changes ranging from normal to markedly atypical cells. In adenocarcinoma and poorly differentiated carcinoma, tumor cells form three-dimensional clusters with smooth edges. They have hyperchromatic nuclei, irregular nuclear membrane, prominent nucleoli, scant cytoplasm, and without intercellular “windows.” In addition, immunostains of mesothelial cell markers (calretinin, GLUT-1, D2-40, WT1, P53) and adenocarcinoma markers (TTF, Napsin A, BerEP4, B72.3, CEA, CD15) may be helpful in the differential diagnosis. Metastatic melanomas have large dispersed tumor cells with large nuclei, prominent nucleoli, and cytoplasmic melanin pigments.

**A-6. (d) Metastatic rhabdomyosarcoma**

Rhabdomyosarcoma is commonly seen in children ages one to five and in adolescents. It is also seen in adults but is rare. The most common anatomic locations for the tumor include the head, neck, and genitourinary tract. Several different histological subtypes of rhabdomyosarcoma exist, each of which has different clinical and morphological characteristics. Prognosis and clinical behavior of the tumor also partially depend on histological subtype. The most common subtypes are embryonal rhabdomyosarcoma and alveolar rhabdomyosarcoma. The cytology sample consists predominantly of dispersed cells. The tumor cells are intermediate in size and admixed with scattered large bizarre cells. Tumor cells reveal hyperchromatic nuclei, prominent nucleoli, and dense cytoplasm (indicative of muscle differentiation). MyoD1 and myogenin are positive for tumor cells.

**A-7. (d) Lymphomatous effusion most consistent with malignant lymphoma**

Monomorphic population of lymphocytes is usually seen in lymph proliferative disorders and/or lymphomas, particularly with the presence of apoptosis. It represents a monoclonal proliferation of lymphoma cells. Other cytological features of lymphoma include discohesive tumor cells with hyperchromatic nuclei, clumped (soccer-ball-like) chromatin, irregular nuclear membrane, nucleoli, and scant cytoplasm. In small cell carcinomas, tumor cells form clusters or dispersed individual cells. Nuclear crowding and molding are common. Metastatic poorly differentiated adenocarcinomas reveal clusters of large tumor cells with hyperchromatic nuclei, coarse chromatin, prominent nucleoli, and cytoplasmic vacuoles. Metastatic melanomas reveal dispersed individual large tumor cells with eccentrically located nuclei, prominent nucleoli, and cytoplasmic melanin pigment.

**A-8. (b) Metastatic small cell lung carcinoma**

In small cell carcinomas, tumor cells form two- or three-dimensional clusters or dispersed individual cells and reveal hyperchromatic nuclei, fine granular (salt-and-pepper) chromatin, and scant cytoplasm. In addition, nuclear crowding, molding, apoptotic body, and mitotic figures are common features. The background of the smear may also reveal "blue stripes" (indicative of breakdown of nuclear material). In adenocarcinomas, tumor cells form acini and/or three-dimensional clusters and reveal hyperchromatic nuclei, vesicular or coarse chromatin, prominent nucleoli, and vacuolated cytoplasm (indicative of mucin production). In lymphoma, tumor cells are

discohesive with clumped chromatin and scant cytoplasm. Lymphoglandular bodies may be identified in the background of the smear. Metastatic melanoma reveals large discohesive tumor cells with prominent nucleoli and cytoplasmic pigment.

**A-9. (b) Mesothelial cell hyperplasia**

The specimen reveals clusters of reactive mesothelial cells with psammoma bodies. Reactive mesothelial cells may show nuclear atypia; however, the normal or low N/C ratio is usually maintained. The findings of reactive atypia represent a spectrum of cellular changes that range from normal to markedly atypical. Psammoma bodies can be found in both benign and malignant conditions. Reactive mesothelial changes can be caused by a variety of conditions, such as chemotherapy and radiation therapy, inflammation, chronic irritation, and others. In mesothelioma, tumor cells form numerous three-dimensional clusters. An intercellular "window" can be seen in both reactive mesothelial cells and mesothelioma. In ovarian serous carcinomas, tumor cells form three-dimensional or papillary clusters with hyperchromatic nuclei, irregular nuclear membranes, prominent nucleoli, and coarse chromatin. In mesotheliomas, tumor cells form numerous three-dimensional clusters with hyperchromatic nuclei, irregular nuclear membranes, and coarse chromatin.

**A-10. (d) Lymphocytosis (lymphocytic effusion)**

Lymphocytosis (lymphocytic effusion) is the condition in which most of nucleated cells are lymphocytes. It is a nonspecific finding and can be caused by a variety of diseases, such as tuberculosis, infections, lymphoma, and other malignancies. In malignancy, lymphocytic effusion is caused by the obstruction of lymphatic outflow by the tumor or peritumoral lymphocytic reaction. Repeat tap and cytological evaluation may increase the chance of finding tumor cells. In lymphoma, particularly in small lymphocytic lymphoma/chronic lymphocytic leukemia, tumor cells reveal hyperchromatic nuclei with clump chromatin. Flow cytometry and immunostain of B-cell markers may help in the diagnosis. Other causes, such as status postcoronary artery bypass, may also induce a lymphocytic effusion. In benign lymphocytosis, lymphocytes reveal euchromatic nuclei with evenly distributed chromatin and inconspicuous nucleoli.

**A-11. (c) Metastatic melanoma**

In metastatic melanoma, tumor cells are usually arranged in loosely cohesive clusters or dispersed individual cells. Nuclei of tumor cells are eccentrically

located and highly variable in size with finely to coarsely granular chromatin and single prominent cherry-red nucleoli. The cytoplasm tends to be abundant and may or may not contain melanin pigment. The N/C ratio may not be high. Melanin pigment appears coarsely granular and dark brown on the Papanicolaou stain. Other characteristic features include plasmacytoid appearance, binucleation, and intranuclear inclusions. The differential diagnosis of malignant melanoma in effusion includes poorly differentiated carcinoma and sarcoma.

**A-12. (d) Mesothelioma**

The cytological findings of mesothelioma include that tumor cells form numerous three-dimensional clusters with scalloped (knobby) edges. Tumor cell has round or oval centrally placed nuclei, coarse chromatin, prominent nucleoli, dense cytoplasm with peripheral “halo,” and intercellular “windows.” Reactive mesothelial cells show a spectrum of changes ranging from normal to markedly atypical cells. In adenocarcinomas and poorly differentiated carcinomas, tumor cells form three-dimensional clusters with smooth edges. Tumor cells reveal hyperchromatic nuclei, irregular nuclear membrane, prominent nucleoli, and lacy or vacuolated cytoplasm, without intercellular “windows.” Immunostains of mesothelial cell markers (calretinin, D2-40, WT1, P53) and adenocarcinoma markers (TTF, Napsin A, BerEP4, B72.3, CEA, CD15) may be helpful in the differential diagnosis. Metastatic melanomas have dispersed tumor cells with large nuclei, prominent nucleoli, and cytoplasmic melanin pigments.

**A-13. (c) Metastatic melanoma**

The diagnosis is a metastatic melanoma. Prominent cherry-red nucleoli and intranuclear pseudoinclusions are common findings in metastatic melanomas. Nuclei of tumor cells are eccentrically located (plasmacytoid appearance) and highly variable in size with finely to coarsely granular chromatin. The cytoplasmic melanin pigment is in dark brown color on the Papanicolaou stain. Another characteristic feature is the presence of binucleated cells. The differential diagnosis of intranuclear pseudoinclusions in malignant tumors includes papillary thyroid carcinoma, breast carcinoma, lung adenocarcinoma, meningioma, and others.

**A-14. (a) Metastatic squamous cell carcinoma**

The diagnosis is metastatic squamous cell carcinoma. In fluid cytology, tumor cells of metastatic squamous cell carcinomas may be rounded up and form loose

clusters. In squamous cell carcinomas, tumor cells have enlarged nuclei, smudgy chromatin, and dense cytoplasm. In nonkeratinizing squamous cell carcinomas, prominent nucleoli may be present and can be confused with an adenocarcinoma. Squamous carcinoma cells have distinct cell borders due to the production of cytokeratin. In contrast, cytoplasm of adenocarcinoma is lacy and vacuolated.

**A-15. (b) Reactive mesothelial cells**

In reactive mesothelial cells, nuclear atypia can be quite striking; however, the normal or low N/C ratio is usually maintained in reactive atypia. The findings of reactive atypia represent a spectrum of cellular changes that range from normal to markedly atypical. Reactive mesothelial changes (reactive atypia) can be caused by a variety of conditions, such as chemotherapy and radiation therapy, inflammation, chronic irritation, and others. In mesothelioma, tumor cells form numerous three-dimensional clusters. An intercellular “window” can be seen in both reactive mesothelial cells and mesothelioma.

**A-16. (d) Metastatic signet ring cell carcinoma**

The diagnosis is metastatic signet ring cell carcinoma. The differential diagnosis of so-called “signet ring” cells in effusion cytology is broad, including both benign and malignant conditions. Benign reactive mesothelial cells may have “signet ring” cell features. A careful evaluation of the nuclear features is important for distinguishing benign from malignant lesions. Both metastatic adenocarcinomas of the lung and stomach can present “signet ring” cell morphology. The nuclear features of a carcinoma include large nuclei, hyperchromatic chromatin, irregular nuclear member, and large prominent nucleoli. The immunostains of TTF1, Napsin A, and CDX2 may help in the differential diagnosis of lung adenocarcinoma from stomach carcinoma. In a metastatic lung adenocarcinoma, TTF1 and Napsin A are usually positive, but CDX2 is negative.

**A-17. (a) Metastatic papillary renal cell carcinoma**

Papillary renal cell carcinoma is the second most common carcinoma of the renal tubules and has been characterized genetically. There are two histomorphologic types. Type 1 tumor consists of papillae and tubular structures covered by small cells with pale cytoplasm and characterized by small oval nuclei with inconspicuous nucleoli, frequent glomeruloid papillae, foamy macrophages in papillary cores, and psammoma bodies. Type 2 tumor consists of papillae covered by large cells with abundant eosinophilic cytoplasm and characterized by pseudostratification

and large spherical nuclei with prominent nucleoli and psammoma bodies, but it is uncommon to see foamy macrophages in papillary cores. Type 2 tumors are larger, more common in patients younger than age 40, and more frequent in stage 3 and 4 tumors. The reactivity of cytokeratin 7 is specific for papillary renal cell carcinomas.

A-18. **(a) Metastatic adenocarcinoma of the lung**

Metastatic adenocarcinomas of the lung may have a variety of appearances. In lung adenocarcinomas, particularly well-differentiated adenocarcinomas, tumor cells form acinar/papillary arrangements, or three-dimensional clusters. Tumor cells are intermediate or large in size and have hyperchromatic nuclei with coarse granular chromatin, prominent nucleoli, and vacuolated or clear cytoplasm. An intercellular “window” characteristic of mesothelial cells is not seen in adenocarcinomas. Small cell carcinomas have fine granular (salt-and-pepper) chromatin, nuclear crowding, and molding.

A-19. **(d) CD56**

This is a small cell lung carcinoma. CD56 is considered to be the most sensitive neuroendocrine marker for small cell lung carcinoma. Approximately 25 % of small cell lung carcinomas are negative for both synaptophysin and chromogranin A, but most of these tumors are positive for CD56. The reactivities for synaptophysin and chromogranin A are typically weak in small cell lung carcinomas. TTF1 is expressed by thyroid and pulmonary cells and is positive in approximately 70–80 % of small cell lung carcinomas. Still, 10 % of small cell lung carcinomas are negative for all three commonly used neuroendocrine markers, synaptophysin, chromogranin A, and CD56.

A-20. **(b) Neuron-specific enolase (NSE), synaptophysin, S100, and glial fibrillary acidic protein (GFAP)**

The diagnosis is a metastatic neuroblastoma. Neuroblastoma is the most common solid cancer in infancy and early childhood. Nearly half of neuroblastoma cases occur in children younger than two years. The tumor derives from primitive sympathetic neural precursors and most frequently involves the adrenal glands, neck, chest, abdomen, and pelvis. The great majority of cases are sporadic. About 1–2 % of cases run in families. N-myc oncogene amplification is a common finding in neuroblastoma. Other genetic abnormalities include activation of *HRAS*, chromosome deletion or allelic loss at 1p, aberrant expression of *TRKA* and *TRAB*, and others.

In histology sections, tumor cells typically reveal as small, round and blue cells with Homer–Wright rosettes. In fluid cytology, the specimen is cellular and consists of discohesive small cells with hyperchromatic nuclei and inconspicuous nucleoli. Necrotic debris is common. The chromatin is finely granular and has “salt-and-pepper” appearance. Rosettes may be seen on cell block preparation. A variety of immunohistochemical stains are used to distinguish neuroblastomas from other tumors, such as rhabdomyosarcomas, Ewing’s sarcoma, lymphoma, and Wilms’ tumor. Neuroblastomas are immunoreactive for neuron-specific enolase (NSE), synaptophysin, S100, and glial fibrillary acidic protein (GFAP). Cytogenetic studies may demonstrate alterations of chromosome 1.

A-21. **(c) Metastatic hepatocellular carcinoma**

In metastatic hepatocellular carcinoma, particularly a poorly differentiated tumor, numerous pleomorphic dispersed individual cells with hyperchromatic nuclei, prominent nucleoli, and dense granular cytoplasm are revealed. The identification of cytoplasmic bile pigment or lipofuscin pigment is helpful. In poorly differentiated adenocarcinoma, tumor cells have acinar arrangements with vesicular chromatin and lacy cytoplasm. In poorly differentiated squamous cell carcinomas, tumor cells have smudged nuclei and cytoplasmic keratin. In reactive mesothelial cells, cells reveal reactive atypia.

A-22. **(c) Metastatic colonic adenocarcinoma**

A metastatic colonic adenocarcinoma has characteristic cytological features, such as tall columnar “picket fence” appearance, hyperchromatic pencil-shaped nuclei, coarse chromatin, and prominent nucleoli. The presence of “dirty” necrosis can be seen in both cytospin smear and cell block sections. In breast carcinomas, tumor cells form tight three-dimensional “cannon ball” clusters. The size of tumor cells is smaller than colon adenocarcinomas; they may have intranuclear inclusions. Both reactive mesothelial cells and mesotheliomas have intercellular “windows,” and the edge of the cell cluster is knobby (scalloped appearance).

A-23. **(d) Metastatic mucinous adenocarcinoma of the lung**

Cytological features of mucinous adenocarcinomas include three-dimensional clusters and acinar and papillary groups. Tumor cells reveal large round- or oval-shaped nuclei, coarse chromatin, irregular nuclear membrane, and prominent nucleoli. The cytoplasm

of tumor cells is vacuolated (indicative of mucin production). Mucinous material can be seen in the background of cytospin smears and cell block preparation. In true papillary adenocarcinoma, numerous papillary structures could be identified. A metastatic colonic adenocarcinoma has hyperchromatic pencil-shaped nuclei and tumor necrosis. Reactive mesothelial cells reveal an intercellular “window” and reactive atypia.

**A-24. (d) Metastatic squamous cell carcinoma**

In metastatic squamous cell carcinomas, the cytological features of tumor cells include large nuclei with smudgy chromatin, nuclei with variation in size and shape, and dense cytoplasm (indicative of cyto-keratin formation). In well-differentiated tumors, cytokeratin stains orangeophilic on the Papanicolaou method. Tumor cells are usually rounded up in the fluid specimens. The formation of two- and three-dimensional tumor cell clusters is not uncommon, particularly in poorly differentiated squamous cell carcinomas. In addition, prominent nucleoli can be seen in poorly differentiated squamous cell carcinomas and should not be confused with poorly differentiated adenocarcinomas.

**A-25. (b) Primary effusion lymphoma**

Primary effusion lymphoma (PEL) is a rare HIV-associated non-Hodgkin lymphoma (NHL) that accounts for approximately 4 % of all HIV-associated NHL. In PEL, tumor cells are large and have hyperchromatic round nuclei, prominent nucleoli, and varying amounts of cytoplasm. The cells show a range of appearances, from immunoblastic (round nuclei with central prominent nucleoli) to plasmablastic (eccentric nuclei with abundant cytoplasm, sometimes containing a perinuclear clearing) to anaplastic (very large round or polygonal cells with bizarre, pleomorphic nuclei). Anaplastic forms may also contain multinucleated and/or Reed–Sternberg-like cells. Immunophenotypically, PEL cells reveal a “null” lymphocyte phenotype (i.e., CD45 is expressed), but routine B-cell (including surface and cytoplasmic immunoglobulin, CD19, CD20, CD79a) and T-cell (CD3, CD4, CD8) markers are negative.

**A-26. (d) Hodgkin lymphoma**

The cytology reveals scattered large atypical cells with binucleation and prominent nucleoli (Reed–Sternberg cells) in a background of mixed inflammatory cells, and findings are characteristic of Hodgkin lymphoma. Classic Hodgkin lymphoma is a monoclonal lymphoid neoplasm (in most instances

derived from B cells) composed of mononuclear Hodgkin and multinucleated Reed–Sternberg cells residing in an infiltrate containing a variable mixture of nonneoplastic small lymphocytes, eosinophils, neutrophils, histiocytes, and plasma cells. Large tumor cells (Reed–Sternberg cells) are positive for CD30 and CD15. In SLL/CLL, it consists of monomorphous small lymphocytes.

**A-27. (c) Reactive mesothelial cells**

The specimen consists of epithelioid cells and inflammatory cells. The epithelioid cells are reactive mesothelial cells, and some of them show signet ring cell morphology. The finding of signet ring cell morphology is not uncommon in reactive mesothelial cells. A careful evaluation of the nuclear features is important for distinguishing benign from malignant conditions. The nuclear features of a signet ring cell carcinoma include large nuclei, hyperchromatic chromatin, irregular nuclear membrane, and large prominent nucleoli. All these features are absent in benign reactive mesothelial cells with signet ring morphology.

**A-28. (b) Metastatic squamous cell carcinoma**

In metastatic squamous cell carcinomas, the cytological features of tumor cells include large nuclei with smudgy chromatin, nuclei with variation in size and shape, and dense cytoplasm (indicative of cyto-keratin formation). In well-differentiated tumors, cytokeratin stains orangeophilic on the Papanicolaou method. Tumor necrosis may be found in the smear and cell block preparation, too.

**A-29. (d) Metastatic serous carcinoma**

The diagnosis is metastatic serous carcinoma. The specimen reveals large papillary clusters of malignant cells and psammoma bodies. Psammoma bodies can be found in both benign and malignant conditions. In serous carcinomas, tumor cells form three-dimensional or papillary clusters with hyperchromatic nuclei, irregular nuclear membrane, prominent nucleoli, and coarse chromatin. Reactive mesothelial cells reveal a spectrum of reactive changes and intercellular “windows” and the presence of psammoma bodies. In colonic adenocarcinomas, tumor cell forms numerous three-dimensional clusters with hyperchromatic elongated nuclei and tumor necrosis. In squamous cell carcinomas, tumor cells are arranged in loose clusters or dispersed individual cells with variable shaped nuclei and dense cytoplasm with cyto-keratin formation. Psammoma bodies are not seen in these two types of carcinomas.

A-30. (c) **Reactive mesothelial cells**

Reactive cellular changes can happen in a variety of settings, such as radiation therapy and chemotherapy. Reactive mesothelial cells may form cohesive sheets and/or two-dimensional clusters of cells. These cells can be larger in size and have enlarged nuclei, but the normal N/C ratio is maintained. The differential diagnosis of reactive mesothelial cells includes mesotheliomas and carcinomas, particularly mesotheliomas. In mesotheliomas, tumor cells form three-dimensional clusters with knobby edges. They have hyperchromatic nuclei, irregular nuclear membranes, and prominent nucleoli.

A-31. (b) **Calretinin, TTF, and BerEP4**

The cytological preparation shows a metastatic adenocarcinoma. In pleural effusion, the most common metastatic adenocarcinoma is from the lung. In lung adenocarcinomas, tumor cells form three-dimensional clusters with smooth edges and without intercellular “windows.” They have hyperchromatic nuclei, irregular nuclear membrane, prominent nucleoli, and scant cytoplasm. The immunostains of calretinin (negative), TTF1 (positive), and BerEP4 (positive) would confirm the diagnosis of a metastatic adenocarcinoma of the lung.

A-32. (a) **Metastatic mucinous adenocarcinoma**

The diagnosis is metastatic mucinous adenocarcinoma. As seen in adenocarcinomas, tumor cells form three-dimensional clusters. They have hyperchromatic nuclei, irregular nuclear membrane, and prominent nucleoli. The striking cytological feature of mucinous adenocarcinomas is the cytoplasm vacuoles and clear cytoplasm (indicative of cytoplasmic mucin production). Reactive mesothelial cells form sheets or loose clusters; they have dense cytoplasm and intercellular “windows.” Metastatic melanomas reveal dispersed large tumor cells with prominent nucleoli and cytoplasmic melanin pigment. In metastatic small cell carcinomas, tumor cells have fine granular (salt-and-pepper) chromatin, nuclear crowding, and molding.

A-33. (c) **Reactive mesothelial cells**

The specimen consists of small clusters of cuboid cells with lumen formation and dispersed individual cells, characteristic of reactive mesothelial cells. Reactive mesothelial cell may be larger in size and have enlarged nuclei, but the normal N/C ratio is maintained. Multinucleation and prominent nucleoli may be also seen. In mesothelioma, tumor cells

form numerous large clusters with hyperchromatic nuclei, clumped chromatin, and irregular nuclear membrane. In colonic adenocarcinoma, tumor cells form three-dimensional clusters with elongated nuclei and tumor necrosis. In serous carcinomas, tumor cells have papillary arrangements, hyperchromatic nuclei, irregular nuclear membrane, prominent nucleoli, scant cytoplasm, and without intercellular “windows.”

A-34. (b) **Metastatic dysgerminoma**

The diagnosis is a metastatic dysgerminoma. Dysgerminoma of the ovary and its counterpart seminoma of the testis present as discohesive clusters and single cells that resemble enlarged mesothelial cells, although their cytoplasm is generally scant and clear. The nuclei are large and round with coarse chromatin and prominent nucleoli. The tumor cells have abundant clear cytoplasm. The background may contain numerous lymphocytes. But, the “tigroid” appearance that is so characteristic of seminomas/dysgerminoma on fine-needle aspiration specimens (owing to the abundance of glycogen from disruption of the delicate cytoplasm) is not apparent in fluid specimens. The differential diagnosis includes poorly differentiated carcinoma, melanoma, anaplastic large cell lymphoma, and epithelioid mesothelioma. The tumor cells of dysgerminoma are positive for periodic acid-Schiff (PAS) stain, placental alkaline phosphatase (PLAP), CD117, and OCT4, but usually negative for cytokeratin (CAM5.2 and/or AE1/AE3) and epithelial membrane protein (EMA).

A-35. (c) **Reactive mesothelial cells**

Reactive mesothelial cells can form cohesive sheets and/or two-dimensional clusters of cells. These cells can be larger in size and have enlarged nuclei, but the normal N/C ratio is maintained. Multinucleation and prominent nucleoli are common. Intercellular “windows” are the feature of mesothelial cells. The differential diagnosis of reactive mesothelial cells includes mesothelioma and carcinoma, particularly a well-differentiated adenocarcinoma. In adenocarcinomas, tumor cells form three-dimensional clusters with smooth edges. They have hyperchromatic nuclei, irregular nuclear membrane, prominent nucleoli, scant cytoplasm, and without intercellular “windows.” In mesothelioma, tumor cells form numerous large three-dimensional clusters.

A-36. (c) **Reactive mesothelial cells**

See answer of Q-35.

**A-37. (b) Reactive mesothelial cells**

See answer of Q-35.

**A-38. (c) Endometriosis**

The diagnosis of this pelvic washing specimen is endometriosis. Endometriosis is typically seen during the reproductive years; it has been estimated that endometriosis occurs roughly in 10 % of women. The most common location is the ovary. On a fluid specimen, benign columnar cells (endometrial glands), hemosiderin-laden macrophages, spindle cells (endometrial stroma), and debris are common findings. The specimen can be quite bloody. Older lesions may display no glands but hemosiderin deposits.

**A-39. (b) Reactive mesothelial cells**

Reactive mesothelial cells may form sheets and/or cohesive clusters of cells. These cells can be larger in size and have enlarged nuclei, but the normal N/C ratio is maintained. Multinucleation and prominent nucleoli are common. In mesotheliomas, tumor cells form numerous large three-dimensional clusters. Tumor cells have hyperchromatic nuclei, irregular nuclear membrane, prominent nucleoli, scant cytoplasm, and intercellular “windows.” In adenocarcinomas, tumor cells form three-dimensional clusters with smooth edges. They have hyperchromatic nuclei, irregular nuclear membrane, prominent nucleoli, vacuolated cytoplasm, and without intercellular “windows.”

**A-40. (a) Metastatic adenocarcinoma of the lung**

The diagnosis is a metastatic adenocarcinoma of the lung. The specimen reveals many variably sized three-dimensional clusters and scattered psammoma bodies, characteristic of lung adenocarcinoma. In adenocarcinomas, tumor cells form three-dimensional clusters with smooth edges. They have hyperchromatic nuclei, irregular nuclear membrane, prominent nucleoli, vacuolated cytoplasm, and without intercellular “windows.” In benign conditions such as mesothelial cell hyperplasia and endosalpingiosis, the presence of psammoma bodies is a common finding. In ovarian serous carcinomas, tumor cells form three-dimensional or papillary clusters with hyperchromatic nuclei, irregular nuclear membranes, prominent nucleoli, and coarse chromatin. In mesotheliomas, tumor cells form numerous three-dimensional clusters with hyperchromatic nuclei, irregular nuclear membranes, and coarse chromatin.

**A-41. (b) Reactive mesothelial cells**

Reactive mesothelial cells show a spectrum of changes, including sheets and/or cohesive clusters of cells, and they are larger in size with enlarged nuclei, but the normal N/C ratio is maintained. Multinucleation and prominent nucleoli are common. In mesotheliomas, tumor cells form numerous large three-dimensional clusters. Tumor cells have hyperchromatic nuclei, irregular nuclear membrane, prominent nucleoli, and scant cytoplasm. In adenocarcinomas and serous carcinomas, tumor cells form three-dimensional or papillary clusters with smooth edges. They have hyperchromatic nuclei, irregular nuclear membrane, prominent nucleoli, vacuolated cytoplasm, and without intercellular “windows.”

**A-42. (c) Metastatic melanoma**

The diagnosis is a metastatic melanoma. In metastatic melanomas, tumor cells are usually arranged in loosely cohesive clusters or dispersed individual cells. Nuclei of tumor cells are eccentrically located and highly variable in size with finely to coarsely granular chromatin and single prominent cherry-red nucleoli. The cytoplasm tends to be abundant and may or may not contain melanin pigment. The N/C ratio may not be high. Melanin pigment appears coarsely granular and dark brown on the Papanicolaou stain. Other characteristic features include plasmacytoid appearance, multinucleation, binucleation, and intranuclear inclusions. The differential diagnosis of malignant melanomas in effusion includes poorly differentiated carcinoma, lymphoma, and sarcoma.

**A-43. (a) Rheumatoid pleuritis**

The diagnosis is rheumatoid pleuritis. The rheumatoid pleuritis occurs in approximately 2–3 % of patients with rheumatoid arthritis. The pleural effusion can be unilateral or bilateral. Cytological features include abundant granular debris, multinucleated giant cells, and scattered lymphocytes. The presence of granular debris is characteristic of rheumatoid pleuritis. Granular debris is amorphous material and forms variable sized green- or pink-red-colored clumps by the Papanicolaou stain. It is believed that the amorphous material is different from fibrin. Diagnosis of rheumatoid pleuritis relies on the characteristic cytological findings in an exudative pleural fluid.

**A-44. (c) Reactive mesothelial cells**

The diagnosis is reactive mesothelial cells. The specimen consists of small clusters of cuboid cells

with lumen formation and dispersed individual cells characteristic of reactive mesothelial cells. Reactive mesothelial cells may be larger in size and have enlarged nuclei, but the normal N/C ratio is maintained. In mesotheliomas, tumor cells form numerous three-dimensional clusters with hyperchromatic nuclei, clumped chromatin, and irregular nuclear membrane. In adenocarcinomas, tumor cells form three-dimensional clusters with hyperchromatic nuclei, irregular nuclear membrane, prominent nucleoli, and scant cytoplasm, and without intercellular “windows.”

**A-45. (d) Metastatic squamous cell carcinoma**

The diagnosis is a metastatic squamous cell carcinoma. When a squamous cell carcinoma involves serosal surfaces and/or tumor cells shed into the fluid, tumor cells may be rounded up in the fluid and with less “squamous” features. Tumor cells of squamous cell carcinomas form loose clusters or dispersed individual cells, whereas tumor cells of adenocarcinoma form three-dimensional clusters or pseudoacinar arrangements. Tumor cells of squamous cell carcinomas have hyperchromatic nuclei, smudgy chromatin, and dense cytoplasm (indicative of cytokeratin formation). Tumor cells of adenocarcinomas have vesicular nuclei, coarse chromatin, and vacuolated cytoplasm (indicative of mucin production). The presence of prominent nucleoli can be seen in both adenocarcinomas and poorly differentiated squamous cells carcinomas.

**A-46. (d) Pseudomyxoma peritonei**

The diagnosis is pseudomyxoma peritonei. Pseudomyxoma peritonei is a condition caused by the production of abundant mucin or gelatinous material by tumor cells, which fills the abdominal cavity. The mucin or gelatinous material stains blue-green or purple color with the Papanicolaou method. This disease is most commonly caused by an appendiceal primary cancer, mucinous tumors of the ovary, and other gastrointestinal cancers. The primary tumor appears to arise from the MUC2-producing goblet cells in the appendix. The *KRAS* (P53) gene mutations have also been identified in the tumor cells. Cytological findings of pseudomyxoma peritonei include viscous, mucoid fluid that is difficult to smear (thick), free-floating columnar epithelial cells or goblet-like cells, occasional papillae, or fibrovascular cores. Since the majority of these tumors in pseudomyxoma peritonei are low-grade malignancy/borderline tumors, it is recommended to be called mucinous tumors unless there is surgical pathology confirmation of a mucinous carcinoma.

**A-47. (b) Reactive mesothelial cells**

The diagnosis is reactive mesothelial cells. Reactive mesothelial cells show a spectrum of changes, including sheets and/or cohesive clusters of cells; they are larger in size with enlarged nuclei, but the normal N/C ratio is maintained. Multinucleation and prominent nucleoli are common. In mesotheliomas, tumor cells form numerous large three-dimensional clusters. Tumor cells have hyperchromatic nuclei, irregular nuclear membrane, prominent nucleoli, and scant cytoplasm. In adenocarcinomas and serous carcinomas, tumor cells form three-dimensional or papillary clusters with smooth edges. They have hyperchromatic nuclei, irregular nuclear membrane, prominent nucleoli, vacuolated cytoplasm, and without intercellular “windows.”

**A-48. (a) Metastatic serous carcinoma**

The diagnosis is metastatic serous carcinoma. The specimen reveals clusters of atypical epithelial cells and psammoma bodies. Psammoma bodies are round collections of calcium which is covered with a thin layer of benign mesothelial cells. It stains purple in color with the Papanicolaou method. Psammoma bodies can be found in both benign and malignant conditions. In benign conditions such as mesothelial cell hyperplasia and endosalpingiosis, the presence of psammoma bodies is a common finding. In malignant conditions such as ovarian serous carcinoma and mesothelioma, numerous psammoma bodies can be identified in specimens. In ovarian serous carcinoma, tumor cells form three-dimensional or papillary clusters with hyperchromatic nuclei, irregular nuclear membrane, prominent nucleoli, and coarse chromatin. In mesothelioma, tumor cell forms numerous three-dimensional clusters with hyperchromatic nuclei, irregular nuclear membrane, and coarse chromatin. Tumor cells of squamous cell carcinomas have hyperchromatic nuclei, smudgy chromatin, and dense cytoplasm (indicative of cytokeratin formation); however, psammoma bodies are not seen in squamous cell carcinomas.

**A-49. (c) Burkitt lymphoma**

Burkitt lymphoma accounts for 30–50 % of childhood lymphoma. It is a highly aggressive B-cell lymphoma and has three main clinical variants: the endemic, the sporadic, and the immunodeficiency-associated variants. The endemic variant occurs in African and Asian children, commonly involves the jaw or other facial bone and distal ileum, and is associated with Epstein–Barr virus (EBV) infection. The sporadic variant (also known as “non-African”)

occurs in the United States and is not associated with the EBV and involves the ileocecal region. The immunodeficiency-associated Burkitt lymphoma occurs in adults and is usually associated with HIV infection or immunocompromised patients. All three variants have similar morphology. The tumor consists of intermediate-sized cells with round nuclei, coarse chromatin, multiple nucleoli, and scant cytoplasm. The cytoplasmic vacuolization is a striking feature of the tumor. Numerous tingible body macrophages, apoptosis, and mitoses can be seen. The “starry sky” appearance seen under low power is due to scattered tingible body macrophages. The tumor cells are positive for B-cell markers (CD20, CD22, CD19) as well as CD10 and BCL6, but generally negative for BCL2 and TdT. The *c-myc* gene is commonly involved (80 % of t(8;14), 15 % of t(2;8), and 5 % of t(8;22)).

#### A-50. (c) **Eosinophilic pleural effusion**

Eosinophilic pleural effusion (EPF) is defined as a nucleated cell count containing more than 10 % eosinophils in the effusion specimen. It is estimated that approximately 10 % of exudative pleural effusions are eosinophilic. The mechanism of the development of EPF is still not fully understood. One hypothesis is that stimulation of pleural mesothelial cells by injury (such as trauma, air, and blood) leads to the production of cytokines, chemokines, and adhesion molecules that induce the accumulation of eosinophils. The most common causes of EPF are pleural irritation or trauma (i.e., hemothorax, pneumothorax, thoracic surgery) and malignancy. Other causes include infections (i.e., bacteria, fungi, mycobacteria, parasites, and viruses) and certain medications. EPF also occurs idiopathic in 8–35 % of patients.

## 2.4 Answers and Discussion of Text-Based Questions 51–100

### A-51. (d) Numerous large three-dimensional cellular clusters

Mesothelial cells may undergo reactive changes in a variety of clinical settings such as with acute and chronic inflammations. The so-called “reactive” mesothelial cells can have markedly nuclear atypia, including nuclear enlargement and variation, multinucleation, and prominent nucleoli. These findings represent a spectrum of cellular changes that range from normal to atypical in reactive mesothelial cells. Variation in nuclear size, binucleation, and multinucleation can be also found in malignant mesothelial cells. Reactive cells may form two- and three-dimensional cellular clusters or sheets of cells; however, the cellular cluster usually contains less number of cells than that of mesothelioma. In contrast, in mesotheliomas, tumor cells form “large” three-dimensional clusters with more than 20–50 cells.

### A-52. (b) BerEP4, Napsin A, TTF1, Calretinin, WT1, and P53

Mesothelioma is positive for calretinin, P53, and WT1, whereas, adenocarcinoma of the lung is positive for TTF, BerEP4, CEA, B72.3, and CD15. Among the so-called adenocarcinoma markers, BerEP4 has the membrane staining pattern; Napsin A is a relative specific marker for lung adenocarcinoma with a cytoplasmic staining pattern; and TTF1 has nuclear staining pattern whereas, among mesothelioma cell markers such as calretinin, WT1, and P53, calretinin has the nuclear staining pattern and relatively high sensitivity. Cytokeratin markers, including AE1/AE3 and CK7, are positive for both epithelial and mesothelial cells. CK20 and Ki67 play no roles in the differential diagnosis of mesothelioma and adenocarcinoma. The combination of BerEP4, Napsin A, TTF1, calretinin, WT1, and P53 will provide a critical differential diagnosis for adenocarcinoma and mesothelioma.

### A-53. (b) “Window” between atypical cells

Reactive mesothelial changes (reactive atypia) can be caused by a variety of conditions, such as chemotherapy and radiation therapy, inflammation, chronic irritation, and others. In reactive mesothelial cells, nuclear atypia can be quite striking, and the normal or low N/C ratio is usually maintained in reactive atypia. These findings represent a spectrum of cellular changes that range from normal to atypical. The reactive cells may form two- or three-dimensional

small clusters or sheets of cells. The cellular arrangement may be confused with an adenocarcinoma. Variation in nuclear size, binucleation, and multinucleation can be found in both reactive mesothelial cells and adenocarcinoma. The most characteristic finding of mesothelial cells is the presence of “window” between cells.

### A-54. (d) Mesothelioma

Pleural mesothelioma is the most common form of the tumor, accounting for roughly 70 % of mesothelioma cases. An individual may be at risk to develop mesothelioma if he or she was exposed to asbestos. Pleural effusion is the common clinical presentation of mesothelioma. The cytological findings of mesothelioma include that tumor cells form numerous three-dimensional clusters with scalloped (knobby) edges. High-power view reveals that tumor cell has round centrally placed nuclei, coarse chromatin, prominent nucleoli, dense cytoplasm with peripheral “halo,” and intercellular “windows.” Reactive mesothelial cells show a spectrum of changes ranging from normal to markedly atypical cells. In adenocarcinoma and poorly differentiated carcinoma, tumor cells form three-dimensional clusters with smooth edges. They have hyperchromatic nuclei, irregular nuclear membrane, prominent nucleoli, scant cytoplasm, and without intercellular “windows.” In addition, immunostains of mesothelial cell marker (calretinin, D2-40, WT1, P53) and adenocarcinoma markers (TTF, Napsin A, BerEP4, B72.3, CEA, CD 15) should be performed to aid in the differential diagnosis.

### A-55. (d) Shared cell borders

In squamous cell carcinomas, tumor cells have enlarged nuclei, smudgy chromatin, and dense cytoplasm. In poorly differentiated squamous cell carcinoma, prominent nucleoli may be present and can be confused with an adenocarcinoma. Squamous carcinoma cells have distinct cell borders due to the production of cytokeratin; therefore, shared cell borders are not a feature of squamous cell carcinomas. It is more often seen in an adenocarcinoma.

### A-56. (d) Hyperchromatic nucleoli and clumped chromatin

Reactive mesothelial cell changes are commonly seen in patients with radiation therapy and chemotherapy. The main differential diagnosis of reactive mesothelial cells includes mesothelioma and carcinoma, particularly a well-differentiated adenocarcinoma. Reactive mesothelial cell may form cohesive

sheets and two- and three-dimensional clusters. These cells can be larger in size and have enlarged nuclei, but the normal N/C ratios are maintained. Multinucleation and prominent nucleoli are common. However, hyperchromatic nuclei, clumped chromatin, and irregular nuclear membrane are not features seen in reactive atypia. The presence of these features indicates malignant lesions. In adenocarcinomas, tumor cells form three-dimensional clusters with smooth edges. They have hyperchromatic nuclei, irregular nuclear membranes, prominent nucleoli, lacy and vacuolated cytoplasm, and without intercellular “windows.”

**A-57. (c) Monomorphic population of lymphocytes**

Monomorphic population of lymphocytes is usually seen in lymph proliferative disorders and/or lymphomas, particularly in small lymphocytic lymphomas/chronic lymphocytic leukemia (SLL/CLL). It represents a monoclonal proliferation of lymphoma cells. Other cytological features of SLL/CLL include discohesive tumor cells with hyperchromatic nuclei, clumped (soccer-ball-like) chromatin, irregular nuclear membrane, inconspicuous nucleoli, and scant cytoplasm. Polymorphous population of lymphocytes is the feature of reactive lymphoid population. The presence of lacunar space (i.e., malignant cells are situated in an empty space) on the cell block section is a feature of malignancy such as metastatic adenocarcinoma and melanoma. Lymphoglandular bodies can be seen in both reactive lymphocytes and lymphoma cases.

**A-58. (a) Adenocarcinoma with lepidic growth pattern (bronchoalveolar carcinoma)**

Adenocarcinoma with lepidic growth pattern (formerly bronchoalveolar carcinoma) is considered a well-differentiated adenocarcinoma. It can be difficult to distinguish from reactive mesothelial cells, particularly in a scant specimen. In a well-differentiated adenocarcinoma, tumor cells are arranged in two- or three-dimensional clusters. They may also form a honeycomb-like arrangement. Tumor cells are intermediate in size and have round hyperchromatic nuclei, vesicular chromatin, small nucleoli, and foamy cytoplasm. However, no “window” is identified between tumor cell clusters. Reactive mesothelial cells may form cohesive sheets and/or two-dimensional clusters. These cells can be larger in size and have enlarged nuclei, but the normal N/C ratios are maintained. Multinucleation and prominent nucleoli are common. Hyperchromatic nuclei, clumped chromatin, and irregular nuclear membrane are not

features seen in reactive mesothelial cells. In a poorly differentiated squamous cell carcinoma, tumor cells have smudgy chromatin and dense cytoplasm with or without cytokeratin formation. In basaloid carcinoma and small cell carcinoma, tumor cells are relatively small in size with hyperchromatic nuclei, nuclear molding and crowding, and scant cytoplasm.

**A-59. (b) Renal transplantation**

Pleural fluid eosinophilia, also called eosinophilic pleural effusion (EPF), is defined as a nucleated cell count containing more than 10 % eosinophils in the effusion specimen. It is estimated that approximately 10 % of exudative pleural effusions are eosinophilic. The mechanism of the development of EPF is still not fully understood. One hypothesis is that stimulation of pleural mesothelial cells by injury (such as trauma, air, and blood) leads to the production of cytokines, chemokines, and adhesion molecules that induce the accumulation of eosinophils. The most common causes of EPF are pleural irritation or trauma (i.e., hemothorax, pneumothorax, thoracic surgery) and malignancy. Other causes include infections (i.e., bacteria, fungi, mycobacteria, parasites, and viruses) and certain medications. EPF also occurs idiopathic in 8–35 % of patients. Although it was common decades ago, the development of EPF in the setting of tuberculosis is now considered rare. Renal transplantation has no direct connection to EPF.

**A-60. (a) True**

The sensitivity of fluid cytology for detecting malignancy is approximately 60–70 %, whereas the sensitivity of “blind” biopsy is less than 50 %. The reason fluid cytology has a higher sensitivity is that it may provide more diagnostic cells. The sensitivity of fluid cytology and the detection rate of malignancy may be further increased when multiple specimens are examined from a clinically suspicious patient.

**A-61. (c) Air in the pleural space (pneumothorax)**

Common causes of EPF are pleural irritation or trauma (i.e., hemothorax, pneumothorax, thoracic surgery), malignancy, infections (i.e., bacteria, fungi, mycobacteria, parasites, and viruses), and certain medications. The reported frequency of pleural malignancy in patients with EPF ranges from 6 to 40 %. Among the malignancies associated with EPF, lung cancer is the most common one. EPF also occurs idiopathic in 8–35 % of patients. In many case studies, pneumothorax, particularly the spontaneous

pneumothorax, is the most common cause of EPF and accounts for more than 50 % of cases.

**A-62. (b) Air in the pleural space (pneumothorax)**

Pneumothorax, particularly the spontaneous pneumothorax, is the most common cause of EPF. An intense eosinophilic pleuritis occurs within hours after air entry into the pleural space. In contrast to the rapid development of EPF after spontaneous pneumothorax, hemothorax-induced EPF appears typically by the tenth day, with the development of a peripheral blood eosinophilia days later. Pleural space hemorrhage may contribute to the development of PFE in the setting of thoracic surgery, thoracotomy, chest trauma, benign asbestos pleural effusion, and pulmonary infarction. The thoracic surgery and biopsy may also result in EPF which typically occurs within 30 days after the procedure, particularly when the pleura has been excised, such as internal mammary grafting. Repeated thoracentesis has been suggested as a cause of EPF; it develops within days but not in hours after the procedure.

**A-63. (d) Cirrhosis**

The most common cause of eosinophilic ascites is cirrhosis. Other causes of eosinophilic effusion include peritoneal irritation or trauma, malignancy, infections (i.e., bacteria, fungi, mycobacteria, parasites, and viruses), and idiopathic. A rare cause of development of eosinophilic ascites is eosinophilic gastroenteritis, which has been increasingly reported recently. It should be included in the differential diagnosis of eosinophilic ascites.

**A-64. (d) Prominent nucleoli**

When squamous cell carcinoma involves serosal surfaces and/or tumor cells shed into the fluid, the distinction of squamous cell carcinoma and adenocarcinoma can be difficult in some cases, since tumor cells may be rounded up in the fluid and with less "squamous" features. Tumor cells of squamous cell carcinoma form loosely clusters or dispersed individual cells, whereas tumor cells of adenocarcinoma form three-dimensional clusters or pseudoacinar arrangements. In general, tumor cells of squamous cell carcinoma have hyperchromatic nuclei, smudgy chromatin, and dense cytoplasm (indicative of cyto-keratin formation). Tumor cells of adenocarcinoma have vesicular nuclei, coarse chromatin, and vacuolated cytoplasm (indicative of mucin production). The presence of prominent nucleoli can be seen in both adenocarcinoma and poorly differentiated squamous cells carcinoma.

**A-65. (d) All of the above**

The differential diagnosis of so-called "signet ring" cells in effusion cytology is broad, including both benign and malignant conditions. In benign reactive mesothelial cells, they can have "signet ring" cell features. Both metastatic adenocarcinomas of the lung and stomach can present "signet ring" cell morphology. A careful evaluation of the nuclear features is important for distinguishing benign from malignant lesions. The nuclear features of a carcinoma include large nuclei, hyperchromatic chromatin, irregular nuclear member, and large prominent nucleoli. The immunostains of TTF1, Napsin A, and CDX2 may help in the differential diagnosis of lung adenocarcinoma from stomach carcinoma. In a metastatic lung adenocarcinoma, TTF1 and Napsin A are usually positive, but CDX2 is negative. However, in cases of metastatic mucinous adenocarcinoma of the lung, stains of TTF and CDX2 may not help, since the TTF may be negative and CDX2 may be focally positive in the mucinous adenocarcinoma.

**A-66. (d) Nuclear grooves**

Neuroendocrine tumors (NET) are a spectrum of neoplasms, arising from various neuroendocrine cells. NETs are most often located in the intestine and the lungs. Although NETs have different embryological origin, they have common phenotypic characteristics. For example, tumors show immunoreactivity for neuroendocrine markers, including chromogranin, synaptophysin, CD56, and neuron-specific enolase (NES) and may secrete various peptides and hormones. Cytological features of NET are characterized by fine granular chromatin (salt-and-pepper chromatin) pattern, inconspicuous nucleoli, and scant cytoplasm. Mitosis may be rare or abundant depending on the differentiation of the tumor. Nuclear crowding and molding are often seen in small cell carcinoma; however, nuclear groove is not a feature of neuroendocrine tumors. The World Health Organization (WHO) classifies neuroendocrine tumors into three main categories: (1) well-differentiated neuroendocrine tumors with benign behavior, (2) well-differentiated (low-grade) neuroendocrine carcinomas with low-grade malignant behavior, and (3) poorly differentiated (high-grade) neuroendocrine carcinomas with aggressive clinical course, such as the large cell neuroendocrine and small cell carcinomas. In addition, cellular proliferative rate (Ki67 labeling) has been considered as a useful marker for the classification of the tumor.

**A-67. (c) Acid (simple, mesenchymal)**

Mucin can be produced by both epithelial cells and stroma. Neutral mucin can be found in glands of the GI tract and in the prostate, and they stain with PAS but not with alcian blue, colloidal iron, mucicarmine, or metachromatic dyes. There are several types of acid mucins. Acid mucin (simple or non-sulfated) is the typical mucin of epithelial cells containing sialic acid, and they stain with PAS, alcian blue at pH 2.5, colloidal iron, and metachromatic dyes. They resist hyaluronidase digestion. Acid mucin (simple, mesenchymal) contains hyaluronic acid and does not stain with PAS, but does stain with alcian blue at pH 2.5, colloidal iron, and metachromatic dyes. They digest with hyaluronic acid and can be found in sarcomas and mesotheliomas. Acid mucin (complex, or sulfated, epithelial) is found in adenocarcinomas; PAS is usually positive; alcian blue is positive at pH 1, and colloidal iron, mucicarmine, and metachromatic stains are also positive. They resist the digestion with hyaluronidase. Finally, acid mucin (complex, connective tissue) are found in stromal tissue such as cartilage and bone, and they are PAS negative but do stain selectively with alcian blue at pH 0.5.

**A-68. (d) Mucicarmine**

There are a variety of mucin stains. In the colloidal iron stain, iron particles are stabilized in ammonia and glycerin and are attracted to acid mucopolysaccharides. It requires formalin fixation. Phospholipids and free nucleic acids may also stain. The actual blue color comes from a Prussian blue reaction. The tissue can be predigested with hyaluronidase to provide more specificity. In alcian blue stain, the pH of the stain can be adjusted to improve the specificity. In PAS stain, both glycogen and mucins are stained, but the tissue can be predigested with diastase to remove glycogen. In mucicarmine stain, epithelial mucins are stained. It is the most specific mucin stain for adenocarcinoma, but its sensitivity is low. The most sensitive mucin stain is PAS, but its specificity is poor. Colloidal iron stains are unpredictable. Alcian blue stains are simple, but have a lot of background staining.

**A-69. (d) Poorly differentiated adenocarcinoma**

The differential diagnosis of spindle cells in fluid cytology is broad, including spindle cell carcinoma, sarcomatoid mesothelioma, melanoma, and all other tumors with spindle cell morphology. Therefore, careful review of the patient's malignant history is extremely important, and it may help to narrow

down the differential diagnosis. The spindle cell appearance is not the feature of a poorly differentiated adenocarcinoma. The cytological features of a poorly differentiated adenocarcinoma include three-dimensional clusters, acinar and papillary groups, or honeycomb-like sheets of epithelial cells. Tumor cells have large round- or oval-shaped hyperchromatic nuclei, coarse chromatin, irregular nuclear membrane, and prominent nucleoli. The cytoplasm of tumor cells is feathery and foamy. Cytoplasmic vacuolization (indicative of mucin production) can be seen.

**A-70. (c) Abundant cytoplasm**

In small cell carcinomas, tumor cells are relatively small, and they are two- to threefold in size of mature lymphocytes; however, in small cell carcinoma large cell variant, the size of tumor cells can be much larger. Tumor cells show scant cytoplasm and high N/C ratio, large nuclei with fine chromatin (salt-and-pepper) pattern, nuclear crowding and molding, and paranuclear blue bodies in the cytoplasm. The nucleoli are inconspicuous in small cell carcinomas. Abundant cytoplasm is not a feature seen in small cell carcinoma. It can be seen in carcinoid and large cell neuroendocrine tumor.

**A-71. (a) Fine granular (salt-and-pepper) chromatin pattern**

The World Health Organization (WHO) classification recognizes four major types of lung neuroendocrine tumors: typical carcinoid, atypical carcinoid, small cell lung cancer (SCLC), and large cell neuroendocrine carcinoma (LCNEC). The classification is based on morphology, mitotic rate, and the absence or presence of necrosis. Ki-67 (MIB1) labeling is also play an important role in the diagnosis and classification of these tumors. In histological section, the characteristics of LCNEC include three features: high-grade nuclei, neuroendocrine morphology, and positive neuroendocrine IHC markers. In cytological preparations, LCNEC typically reveals as dispersed individual cells or loosely formed clusters. The size of cells is usually larger than those of SCLC. Tumor cell has prominent nucleoli, fine rather than coarse granular chromatin (seen in adenocarcinoma), and more markedly cytological pleomorphism, whereas the reactivities for synaptophysin and chromogranin may be weak in small cell lung carcinoma. Tumor cells have coarse granular rather than fine chromatin and lacy or vacuolated cytoplasm. In difficult cases, diagnosis of LCNEC versus a poorly differentiated adenocarcinoma depends on IHC staining of

neuroendocrine markers. Although LCNEC are positive for neuroendocrine markers, 10–20 % of non-small cell lung cancers label for neuroendocrine markers. Therefore, the differential diagnosis of these two tumors should be based on the combination of cytomorphology and IHC study.

A-72. **(b) Make cell block as usual**

Making a cell block preparation is important in fluid cytology, particularly in cases with atypical epithelial cells and/or suspicious metastatic carcinomas. In such cases, IHC study is usually helpful in the differential diagnosis. Repeat tap and biopsy of the lung lesion are not necessary. The main differential diagnosis is reactive mesothelial cells versus adenocarcinoma. Reactive mesothelial cells show a spectrum of changes ranging from normal to markedly atypical cells. In adenocarcinomas, tumor cells form three-dimensional clusters with smooth edges. They have hyperchromatic nuclei, irregular nuclear membrane, prominent nucleoli, scant cytoplasm, and without intercellular “windows.” In addition, immunostains of mesothelial cell marker (calretinin, D2-40) and adenocarcinoma markers (TTF, Napsin A, BerEP4, B72.3, CEA, CD15) may help in the differential diagnosis.

A-73. **(d) All of the above**

Primary effusion lymphoma (PEL) is a rare HIV-associated non-Hodgkin lymphoma (NHL) that accounts for approximately 4 % of all HIV-associated NHL. PEL has a unique clinical predilection for arising in body cavities such as the pleural space, pericardium, and peritoneum. There is an evidence of human herpesvirus (HHV)-8 infection in patients. The exact oncogenic mechanisms of HHV-8 have not been clearly defined. Treatment is usually with combination CHOP (cyclophosphamide, doxorubicin, vincristine, and prednisone) chemotherapy and antiretroviral therapy (if HIV positive). The prognosis for PEL is poor, with a median survival time of around 6 months. The diagnosis of PEL requires cytomorphological analysis of effusion specimen, immunophenotypic and molecular tests, and virologic criteria (i.e., previously infection with HHV-8). The diagnosis is usually made on a cytological preparation (e.g., liquid-based preparation, cytospin, cell block) of the effusion fluid. Morphologically, tumor cells are large and have round to irregular nuclei, prominent nucleoli, and varying amounts of cytoplasm. The cells show a range of appearances, from immunoblastic (round nuclei with central prominent nucleoli) to plasmablastic

(eccentric nuclei with abundant cytoplasm, sometimes containing a perinuclear clearing) to anaplastic (very large round or polygonal cells with bizarre, pleomorphic nuclei). Anaplastic forms may also contain multinucleated and/or Reed–Sternberg-like cells. Immunophenotypically, PEL cells reveal a “null” lymphocyte phenotype (i.e., CD45 is expressed), but routine B-cell (including surface and cytoplasmic immunoglobulin, CD19, CD20, CD79a) and T-cell (CD3, CD4, CD8) markers are negative. Instead, various markers of lymphocyte activation (CD30, CD38, CD71, human leukocyte antigen DR) and plasma cell differentiation (CD138) are usually displayed. Molecular studies have provided evidence that immunoglobulin gene rearrangements and somatic mutation have occurred in PEL cells. Cytogenetic analysis has revealed complex karyotypes but no common chromosomal abnormality in PEL.

A-74. **(d) Hepatocellular carcinoma**

“Intranuclear inclusions” have been described in a variety of malignant tumors, such as papillary thyroid carcinoma, lung adenocarcinoma, meningioma, hepatocellular carcinoma, and others. It has not been found in renal cell carcinomas. The cytological features of renal cell carcinomas (clear cell renal cell carcinomas) include loosely cohesive clusters and/or scattered individual tumor cells. They have slightly enlarged round nuclei with or without nucleoli depending on the Fuhrman grade of the tumor. The background of smears can be bloody with vascular structures, best seen on cell block preparations. Tumor cells also have abundant vesicular cytoplasm and cytoplasmic vacuoles. The N/C ratio is usually in normal range.

A-75. **(c) Prepare cell blocks and make sure that it have adequate tumor cells**

Currently *EGFR*, *KRAS*, and other mutations are routinely tested in non-small cell lung cancer patients. Any type of formalin-fixed and paraffin-embedded specimen, including cell block preparations, can be used for these molecular and mutational analyses. For any type of specimens, the presence of adequate tumor cells is crucial and necessary to be confirmed prior to sending the specimen for molecular tests. In lung adenocarcinoma, the *EGFR* and *KRAS* mutational rates are 10–15 and 15–20 % in the United States. *EGFR* mutation is associated with a good response to tyrosine kinase inhibitors therapy, whereas *KRAS* mutation is associated with a resistance to tyrosine kinase inhibitor therapy in lung cancer patients. It is not necessary to obtain tissue

from primary tumor; molecular studies can be performed using tissue from a metastatic tumor.

**A-76. (d) All of the above**

Psammoma body can be found in both benign and malignant conditions. In benign conditions such as mesothelial cell hyperplasia and endosalpingiosis, the presence of psammoma body is a common finding. In malignant conditions such as ovarian serous carcinoma and mesothelioma, numerous psammoma bodies can be identified in ascites specimens.

**A-77. (c) Pyknotic nuclei**

In a fluid specimen, tumor cells of metastatic squamous cell carcinoma are usually rounded up and form loosely clusters. The cytological features of tumor cells include large nuclei with smudgy chromatin, nuclei with variation in size and shape, and dense cytoplasm (indicative of cytokeratin formation), except the feature of pyknotic nuclei. Pyknotic nuclei are usually seen reactive and/or benign squamous cells. Finally, prominent nucleoli can be seen in poorly differentiated squamous cell carcinomas and should not be confused with poorly differentiated adenocarcinomas. Tumor cells of adenocarcinoma have vesicular nuclei, coarse chromatin, and vacuolated cytoplasm.

**A-78. (a) Burkitt's or Burkitt's-like lymphoma (BL)**

The most common histological types of AIDS-related non-Hodgkin lymphoma (ARL) include Burkitt's or Burkitt's-like lymphoma (BL), diffuse large B-cell lymphoma (DLBCL) (including the subtypes immunoblastic (including most cases of PCNSL) and centroblastic lymphoma), plasmablastic lymphoma (including oral cavity involved and multicentric Castleman's disease [MCD] associated), and primary effusion lymphoma (PEL). Among them, BL rarely presents as a lymphomatous effusion. BL tumor cells are positive for the characteristic c-myc gene rearrangement and show no evidence of HHV-8 infection. Peripheral T-cell NHLs presenting with an effusion can usually be distinguished by routine immunohistochemistry for T-cell markers or T-cell receptor (TCR) gene rearrangement studies. Because of similar morphology, T-cell anaplastic large cell lymphoma may also be confused for PEL in some cases; immunohistochemical staining for anaplastic lymphoma kinase in addition to the TCR gene rearrangement studies may be helpful in these cases. Both DLBCL and PEL can have similar cytomorphology. In DLBCL, tumor cells are positive for Epstein-Barr virus, but

negative for HHV-8. In PEL, tumor cells are negative for Epstein-Barr virus, but positive for HHV-8.

**A-79. (c) Colon**

A metastatic colonic adenocarcinoma has these classic cytological features. Tumor cells showed tall columnar "picket fence" appearance, hyperchromatic pencil-shaped nuclei, coarse chromatin, and prominent nucleoli. The presence of "dirty" necrosis is usually not as apparent as seen in histological sections. In breast carcinomas, tumor cells form tight three-dimensional "cannon ball" clusters. The size of tumor cells is smaller than that of colon adenocarcinomas; they may have intranuclear inclusion. Renal cell carcinomas usually reveal a centrally located nuclei and clear cytoplasm. Lung adenocarcinomas may have a variety of morphological features. The finding of tall columnar cells favors a colonic primary rather than the lung primary; IHC stain of TTF, Napsin A, CK7, CK20, and CDX2 may aid to the differential diagnosis in difficult cases.

**A-80. (a) Prominent nucleoli**

The presence of prominent nucleoli is not the feature seen in small cell carcinomas. All other features can be seen in both adenocarcinoma and small cell carcinoma. In adenocarcinomas, tumor cells form acini and/or three-dimensional clusters and reveal hyperchromatic nuclei, vesicular or coarse chromatin, prominent nucleoli, and vacuolated cytoplasm (indicative of mucin production). All neuroendocrine tumors share many cytological features, such as fine granular (salt-and-pepper) chromatin and acini/rosette arrangements of tumor cells. In addition, in small cell carcinomas, nuclear crowding and molding are common features. Tumor necrosis can be seen in both adenocarcinoma and small cells carcinoma.

**A-81. (b) Making cell block to perform IHC markers S100, HMB45, and melanin A**

Metastatic melanoma to serosal cavities, including pleural, pericardial, and peritoneal cavities, is not uncommon. Tumor cells are usually rounded up in a fluid specimen and may or may not produce melanin pigment, particularly in desmoplastic/spindle cell melanoma (no pigment production). The cytological features of a metastatic melanoma include individual large cells with prominent nucleoli, intranuclear inclusion, cytoplasmic pigment, binucleation, and the presence of plasmacytoid cells. In desmoplastic/spindle cell melanoma, tumor cells reveal bizarre nuclei and prominent nucleoli. Immunomarkers S100, HMB45, and MelanA/Mart1 are helpful in the

differential diagnosis. S100 stains nuclei and cytoplasm with 90 % sensitivity but not specific. HMB45 stains cytoplasm; it is more specific but less sensitive than S100; only 20 % of desmoplastic/spindle cell melanomas are immunoreactive with HMB45. MelanA/Mart1 stains cytoplasm, and is a sensitive marker, but it also stains steroid-producing cells in the ovary, testis, and adrenal cortex; it is also negative in desmoplastic/spindle cell melanoma. Although unstained cytopsin slides can be used for IHC study, cell block preparation provides better results. The combination of S100, HMB45 and melanin A may result in the best immunopattern in the differential diagnosis of melanomas.

**A-82. (d) Naked nuclei**

The presence of naked nuclei is not the feature seen in metastatic breast carcinoma. In pleural effusion cytology, tumor cells of metastatic breast carcinoma form tight three-dimensional “cannon ball” clusters. The size of tumor cells is relatively smaller than that of metastatic adenocarcinoma from the lung and/or GI tract. The presence of intracytoplasmic lumina, so-called magenta body, is also one of the characteristics of metastatic breast carcinoma. Magenta bodies are variably sized red-to-purple perinuclear inclusions seen by the Diff-Quik stains. The prominent nucleoli are a common cytological feature seen in a variety of adenocarcinomas. Naked nuclei can be seen in metastatic melanoma and hepatocellular carcinoma.

**A-83. (c) Hyaluronic acid–alcian blue**

Both mesothelioma and adenocarcinoma produce mucins. In adenocarcinomas, tumor cells are positive for mucicarmine, PAS, and cytokeratin. Similarly, in mesotheliomas, particularly in epithelial mesotheliomas, tumor cells may also be positive for mucicarmine, PAS, and cytokeratin. Studies have shown that mucicarmine and PAS stains were usually eradicated or reduced in intensity by pretreatment of the tissue sections with hyaluronidase, suggesting that hyaluronic acid was responsible for the positive mucin reactions in mesothelioma. Therefore, hyaluronic acid–alcian blue stain is a characteristic feature of a mesothelioma rather than an adenocarcinoma. In alcian blue stain, the pH of the stain can be adjusted to improve the specificity.

**A-84. (d) Bipolar nuclei**

The presence of bipolar nuclei is not the feature seen in metastatic breast carcinoma. In pleural effusion

cytology, tumor cells of metastatic breast carcinoma form tight three-dimensional “cannon ball” clusters. The size of tumor cells is relatively smaller than that of metastatic adenocarcinoma from the lung and/or GI tract. The presence of intracytoplasmic lumina (magenta body) is also one of the characteristics of metastatic breast carcinoma.

**A-85. (a) Hyperchromatic nuclei and prominent nucleoli**

The presence of prominent nucleoli is not the feature seen in small cell carcinomas. All other features can be seen in small cell carcinoma. In small cell carcinomas, tumor cells form three-dimensional clusters or dispersed individual cells and reveal hyperchromatic nuclei, fine granular (salt-and-pepper) chromatin, and scant cytoplasm. In addition, nuclear crowding, molding, apoptotic body, and mitotic figures are common features. The background of the smear may also reveal “blue strips” (indicative of breakdown nuclear material). In adenocarcinomas, tumor cells form acini and/or three-dimensional clusters and reveal hyperchromatic nuclei, vesicular or coarse chromatin, prominent nucleoli, and vacuolated cytoplasm (indicative of mucin production).

**A-86. (d) All of the above**

Lymphocytic effusion is the effusion in which almost all nucleated cells are lymphocytes. In the cytological preparation, it reveals small lymphocytes. In tuberculosis, the identification of eosinophils is important; it may be suggestive of the diagnosis. The diagnosis of tuberculosis can be confirmed by microbiology culture or pleural biopsy. Malignancy is the common cause of lymphocytic effusion. It may be caused by the obstruction of lymphatic outflow by the tumor or peritumoral lymphocytic reaction. Repeat tap and cytological evaluation may increase the chance of finding tumor cells. Small lymphocytic lymphoma/chronic lymphocytic leukemia may cause lymphocytic effusion, particularly in a patient with peripheral lymphocytosis. Flow cytometry and immunostain of B-cell markers may help in the diagnosis. Other causes, such as status for post coronary artery bypass may also induce a lymphocytic effusion.

**A-87. (d) CD56**

CD56 is considered to be the most sensitive neuroendocrine marker for small cell lung carcinoma, whereas the reactivities for synaptophysin and chromogranin A are typically weak in small cell lung carcinoma. Approximately 25 % of small cell lung

carcinomas are negative for both synaptophysin and chromogranin A, but most of these tumors are positive for CD56. Still, 10 % of small cell lung carcinomas are negative for all three commonly used neuroendocrine markers. The frequency of neuroendocrine marker negativity in small cell lung carcinoma is even higher in small biopsy and cytology specimens, in which focal reactivity may not be represented on the smear due to the nature of the specimen and the heterogeneity of the tumor. If the cytomorphology is classic for small cell carcinomas, the lack of supporting immunohistochemical stains should not serve as evidence against the diagnosis. TTF1 is positive for both small cell lung carcinoma and lung adenocarcinomas.

**A-88. (b) False**

TTF1 (thyroid transcription factor 1) is expressed by thyroid and pulmonary cells and is positive in approximately 70–80 % of small cell lung carcinomas. TTF1 is usually used to identify the pulmonary (and/or thyroid) origin of metastatic adenocarcinomas. In contrast to adenocarcinomas, TTF1 in small cell carcinomas cannot be used to distinguish the origin of the tumor, i.e., pulmonary versus extrapulmonary origin. In addition to lung small cell carcinomas, the expression of TTF1 has been found to occur in 20–80 % of small cell carcinomas of various sites, including the prostate, bladder, cervix, and gastrointestinal tract.

**A-89. (b) Small cell lung carcinoma**

Both adenocarcinomas and small cell carcinomas are cytokeratin positive. The weak punctate (“dotlike”) labeling pattern for cytokeratins, including both AE1/AE3 and CAM 5.2, is the feature commonly seen in small cell lung carcinomas. In contrast, a strong circumferential labeling of tumor cells is characteristic of a non-small cell lung carcinoma, particularly an adenocarcinoma. However, this feature may be seen in other high-grade carcinomas. Although all resected small cell carcinomas are cytokeratin positive, some tumors may show weak and minimal reactivity. Thus, on small biopsy and/or cytology specimens, a subset of small cell carcinomas may appear cytokeratin negative. In the absence of confirmatory markers, it is important to exclude the possibility of lymphoma, basaloid squamous cell carcinoma, and other small round blue cell tumors. If the cytomorphology is classic for small cell carcinomas, the lack of supporting immunohistochemical stains should not serve as evidence against the diagnosis.

**A-90. (d) Immunostains of synaptophysin, chromogranin, CD56, and CD45**

An important differential diagnosis of small cell lung carcinoma is lymphoma. In small cell carcinomas, tumor cells form three-dimensional clusters or dispersed individual cells and reveal hyperchromatic nuclei, fine granular (salt-and-pepper) chromatin, and scant cytoplasm. In addition, nuclear crowding, molding, apoptotic body, and mitotic figures are common features. The background of the smear may also reveal “blue strips” (indicative of breakdown of nuclear material). Positive immunostains of synaptophysin, chromogranin and CD56, and negative stain of CD45 may confirm the diagnosis. In lymphomas, tumor cells are discohesive and dispersed throughout the smear. The finding of a “lymphoglandular body” is characteristic of lymphoma. The chromatin of lymphoma cells are coarse granular, and they may have prominent nucleoli. Flow cytometry and immunostain of lymphoma markers may help in the diagnosis. Immunomarkers of AE1/AE3, TTF, and BerEP4 are best used for carcinomas, particularly adenocarcinoma. CD20 and CD5 may stain background lymphocytes in the smear of a small cell carcinoma.

**A-91. (b) Irregular nuclear membrane and hyperchromasia**

Reactive cellular changes can happen in a variety of settings, such as radiation and chemotherapy. Reactive mesothelial cell may form cohesive sheets and/or two-dimensional clusters of cells. These cells can be larger in size and have enlarged nuclei, but the normal N/C ratio is maintained. Multinucleation and prominent nucleoli are common. Intercellular “windows” are a feature of mesothelial cells. However, hyperchromatic nuclei, clumped chromatin, and irregular nuclear membranes are not features seen in reactive atypia. The presence of these features indicates malignant lesions. The differential diagnosis of reactive mesothelial cells includes mesothelioma and carcinoma, particularly a well-differentiated adenocarcinoma. In adenocarcinomas, tumor cells form three-dimensional clusters with smooth edges. They have hyperchromatic nuclei, irregular nuclear membranes, prominent nucleoli, scant cytoplasm, and without intercellular “windows.”

**A-92. (b) CT-guided transthoracic needle biopsy**

The most common primary malignant lesions involving the pleural cavity are mesotheliomas and lymphomas. Malignant pleural effusion is a condition in which cancer causes an abnormal accumulation

of fluid between the thin layers of pleura lining the outside of the lung and the wall of the chest cavity. Lung cancer and breast cancer account for about 50–65 % of malignant pleural effusions. Among these procedures, blind transthoracic needle biopsy has the sensitivity of less than 50 %; thoracentesis cytology has a sensitivity of 60 %; ultrasound-guided transthoracic needle biopsy has a sensitivity of 73 %; and a CT-guided transthoracic needle biopsy has a sensitivity of 87 %.

A-93. **(d) Ultrasound-guided thoracentesis**

The ultrasound-guided thoracentesis has a specificity of 100 % for distinguishing malignant pleural effusions from other causes of pleural effusion, based on the presence of visible pleural lesions (i.e., metastases), pleural thickening greater than 1 cm, pleural nodularity, diaphragmatic thickening greater than 7 mm, and an echogenic swirling pattern visible in the pleural fluid.

A-94. **(b) False**

Cytological features of adenocarcinomas include three-dimensional clusters, acinar and papillary groups, or honeycomb-like sheets of tumor cells. Tumor cells reveal large round- or oval-shaped nuclei, coarse chromatin, irregular nuclear membrane, and prominent nucleoli. The cytoplasm of tumor cells is feathery and foamy (indicative of mucin production). Squamous cell carcinomas account for 30–40 % of non-small cell lung cancers. In metastatic squamous cell carcinomas, the cytological features of tumor cells include large nuclei with smudgy chromatin, nuclei with variation in size and shape, and dense cytoplasm (indicative of cyto-keratin formation). Tumor cells are usually rounded up in the fluid specimens. The formation of two- and three-dimensional tumor cell clusters is not uncommon, particularly in poorly differentiated squamous cell carcinomas. In addition, prominent nucleoli can be seen in poorly differentiated squamous cell carcinomas and should not be confused with poorly differentiated adenocarcinomas.

A-95. **(d) All of the above**

The rheumatoid pleuritis may occur in approximately 2–3 % of patients with rheumatoid arthritis. The pleural effusion can be unilateral or bilateral. Cytological features include abundant granular debris, multinucleated giant cells, and scattered lymphocytes. The presence of granular debris is characteristic of the rheumatoid pleuritis. Granular debris are amorphous material and form variable

sized green- or pink-red-colored clumps by the Papanicolaou stain. It is believed that the amorphous material is different from fibrin. Diagnosis of rheumatoid pleuritis relies on the characteristic cytological findings in an exudative pleural fluid.

A-96. **(c) Mesothelial cells**

The diagnosis features of a rheumatoid pleuritis rely on the characteristic cytological findings of the exudative pleural fluid, which contains elongated and giant multinucleated histiocytes in a sea of amorphous granular material. The absence of mesothelial cells is also characteristic of the disease.

A-97. **(d) All of the above**

Charcot–Leyden crystal is a needle-shaped crystal. They vary in size and may be as large as 50  $\mu\text{m}$  in length. They consist of lysophospholipase, an enzyme synthesized by eosinophils, and are produced from the breakdown of these cells. It was first described by Friedrich Albert von Zenker in 1851. The finding of Charcot–Leyden crystals in pathology specimen is indicative of a disease involving eosinophilic inflammation or proliferation, such as in allergic reactions, parasitic infections, and eosinophilic effusions.

A-98. **(d) LE cells contain nuclear material with visible chromatin structures, such as coarse chromatin granules**

The lupus pleuritis may occur in one third of lupus patients. The finding of LE cells in the fluid cytological preparations is characteristic and can be identified in the majority of cases. The LE cell was discovered in bone marrow by Hargraves et al. in 1948. The LE cell is a neutrophil or macrophage that has phagocytized (engulfed) the denatured nuclear material (hematoxylin body) of another cell. Denatured nuclear material in the neutrophil/macrophage has a glassy and homogeneous appearance; it may push the nuclei to the peripheral location. The hematoxylin body may be green, blue, or purple in color with the Papanicolaou stain and magenta color with the Diff-Quik stains. Cells contain nuclear material with visible chromatin structures (i.e., coarse chromatin pattern) are the so-called Tart cells; they are not LE cells.

A-99. **(d) All of the above**

In effusion as well as ascites and pericardial effusion, the presence of a second population of cells, numerous large clusters of cells, and lacunae spaces on cell block preparation is characteristic of a malignant

effusion. The cellularity in a malignant effusion may be markedly increased. Numerous tumor cell clusters are seen in the specimen. In addition to mesothelial cells, metastatic tumor cells represent a second cellular component in the fluid specimen. Lacuna is the empty space surrounding the tumor cell cluster on the cell block preparation. It has been reported that lacunae have been identified in 75 % of malignant effusions, particularly in adenocarcinomas.

**A-100. (b) False**

Lacuna is the empty space surrounding the tumor cell cluster on the cell block preparation. It is an artifact and has been found in 75 % of malignant effusions. The finding of lacunae at low magnification is helpful for identifying suspicious cells. Although it is a common finding in a malignant effusion, lacunae can also be seen in benign conditions. Therefore, evaluation of cells at high magnification is necessary to confirm the diagnosis of a malignant effusion.

## Reading List

- Abadi MA, Zakowski MF. Cytologic features of sarcoma in fluids. *Cancer Cytopathol.* 1998;84:71–6.
- Bibbo M, Wood MD, Fitzpatrick BT. Peritoneal washings and ovary. In: Bibbo M, Wilbur D, editors. *Comprehensive cytopathology*. 3rd ed. Philadelphia: Saunders/Elsevier; 2008.
- Cagle PT. Pleural histology. In: Light RW, Lee YCG, editors. *Pleural disease: an international textbook*. London, England: Arnold Publishers; 2003. p. 249–55.
- Cibas ES. Peritoneal washings. In: Cibas ES, Ducatman BS, editors. *Cytology: diagnostic principles and clinical correlates*. Philadelphia: Saunders/Elsevier; 2009.
- DeMay RM. *The art and science of cytopathology, exfoliative cytology*, vol. 1. 2nd ed. Chicago: ASCP Press; 2012.
- Ellis CL, Burroughs F, Michael CW, Li QK. Cytology of metastatic renal medullary carcinoma in pleural effusion. A study of two cases. *Diagn Cytopathol.* 2009;37:843–8.
- Gupta S, Sodhani P, Jain S. Cytomorphological profile of neoplastic effusions: an audit of 10 years with emphasis on uncommonly encountered malignancies. *J Cancer Res Ther.* 2012;8:602–9.
- Henderson DW, Reid G, Kao SC, van Zandwijk N, Klebe S. Challenges and controversies in the diagnosis of mesothelioma: Part 1. Cytology-only diagnosis, biopsies, immunohistochemistry, discrimination between mesothelioma and reactive mesothelial hyperplasia, and biomarkers. *J Clin Pathol.* 2013;66(10):847–53.
- Jing X, Li QK, Bedrossian U, Michael CW. Morphologic and immunocytochemical performances of effusion cell blocks prepared using three different methods. *Am J Clin Pathol.* 2013;139:177–82.
- Khalbuss WE, Yang H, Lian Q, Elhosseiny A, Pantanowitz L, Monaco SE. The cytomorphologic spectrum of small-cell carcinoma and large-cell neuroendocrine carcinoma in body cavity effusions: a study of 68 cases. *Cytojournal.* 2011;8:18.
- Khalbuss WE, Monaco SE, Pantanowitz L. Chapter 9. Serous effusions. In: *The ASCP quick compendium (QC) of cytopathology*. Chicago: ASCP Press; 2013. p. 128–59.
- Li Q, Bavikatty N, Michael CW. The role of immunohistochemistry in the distinguishing squamous cell carcinoma from mesothelioma and adenocarcinoma in pleural effusion. *Semin Diagn Pathol.* 2006;23:15–9.
- Longatto-Filho A, Bisi H, Bortolan J, Granja NV, Lombardo V. Cytologic diagnosis of metastatic sarcoma in effusions. *Acta Cytol.* 2003;47:317–8.
- Nauen D, Li QK. Cytological diagnosis of metastatic glioblastoma in the pleural effusion of a lung transplant patient. *Diagn Cytopathol.* 2014;42(7):619–23.
- Stoll LM, Johnson MW, Gabrielson E, Askin F, Clark DP, Li QK. The utility of Napsin-A in the identification of primary and metastatic lung adenocarcinoma among cytologically “poorly differentiated carcinoma”. *Cancer Cytopathol.* 2010;118:441–9.
- Tong LC, Ko HM, Saieg MA, Boerner S, Geddie WR, da Cunha SG. Subclassification of lymphoproliferative disorders in serous effusions: a 10-year experience. *Cancer Cytopathol.* 2013;121:261–70.
- Wheeler YR, Burroughs F, Li QK. Fine needle aspiration of a well-differentiated papillary mesothelioma in the hernia sac: case report and review of literature. *Diagn Cytopathol.* 2009;37:748–54.
- Wojcik EM, Naylor B. “Collagen balls” in peritoneal washings. Prevalence, morphology, origin and significance. *Acta Cytol.* 1992;36(4):466–70.



<http://www.springer.com/978-1-4939-1476-0>

Diagnostic Cytopathology Board Review and  
Self-Assessment

Khalbuss, W.E.; Li, Q.K. (Eds.)

2015, XIII, 748 p. 484 illus. in color., Softcover

ISBN: 978-1-4939-1476-0